

# Cerebral Perfusion Using the Tissue Oxygenation Index in Mitral Valve Repair in a Patient with Porcelain Aorta and Aortic Regurgitation

Hirofumi Kasahara, MD, Hankei Shin, MD, and Mitsuharu Mori, MD

**We report successful mitral valve repair in a patient with porcelain aorta, complicated by aortic regurgitation, severe cerebrovascular disease, and multiple cerebral infarctions. The patient was a 77-year-old male who had congestive heart failure as a result of severe mitral regurgitation. Mitral valve repair was performed without aortic cross-clamping, using moderate hypothermic cardiopulmonary bypass. Aortic regurgitation was likely to worsen upon retracting the atrial septum to expose the mitral valve, complicating the operative procedure. We therefore controlled the regurgitation by lowering the blood temperature and using systemic perfusion flow. During systemic low-flow perfusion, we used near-infrared spectroscopy (NIRS) and the bispectral index to prevent cerebral hypoperfusion. The tissue oxygenation index value derived from NIRS was maintained above 55% during the procedure. The repair was performed safely with no difficulty. The postoperative course was satisfactory, with no neurological complications; echocardiography revealed no mitral regurgitation. The use of NIRS is valuable in preventing neurological complications in mitral valve operations complicated by porcelain aorta and aortic regurgitation. (Ann Thorac Cardiovasc Surg 2007; 13: 413–416)**

**Key words:** porcelain aorta, mitral valve repair, near-infrared spectroscopy, bispectral index

## Introduction

The porcelain aorta remains a challenging problem for cardiac surgeons. We successfully performed mitral valve repair on a patient with porcelain aorta complicated by aortic regurgitation (AR) without aortic clamping by using moderate hypothermic systemic low-flow perfusion controlled by near-infrared spectroscopy (NIRS) monitoring.

---

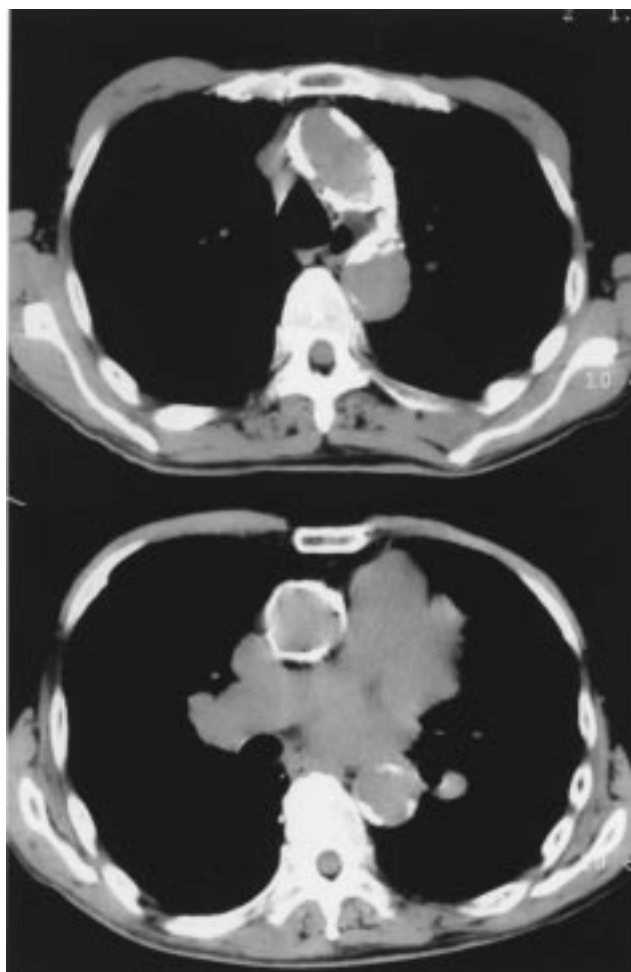
*From Department of Cardiovascular Surgery, Tokyo Dental College Ichikawa General Hospital, Ichikawa, Japan*

Received June 26, 2006; accepted for publication March 9, 2007  
Address reprint requests to Hirofumi Kasahara, MD: Department of Cardiovascular Surgery, Tokyo Dental College Ichikawa General Hospital, 5–11–13 Sugano, Ichikawa, Chiba 272–8513, Japan.

## Case Report

A 77-year-old man was referred to Ichikawa General hospital, Japan, complaining of dyspnea. He had had infective endocarditis 9 years earlier, resulting in mitral regurgitation (MR). He had received conservative therapy, but his heart failure worsened (New York Heart Association Class III). Echocardiography showed mild AR resulting from calcification and severe MR caused by prolapse of the medial portion of the posterior leaflet (P3) as a result of chordal rupture. Computer tomography (CT) revealed extensive calcification of the entire aorta (Fig. 1). Arterial angiography demonstrated diffuse arteriosclerotic changes with 50% stenosis in all supra-aortic vessels, 75% stenosis of the right iliac artery, and occlusion of the left iliac artery. Brain CT showed old multiple cerebral infarctions.

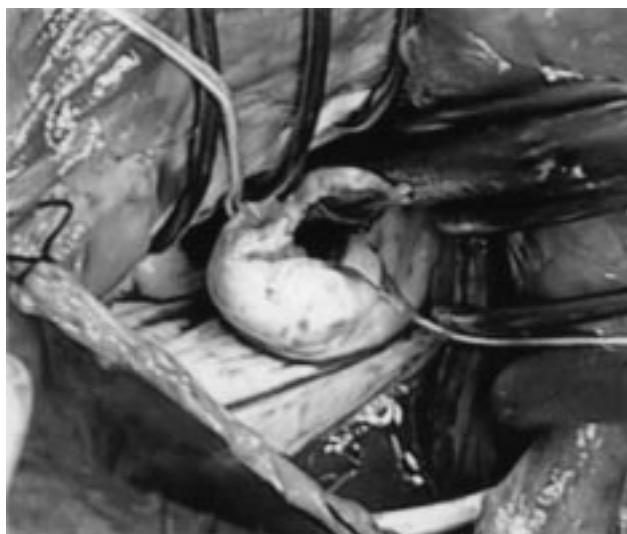We scheduled mitral valve repair, inducing ventricular fibrillation (VF) with no aortic cross-clamping. Prior to



**Fig. 1.** Computer tomography (CT) scan showing extensive calcification of the ascending aorta and aortic arch.

the induction of anesthesia, a dual sensor for NIRS (the NIRO-200, Hamamatsu Photonics, Hamamatsu, Japan) was attached to the patient's forehead to monitor the tissue oxygenation index (TOI) in the bilateral frontal lobe. Anesthesia was maintained by continuous intravenous propofol infusion and intermittent dosing with fentanyl. The bispectral index (BIS) was monitored with a BIS monitor (A-2000, Aspect Medical Systems, Inc., Newton, MA, USA) to maintain the depth of anesthesia. The BIS index was maintained from 40 to 60 throughout the operation.

After a median sternotomy, transesophageal echocardiography (TEE) and an epi-aortic manual search found a small area without calcification on the aortic arch; this spot was chosen as the cannulation site. After VF had been induced by systemic moderate hypothermia, the mitral valve was exposed using a transseptal approach. Mitral valve repair was performed by a quadrangular re-



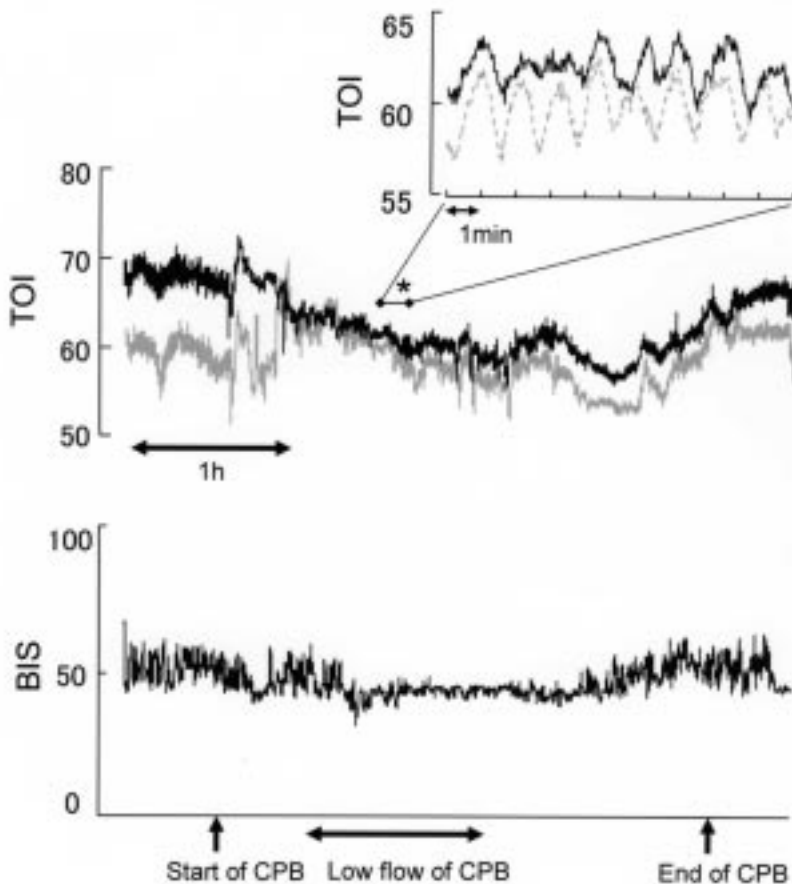
**Fig. 2.** Intraoperative view.

The mitral valve was exposed using the transseptal approach. A prolapse of the medial portion of the posterior leaflet is visible as a result of chordal rupture.

section of the P3 segment (Fig. 2). Mitral annuloplasty was also performed with a 32-mm Cosgrove-Edwards band (Edwards Lifesciences, Irvine, CA, USA). After the repair was complete, air evacuation was confirmed with TEE.

During the mitral procedure, the patient's AR was exacerbated by a retraction of the atrial septum to expose the mitral valve. The resulting increase in regurgitation considerably increased the volume of blood in the operative field, complicating the operative procedure and jeopardizing cerebral perfusion. Regurgitation was therefore controlled by reducing the blood temperature and the systemic pump flow. We manipulated the cardiopulmonary bypass (CPB) blood temperature and systemic perfusion flow so as to maintain the TOI derived from the NIRS at not less than 55% (Fig. 3). As a result, the lowest perfusion blood temperature was 23°C, and the lowest bladder temperature was 25.5°C. The minimum systemic pump flow during the procedure was 1.5 L/min/m<sup>2</sup>. At that time systemic blood pressure was around 40 mmHg. The CPB time was 183 min, and the VF time was 109 minutes. Myocardial damage was minimum, and the maximum postoperative creatine phosphokinase value was 425 IU/L.

A postoperative examination found that the mitral valve regurgitation had disappeared. The patient was discharged in good condition with no neurological complications.



**Fig. 3.** Time course of changes of TOI and BIS.

**Top:** Tissue oxygenation index (TOI). Channel 1 (left frontal forehead) corresponds to the black line, channel 2 (right frontal forehead) to the gray line. An asterisk shows that the value is expressed on a different scale.

The cardiopulmonary bypass (CPB) blood temperature and systemic perfusion flow were controlled so as to maintain the TOI at not less than 55%. The TOI value was very sensitive to the CPB flow. Immediately after the CPB flow reduced, the TOI value fell from 65% to 55%. Once it increased, the reduced TOI value recovered promptly.

**Bottom:** Bispectral index (BIS).

## Discussion

Many different methods have been reported for performing valve surgery without aortic clamping in patients having a severely calcified ascending aorta.<sup>1)</sup> These include deep hypothermic circulatory arrest (DHCA), endoaortic balloon clamp (EAC), and beating heart operations. DHCA is a method of brain protection, but it tends to require a long CPB time, and its safe arrest time is limited.<sup>1)</sup> EAC is a useful option, but the balloon may migrate and change the mitral valve geometry.<sup>2,3)</sup> EAC is also infeasible when there is peripheral arterial sclerosis, as in the present case. With the beating heart technique, the mitral valve operation in patients with AR becomes difficult because besides the beating condition, AR disturbs the operative field.<sup>4)</sup> We therefore performed the operation on a perfused fibrillated heart under relatively low perfusion with moderate hypothermia. We also chose the transseptal approach to access the mitral valve, allowing less retraction of the atrial septum than with the conventional lateral left atriotomy.<sup>5,6)</sup>

During the operation, AR was exacerbated by retracting the atrium septum so as to expose the mitral valve; this disturbs the procedure. We controlled the regurgitation by intermittently reducing systemic pump flow, as necessary. However, when the systemic perfusion is reduced, cerebral ischemia may develop as a result of hypoperfusion in cases with severe cerebrovascular disease, as in the present case. We believe that cerebral ischemic monitoring is necessary to avoid cerebral ischemia. We therefore used NIRS, which provided the cerebral TOI continuously and immediately.

The TOI derived from the NIRS is a reliable index for those cerebral perfusion parameters that must be maintained to prevent functional or structural neurological injury.<sup>7,8)</sup> Hagino and colleagues reported that a TOI value of less than 55% was a strong predictor of neurological injury.<sup>7)</sup> In the present case, when the atrial septum was retracted to expose the mitral apparatus, AR blood increased and the TOI value promptly fell. During the procedure, the TOI value was controlled to remain above 55%, with no sustained fall upon manipulating the perfu-

sion flow or blood temperature (Fig. 3). The patient recovered fully without neurological complications.

In nonaortic cross-clamping operations, mitral valve repair is quite complicated even when AR is not recognized, especially for the anterior leaflet. Intermittent systemic pump flow reduction with NIRS monitoring would then be a helpful option.

We have successfully performed mitral valve repair on a patient with porcelain aorta and AR without aortic clamping, using hypothermic systemic low flow perfusion and with the TOI monitored using the NIRS. This method is safe and should prevent neurological complications in similar patients.

## References

1. Girardi LN, Krieger KH, Mack CA, et al. No-clamp technique for valve repair or replacement in patients with a porcelain aorta. *Ann Thorac Surg* 2005; **80**: 1688–92.
2. Grossi EA, Galloway AC, LaPietra A, et al. Minimally invasive mitral valve surgery: a 6-year experience with 714 patients. *Ann Thorac Surg* 2002; **74**: 660–3; discussion 663–4.
3. Greelish JP, Soltesz EG, Byrne JG. Valve surgery in octogenarians with a “porcelain” aorta and aortic insufficiency. *J Card Surg* 2002; **17**: 285–8.
4. Prifti E, Bonacchi M, Giunti G, et al. Beating heart ischemic mitral valve repair and coronary revascularization in patients with impaired left ventricular function. *J Card Surg* 2003; **18**: 375–83.
5. Ogino H, Ueda Y, Morioka K, et al. Mitral valve repair in a patient with severe porcelain aorta. *Ann Thorac Surg* 1997; **64**: 1179–81.
6. Toyama M, Usui A, Murayama H, et al. Beating mitral valve replacement for a patient with porcelain aorta. *Jpn J Thorac Cardiovasc Surg* 2004; **52**: 488–90.
7. Hagino I, Anttila V, Zurakowski D, et al. Tissue oxygenation index is a useful monitor of histologic and neurologic outcome after cardiopulmonary bypass in piglets. *J Thorac Cardiovasc Surg* 2005; **130**: 384–92.
8. Orihashi K, Sueda T, Okada K, et al. Near-infrared spectroscopy for monitoring cerebral ischemia during selective cerebral perfusion. *Eur J Cardiothorac Surg* 2004; **26**: 907–11.