Case Report

Minimally Invasive Direct Coronary Artery Bypass Grafting for Third-Time Coronary Artery Revascularization

Shigeki Tabata, MD,[1] Go Watanabe, MD,[1] Kenji Iino, MD,[1] Kouichi Hagashidani, MD,[1]
Syohjiro Yamaguchi, MD,[1] Shigeyuki Tomita, MD,[1] Sadahiko Arai, MD,[1]
Takehisa Imagawa, MD,[2] and Hiroshi Saito, MD[2]

We performed a minimally invasive direct coronary artery bypass (MIDCAB) on two patients for third-time revascularization. The first patient was a 66-year-old woman who had patent bilateral internal thoracic artery (ITA) grafts and an occluded radial artery (RA) graft anastomosed to the posterolateral (PL) branch. She underwent her third revascularization for left circumflex coronary artery reconstruction with the MIDCAB technique using the right gastroepiploic artery. The second patient was a 65-year-old man who had occluded saphenous vein grafts (SVGs) on the anterior aspect of the heart, a stenotic left ITA graft to the left anterior descending artery, and a stenotic SVG to the PL branch. He underwent his third revascularization by MIDCAB using a bilateral RA-Y graft. Postoperative angiography of the two cases showed that the new grafts were widely patent. (Ann Thorac Cardiovasc Surg 2007; 13: 417–420)

Key words: minimally invasive direct coronary artery bypass grafting, third-time revascularization

Introduction

Reoperative coronary artery bypass grafting (second-time CABG) is performed when it is necessary to revascularize occluded bypass grafts or native coronary arteries with progressed arteriosclerosis, or both. However, it has been reported that second-time CABG procedures increased the rate of mortality and morbidity.[1)] The main problems that affect the surgical mortality and morbidity are due in part to the risks inherent in a second sternotomy and the detrimental effects of cardiopulmonary bypass (CPB).[2)] The choice of graft material in coronary reoperations also represents a major problem, especially in cases where the left internal thoracic artery (LITA) has been used previously.[3)] Refinements in surgical technique, cardiac anesthesia, myocardial protection, and postoperative care have resulted in an increasing number of patients undergoing a third CABG, and even a fourth.[3–5)] Performing minimally invasive direct coronary artery bypass (MIDCAB) without sternotomy, CPB, aortic cross clamping, or extensive dissection of the heart can prevent these problems in patients needing repeated surgical myocardial revascularization.[6,7)] In this report, we present two cases of MIDCAB for a third-time CABG.

From [1]Department of General and Cardiothoracic Surgery, Kanazawa University School of Medicine, Kanazawa, and [2]Department of Thoracic and Cardiovascular Surgery, Kouseiren Takaoka Hospital, Takaoka, Japan

Received October 19, 2006; accepted for publication January 22, 2007
Address reprint requests to Shigeki Tabata, MD: Department of Cardiac Surgery, Tokyo Medical University Hospital, 6–7–1 Nishishinjuku, Shinjuku-ku, Tokyo 160–0023, Japan.

Case Reports

Case 1

A 66-year-old woman underwent her first CABG with the bilateral internal thoracic arteries (ITAs) to the left anterior descending artery and the first diagonal branch in August 2001. One year later, she again presented with anginal pain. A coronary angiography (CAG) showed a

progression of arteriosclerosis in the left circumflex coronary artery (LCX). She required a second coronary artery revascularization. In August 2002, the operation was performed via a left thoracotomy using the left radial artery (RA), which was anastomosed to the descending aorta under partial clamping and the posterolateral (PL) branch without CPB, but postoperative CAG revealed an occlusion of the graft. Although the symptoms had mildly improved with coronary intervention and medical treatment, she was admitted to our hospital with severe chest pain. CAG revealed 95% stenosis of the LCX (Fig. 1). We decided to perform a third CABG for LCX reconstruction with the MIDCAB technique, using the right gastroepiploic artery (RGEA).

The patient underwent the third operation on April 1, 2003. An intra-aortic balloon pump (IABP) was used preoperatively. A midline epigastric incision approximately 10 cm caudal to the xiphoid was made to open the abdomen, and the RGEA was harvested. Simultaneously, the groin vessels were exposed for the cannulations. The diaphragm and pericardium were incised lengthwise to expose the diaphragm side of the left ventricular wall, and the posterodescending (PD) branch was carefully identified. After placing the stabilizer (Donut Heart Stabilizer™, Fukuda Denshi Co., Ltd., Tokyo, Japan), the RGEA-to-PD bypass grafting was successfully completed without CPB. While the PD branch was occluded for anastomosis, no marked change was found in the hemodynamic state or electrocardiographic monitoring.

Her postoperative course was uneventful. Postoperative CAG demonstrated a patent RGEA graft and satisfactory filling of the LCX system (Fig. 2).

Case 2

A 65-year-old man underwent his first CABG with the saphenous vein grafts (SVGs) to the left anterior descending artery (LAD), the first diagonal branch, and the LCX in September 1988. Ten years later he again presented with anginal pain. An angiogram showed the occlusion of two SVGs to the LAD and the diagonal branch. In November 1998, he underwent a second coronary artery revascularization with the MIDCAB procedure. The LITA was anastomosed to the LAD through a small anterolateral thoracotomy without CPB. Five years later, he was admitted to our hospital with severe chest pain. An angiogram showed an occlusion of the SVG to the LCX. Immediately thereafter, percutaneous transluminal coronary angioplasty was performed, but the SVG showed 90% stenosis (Fig. 3). Moreover, selective dye injection into the LITA graft revealed a stenotic legion at the distal anastomosis site. We decided to perform a third CABG, using the MIDCAB technique.

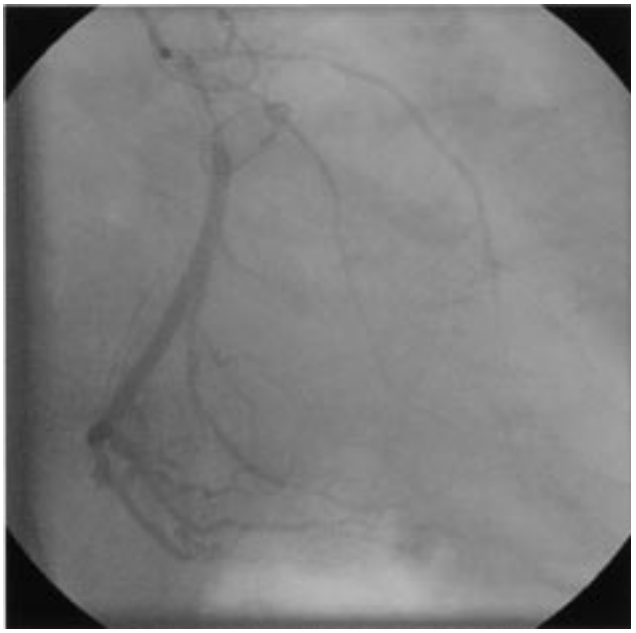

Fig. 1. Case 1: A preoperative coronary angiography demonstrated 95% stenosis of the left circumflex coronary artery.

The patient underwent the third operation on January 16, 2004. The anesthesiologist used selective intrabronchial intubation, and the patient was placed in a semilateral position. First, bilateral RAs were harvested in the usual fashion. The chest was entered through the left fifth intercostal space, and the left lung was collapsed. The LITA was dissected, and it was confirmed that it was patent. After a Y-shaped bilateral RA conduit was made, proximal anastomosis of the RA to the LITA was performed. After that, distal anastomoses to the LAD and LCX were performed. For distal anastomosis, the use of the Octopus-4 (Medtronic, Inc., Minneapolis, MN, USA) created a stable and dry operative field.

His postoperative course was uneventful. Postoperative CAG demonstrated a patent bilateral RA-Y graft (Fig. 4).

Discussion

Reoperative coronary artery bypass operations are performed when they are necessary to revascularize occluded bypass grafts or native coronary arteries with progressed arteriosclerosis, or both, and second CABGs are increasing in frequency. Coronary artery reoperations include the following problems: (1) difficulties with reentry, (2)

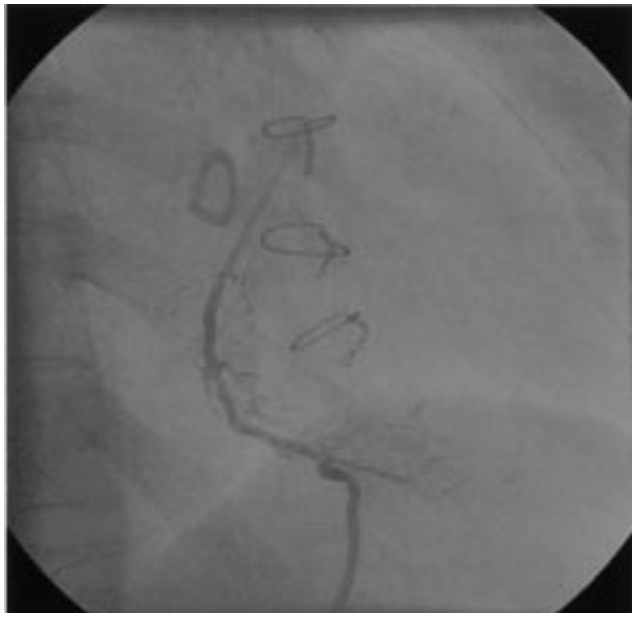

Fig. 2. Case 1: A postoperative coronary angiography demonstrated a patency of the right gastroepiploic artery to the posterodescending branch bypass grafting.

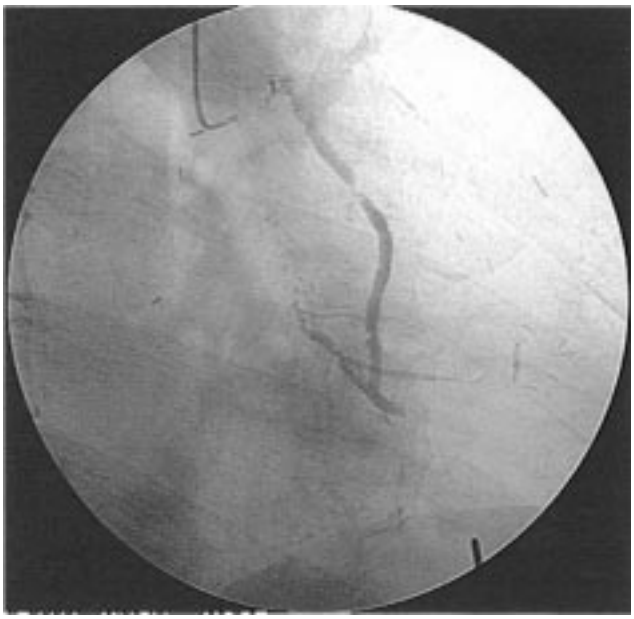

Fig. 3. Case 3: A preoperative coronary angiography demonstrated 90% stenosis of the saphenous vein graft.

potential for cardiac and conduit injury during dissection, (3) availability of a conduit, (4) management of patent vein graft, (5) myocardial protection, and (6) bleeding and blood use.[8] Thus second CABGs are associated with increased mortality and morbidity.[1]

Patients undergoing their third or fourth CABG procedure present unique challenges. Several authors have reported an operative mortality rate of third CABGs ranging from 6% to 12%.[3–5] As described above, the main problems that affect the surgical mortality and morbidity in repeat coronary bypass surgery are due in part to the risks inherent in the second sternotomy and the detrimental effects of CPB.[2] There is a risk of injury to the heart, such as the right ventricle and native coronary arteries, and to the old patent grafts, especially the functioning ITA graft, caused by the reopening of the sternum or by the dissection of the heart from adhesion. It has been reported that the incidence of reexploration for bleeding is higher in repeat reoperations than in primary operations or first reoperations.[4] Moreover, for the use of CPB the heart should be adequately exposed to mobilize the ascending aorta and right atrium for bypass cannulation and aortic cross clamping. Careful attention should be given when applying extracorporeal circulation and myocardial protection during repeated coronary revascularization. In patients who have patent ITA grafts, the need to free the ITA graft from adhesions and to occlude it during cardioplegic delivery adds further risk to the procedure.

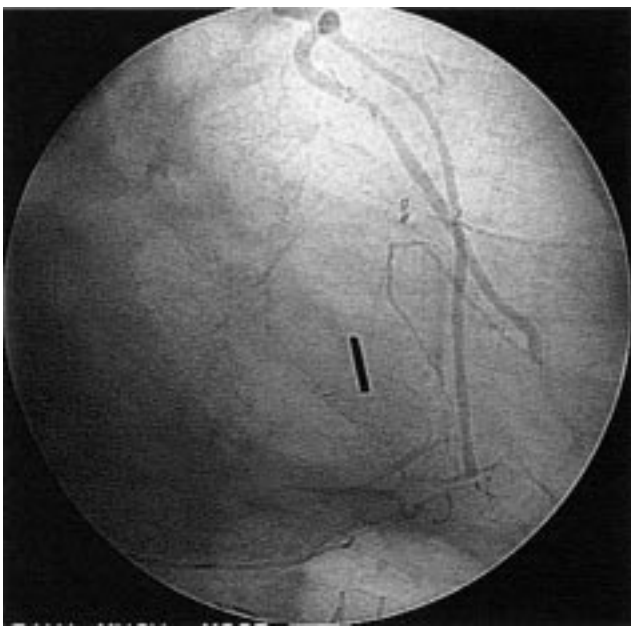

Fig. 4. Case 2: A postoperative coronary angiography demonstrated a patency of the radial artery Y graft.

MIDCAB has been suggested to be an effective alternative procedure for patients undergoing a second CABG.[6,7] The MIDCAB procedure avoids a second sternotomy, manipulation of patent grafts, and mobilization

of adhesions from previous surgery and does not require CPB or aortic cross clamping. As coronary artery anastomosis is performed on the beating heart in this procedure, stabilization of the heart becomes of great importance. Conveniently there are adhesions between the left ventricle and pericardium in almost all "re-do" patients, and these adhesions serve as a kind of stabilizer.[7)]

The choice of graft material in coronary reoperations also represents a major problem. Complete revascularization by the use of arterial grafts during a third CABG certainly represents the most logical approach to preventing another reoperation.[3)] It has been reported that arterial grafts in situ such as LITA, right ITA, or RGEA have been used in re-do MIDCAB procedures.[7)] In our first reported case, we performed the anastomosis of the RGEA to the PD branch via a small laparotomy. The application of this strategy is effective for avoiding both resternotomy and CPB, and it is particularly advantageous in patients who have patent ITA grafts.[6)] It has been reported that the left thoracotomy technique has been utilized in patients needing isolated LCX bypass grafting with a previously constructed functioning LITA graft.[3)] With this technique, the adhesion only in the area around the anastomosis sites is dissected to prevent the risk of dissecting the adhesion around the patent grafts. Also, the graft length can be easily adjusted because the route of the graft from the descending thoracic aorta to the LCX is almost straight up from the thoracic aorta to the LCX. Moreover, it has been suggested that these structural characteristics will decrease the risk of graft failure because of kinking or twisting. On the other hand, a possible problem of this procedure is a calcification of the descending aorta on which proximal anastomosis is done under partial aortic clamping. Moreover, long-term patency has not been reported. In our first reported case, the second coronary artery revascularization was performed via a left thoracotomy using the left RA, which was anastomosed to the descending aorta under partial clamping and the PL branch without CPB, but postoperative CAG revealed occlusion of the graft.

In our second reported case, we performed the anastomosis of the bilateral RA-Y graft to the LAD and LCX via a left thoracotomy approach. Fukuda et al. reported a case of a third CABG using a bilateral RA-T graft, which was anastomosed from the left subclavian artery to the LAD and first diagonal branch through a left thoracotomy approach.[9)] Uwabe et al. reported a case of a second CABG after MIDCAB with the reuse of LITA in situ, which was skeletonized and anastomosed 10 mm distal to the previous anastomosis site.[10)] The important point of our strategy is to limit the mobilization of adhesions from previous surgery to a minimum and to prevent the detrimental effects of CPB.

Conclusion

We performed MIDCAB procedures on two patients undergoing third-time CABGs. This approach is useful to avoid a second sternotomy and CPB in cases of repeat coronary artery reconstruction, especially with patent ITA grafts. Also, we believe that the operative approach should be individualized to the specific coronary status of the patient, and as much arterial graft material as possible should be utilized to secure adequate long-term results.

References

1. Grover FL, Johnson RR, Marshall G, et al. Factors predictive of operative mortality among coronary artery bypass subsets. *Ann Thorac Surg* 1993; **56**: 1296–306.
2. Moshkovitz Y, Lusky A, Mohr R. Coronary artery bypass without cardiopulmonary bypass: analysis of short-term and mid-term outcome in 220 patients. *J Thorac Cardiovasc Surg* 1995; **110**: 979–87.
3. Watanabe G, Haverich A, Speier R. Third-time coronary artery revascularization. *Thorac Cardiovasc Surg* 1993; **41**: 163–6.
4. Brenowitz JB, Johnson WD, Kayser KL, et al. Coronary artery bypass grafting for the third time or more. Results of 150 consecutive cases. *Circulation* 1988; **78**: I166–70.
5. Noyez L, Touma IM, Skotnicki SH, et al. Third-time coronary artery bypass grafting. *Ann Thorac Surg* 2000; **70**: 483–6.
6. Grandjean JG, Mariani MA, Ebels T. Coronary reoperation via small laparotomy using right gastroepiploic artery without CPB. *Ann Thorac Surg* 1996; **61**: 1853–5.
7. Miyaji K, Wolf RK, Flege JB Jr. Minimally invasive direct coronary artery bypass for redo patients. *Ann Thorac Surg* 1999; **67**: 1677–81.
8. Cosgrove DM 3rd. Is coronary reoperation without the pump an advantage? *Ann Thorac Surg* 1993; **55**: 329.
9. Fukuda I, Watanabe K, Seita J, et al. Bilateral radial arterial T graft and the left thoracotomy approach for second redo coronary artery bypass grafting. *Ann Thorac Cardiovasc Surg* 2000; **6**:196–8.
10. Uwabe K, Endo M, Kurihara H, et al. Re-use of left internal thoracic artery for redo operation after MIDCAB. *J Cardiovasc Surg (Torino)* 2000; **41**: 399–400.