Case Report

Coronary Artery Bypass Grafting in Cerebral Palsy with Severe Contractures of Extremities

Kazuhiro Kurisu, MD, Manabu Hisahara, MD, and Yusuke Ando, MD

We report on a 76-year-old man suffering from cerebral palsy who underwent coronary artery bypass grafting. Limitation of available bypass grafts and the approach of intra-aortic balloon pump insertion are of great concern because of his specific posture resulting from multiple articular contractures. We describe our planning to survive coronary surgery in this specific situation. (Ann Thorac Cardiovasc Surg 2007; 13: 421–422)

Key words: articular contracture, cerebral palsy, coronary artery bypass grafting, intra-aortic balloon pump

Introduction

Cerebral palsy is an abnormality of motor function that appears in an early age. It is a nonprogressive condition, but the involvement of extremities often develops articular contracture and abnormal posture.[1] Its association with coronary artery bypass grafting (CABG) presents two serious technical issues, choice of grafts and the approach of intra-aortic balloon pump (IABP) insertion. We report on an adult patient with cerebral palsy who underwent CABG and describe our perioperative planning.

Case Report

A 76-year-old man with refractory heart failure following anteroseptal myocardial infarction was transferred to our hospital. Electrocardiography showed poor R wave progression with an elevation of ST segment in leads V_{1-4} and T inversion in V_{2-6}. Echocardiography showed an impaired left ventricular function with severe hypokinetic wall motion in the anteroseptal and apical regions. Coronary angiography, approached through the right radial artery, demonstrated 75% stenosis of the left main trunk, 90% of the left anterior descending artery (LAD), 99% of the obtuse marginal branch (OM), and a total occlusion of the right coronary artery (RCA).

The patient suffered from cerebral palsy that had affected all four limbs. The hip joints were contracted in adduction and flexion, and the knees were fixed in flexion, presenting both knees pulled up on a supine position. The abduction of shoulder joints was tightly restricted, but the involvement of forearms and hands was mild; therefore he was able to take care of his matters using the upper limbs. This patient was classified as *diplegia*,[1] and his intelligence appeared to be borderline.

We scheduled an urgent CABG, in which the harvesting of grafts from other than extremities and the standby of retroperitoneal IABP insertion were planned. Bilateral internal thoracic arteries (ITAs) and the right gastroepiploic artery (RGEA) were harvested in skeletonized fashion. Simultaneously, an oblique abdominal incision about 10 cm in length was made above the right inguinal ligament (Fig. 1). The right iliac artery was easily exposed through the retroperitoneal approach.

Assisted circulation with ascending aortic perfusion and right atrial drainage was required because of hemodynamic instability soon after the manipulation of the heart. Triple bypass grafting to LAD, OM, and RCA was performed using a cardiac stabilizer. The intra-aortic counterpulsation through the right external iliac artery succeeded in weaning from the assist circulation (Fig. 1). Cardiac function was gradually improved, and

From Department of Cardiovascular Surgery, Kitakyushu Municipal Medical Center, Kitakyushu, Japan

Received September 12, 2006; accepted for publication February 7, 2007
Address reprint requests to Kazuhiro Kurisu, MD: Department of Cardiovascular Surgery, Kitakyushu Municipal Medical Center, 2–1–1 Bashaku, Kokurakita-ku, Kitakyushu, Fukuoka 802–0077, Japan.

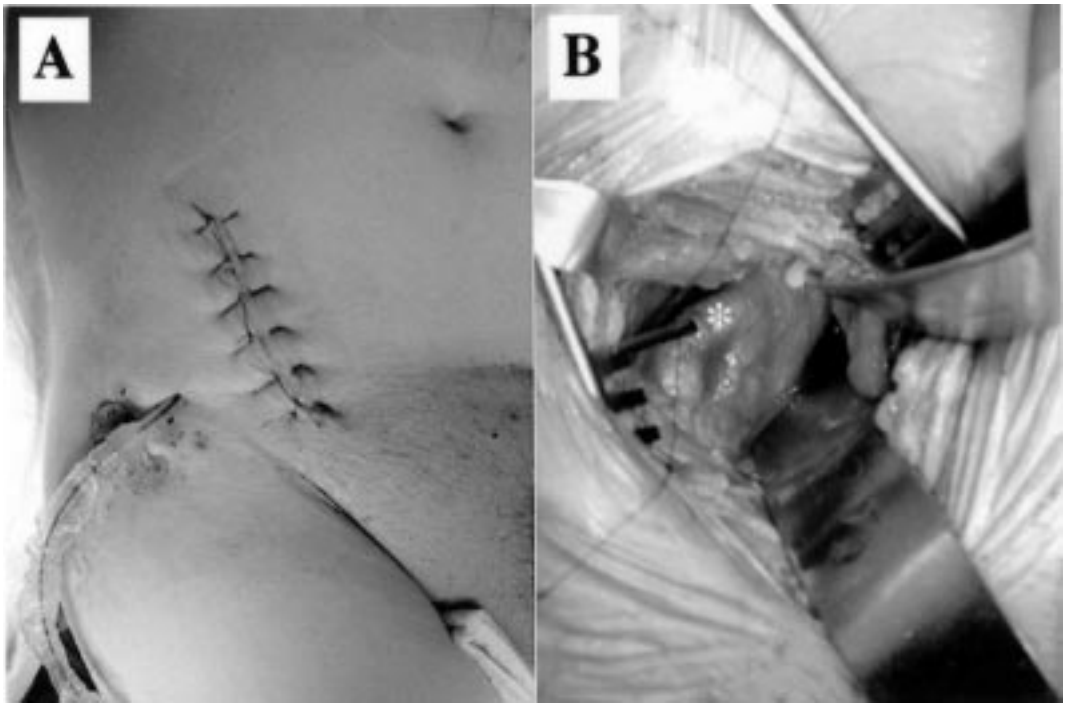

Fig. 1. Surgical images on intra-aortic balloon pump insertion.
A: Appearance of the right lower abdomen showed a skin incision and the shaft of a catheter.
B: A balloon pump catheter was directly inserted through the right external iliac artery (asterisk).

reexploration for the removal of IABP was carried out on postoperative day 4. Thereafter the cardiac function was well preserved, and the patient's recovery was uncomplicated.

Discussion

Someone with cerebral palsy is able to lead a nearly normal life if his/her neurological problems are properly managed, but this person may develop ischemic heart disease in adulthood. To our knowledge, this case is the first report of cardiac surgery in an adult with cerebral palsy.

Coronary surgery in this condition presents two technical issues related to severe contractures of the extremities. One is a limitation of available grafts. Both the radial artery and saphenous vein, harvested from extremities, were practically unsuitable. Bilateral ITAs and RGEA were good to harvest, but a "hybrid" revascularization might be required in case of grafts shortage. The other is the approach of IABP insertion. Several alternative approaches, including through ascending aorta, subclavian, axillary, or iliac artery, have been reported.[2–5] Of these, we proposed the retroperitoneal placement through the iliac artery[5] because of easy access and the avoidance of clutter in the chest. This approach appears to be really useful, especially in such a case with inadequate femoral arterial access.

In conclusion, we reported on a patient with cerebral palsy who survived CABG. Our planning appeared to be successful in managing this serious condition.

References

1. Huttenlocher PR. Cerebral palsy. In: Behrman RE, Vaughan VC III eds.; Nelson Textbook of Pediatrics. Philadelphia: WB Saunders, 1987; pp 1307–9.
2. Santini F, Mazzucco A. Transthoracic intraaortic counterpulsation: a simple method for balloon catheter positioning. *Ann Thorac Surg* 1997; **64**: 859–60.
3. Mayer JH. Subclavian artery approach for insertion of intra-aortic balloon. *J Thorac Cardiovasc Surg* 1978; **76**: 61–3.
4. H'Doubler PB Jr, H'Doubler WZ, Bien RC, et al. A novel technique for intraaortic balloon pump placement via the left axillary artery in patients awaiting cardiac transplantation. *Cardiovasc Surg* 2000; **8**: 463–5.
5. Buchanan SA, Langenburg SE, Mauney MC, et al. Ambulatory intraaortic balloon counterpulsation. *Ann Thorac Surg* 1994; **58**: 1547–9.