Original Article

Recommendation for Appropriate Use of GRF Glue in the Operation for Acute Aortic Dissection

Takashi Kunihara, MD, PhD, Norihiko Shiiya, MD, PhD, Kenji Matsuzaki, MD, Toshifumi Murashita, MD, PhD, and Yoshiro Matsui, MD, PhD

Background: Because an excessive use of activator (formaldehyde + glutaraldehyde) is supposed to be responsible for later adverse events after the use of gelatin resorcin formalin (GRF) glue in surgery for acute aortic dissection, we have tried to use a minimum dose of activator when the GRF glue was applied. We compare our midterm surgical results for acute aortic dissection with and without the use of GRF glue.
Methods: Forty-nine consecutive operated cases with Stanford type A acute aortic dissection within 48 h from onset from 1992 to 2005 were retrospectively analyzed. GRF glue was used in 21 cases (18 proximal and 14 distal anastomosis sites) since 1995 with outer felt reinforcement (GRF group).
Results: There was no operative deaths. In-hospital mortality was 4.8% in the GRF group and 7.1% in the control group (*P* = 0.7308). Intraoperative blood loss and transfusion requirements were similar between groups. The patency of the distal false lumen after the operation (57% vs. 55%, *P* = 0.8855), the 3-year survival estimate (82% ± 10% vs. 92% ± 6%, *P* = 0.4219), and the 3-year actuarial freedom from a reoperation of 92 anastomoses (97% ± 3% vs. 100%, *P* = 0.4986) were similar between the GRF group and the control group, respectively. A multivariate Cox's proportional hazard model identified no significant predictor for midterm death or reoperation.
Conclusions: The use of GRF glue for type A acute aortic dissection seems as clinically safe as other options with regard to midterm death or reoperation when applied appropriately with felt reinforcement. (Ann Thorac Cardiovasc Surg 2008; 14: 88–95)

Key words: GRF glue, acute aortic dissection, operation

Introduction

The advent of biological glues has greatly facilitated the approximation of fragile dissected aortic layers in the operation for acute aortic dissection. Since Guilmet and colleagues introduced the usefulness of gelatin resorcin formalin (GRF) glue (Cardial, Technopole, Sainte-Etienne, France: See appendix 1 for U.S. readers.) in surgery for acute aortic dissection in 1979,[1] it has been widely used except in the United States. However, the beneficial effect of GRF glue in aortic surgery is still controversial. Several authors have demonstrated that its use provides long-term stability of the dissected aorta without adverse sequelae.[2–7] On the other hand, a higher incidence of late reoperation or distal embolization in the subgroup with the use of GRF glue has been reported.[8–10] The key to resolve this conflict may be pathological findings from both groups. Hata and associates[4] showed that no infiltration of inflammatory cells was evident in the glued area, whereas Kirsch and co-workers[11] demonstrated a major destruction of the aortic root media, leading to vascular wall thinning and rupture. We suppose that this difference may come from a difference in the ratio of mixture of the two components: GR solution (gelatin + resorcinol) and F-activator (formaldehyde

From Department of Cardiovascular Surgery, Hokkaido University Hospital, Sapporo, Japan

Received December 22, 2006; accepted for publication June 4, 2007
Address reprint requests to Takashi Kunihara, MD, PhD: Department of Cardiovascular Surgery, Hokkaido University Hospital, N14W5, Kita-ku, Sapporo 060-8648, Japan.

+ glutaraldehyde). Manufacturer guidelines for GRF glue use recommend that F-activator should be used at 4%–6% GR solution. Several authors[8–10] have emphasized that an excess use of F-activator may be responsible for later adverse event after the use of GRF glue. Therefore we have tried to use a minimum dose of F-activator when GRF glue was applied in surgery for acute aortic dissection.

In the current study, we sought to demonstrate our early and midterm clinical results of surgery for acute aortic dissection with or without the use of GRF glue.

Material and Methods

Patients

Forty-nine consecutive patients with Stanford type A acute aortic dissection who were operated; on at Hokkaido University Hospital within 48 h from onset during August 1992 and August 2005 were recruited in this study (Table 1). The local ethics committee approved this investigation, including follow-up studies. Informed consent was obtained from all patients for the anonymous use of their data, including follow-up information. All operations were performed by a total of six surgeons. Among them, GRF glue was applied in 21 cases, since December 1995 (from the fifth patient in this series), to obliterate dissected aortic layers at either the proximal or distal anastomosis site (GRF group). In the GRF group, there were 11 males (52%), and the mean age was 64 ± 11 years. No patient with Marfan's syndrome was included in this subgroup. Fourteen patients underwent a replacement of the ascending aorta and the proximal arch (without reimplantation of the arch vessels), whereas 7 underwent total aortic arch replacement. The GRF group contained slightly older cohorts, but there were no significant differences with regard to preoperative characteristics compared with patients receiving no GRF glue at any suture line (control group).

Surgical techniques

Our routine operative methods for acute aortic dissection were based on those of the aortic arch replacement that was described previously in detail.[12] Briefly, after sufficient systemic cooling, the open distal aortic anastomosis was carried out first under circulatory arrest of the lower torso and antegrade selective cerebral perfusion, followed by systemic antegrade reperfusion through the side branch of the prosthesis. Proximal aortic anastomosis was then performed during systemic rewarming. When the total aortic arch should be replaced, the arch vessels were ultimately connected to the branches of the prosthesis.

Anastomosis techniques

GRF glue was used in 18 proximal and 14 distal anastomosis sites. GR solution was applied directly into the false lumen, and a minimum dose of F-activator was added using a 1-mL syringe with a 27 G needle. Compression of the two dissected aortic layers was carried out by special clamp[13] for a few minutes. Polytetrafluoroethylene (Teflon™, DuPont, Wilmington, DE) felt strips were liberally used for reinforcement at the outer suture line, except for three anastomosis sites (proximal, 1; distal, 2). Other techniques of reapproximation included felt reinforcement alone in 38 (proximal, 18; distal, 20) and creating neointima[14] in 15 (proximal 9, distal 6). Neointima was made with fibrinogen-soaked knitted polyester fabric (Bard Peripheral Vascular, Inc., Tempe, AZ), inserted within the false lumen, followed by dropping the thrombin solution of the fibrin glue (Beriplast P™, ZLB Behring, King of Prussia, PA, or Bolheal™, Astellas Pharma, Tokyo, Japan) around the fabric. Compression was made in the same manner as for the GRF glue. Seven elephant trunk techniques, 3 modified Bentall operations, and 3 direct sutures at the nondissecting aorta (proximal, 1; distal, 2) were also performed. All these anastomoses were reinforced with external felt strip, except for 3 proximal and 4 distal anastomosis sites.

Postoperative evaluation

Postoperative computed tomography was performed before discharge in all patients except 2. Among 94 anastomoses of 47 patients, 3 proximal anastomoses using the full root replacement technique and 3 performed on the nondissecting aorta (proximal, 1; distal, 2) were excluded. The patency of the false lumen of both proximal and distal anastomosis sites of a total of 88 anastomoses was then checked. Among them, GRF glue was used in 31 (17, proximal; 14, distal).

Late follow-up was 100%. The mean follow-up period was 42 ± 34 months (3–151 months): 49 ± 32 months (5–151 months) in the GRF group and 37 ± 36 months (3–121 months) in the control group ($P = 0.2523$).

Statistical analysis

All values are expressed as mean ± standard deviation. Statistical analysis was performed using StatView™ 5.0 (SAS Institute Inc., North Carolina, USA). A Student's *t* test was used for a comparison of the continuous variables, and the Chi-square test was used to compare frequencies between groups. Midterm survival and freedom from reoperation were compared between the groups us-

Table 1. Preoperative characteristics of two groups

	GRF (–) *n* = 28	GRF (+) *n* = 21	*P* value
Gender (male)	17 (61%)	11 (52%)	0.5597
Age (median)	58 ± 16 (62)	64 ± 11 (65)	0.1247
Marfan's syndrome	2 (7%)	0	0.2111
Preoperative shock	8 (29%)	4 (19%)	0.4430
Preoperative consciousness loss	7 (25%)	1 (5%)	0.0579
Aortic valve insufficiency>III°	3 (11%)	2 (10%)	0.8916
Total arch replacement	10 (36%)	7 (33%)	0.8624
Concomitant cardiac operation	6 (21%)	5 (24%)	0.8433
	Bentall 3	AVR 1	
	CABG 3	CABG 4	

GRF, gelatin resorcin formalin; Bentall, modified Bentall-type operation; AVR, aortic valve replacement; CABG, coronary artery bypass grafting.

ing the log-rank test. A *P* value of less than 0.05 was considered statistically significant. Factors listed in Appendix 2 were entered into the analysis of predictors for late death or reoperation. In a Cox's proportional hazard model to identify predictors for late death or reoperation, a *P* value of less than 0.05 in the univariate analysis was defined for selecting variables for entry into the multivariate analysis because of small sample size.

Results

Intra- and postoperative data

There was no significant difference between groups in intraoperative demographic data (Table 2). When only patients who underwent an isolated replacement of the ascending aorta and proximal arch were selected, they were also comparable.

There was no 30-day mortality, and all patients were discharged from our hospital. Three patients died in our associated hospitals afterward without returning to their homes; thus in-hospital mortality was 4.8% in the GRF group and 7.1% in the control group (*P* = 0.7308). No significant difference was found between groups with regard to postoperative morbidities (Table 3). Although reexploration for bleeding in the GRF group was twice the incidence of that in control, the suture line was responsible for rebleeding in only two patients (one from each group), which means that the main reason was coagulopathy and not GRF glue.

Patency of the false lumen

In all anastomoses, the patency rate of the false lumen was similar between anastomoses using GRF glue (32%) and those not using it (39%) (*P* = 0.5549). The patency rate of the false lumen in proximal anastomosis was also similar between two groups (GRF: 12%; control: 19%, *P* = 0.5167). In distal anastomosis, the patency rate of the false lumen was almost the same between the two groups (GRF: 57%; control: 55%, *P* = 0.8855). Patency of the false lumen was not identified to be an independent predictor for late death (*P* = 0.2838) or reoperation (*P* = 0.1724).

Midterm survival

Actuarial survival rate at 3 and 5 years after the operation was lower in the GRF group (82% ± 10%, 65% ± 13%, respectively) than in the control group (92% ± 6%, 83% ± 10%, respectively), but the difference may be due to chance (*P* = 0.4219) (Fig. 1: Each curve is truncated at 5 years because of the small number of patients at risk). There were 5 late deaths in the GRF group and 3 in the control group. All except one were transferred to our associated hospitals when they became stable with mean postoperative stay in our hospital of 104 ± 73 days (35–245 days). Their mean postoperative survival was 27 ± 19 months (3–55 months). The causes of deaths are summarized in Table 4. Sudden death was observed in only 1 patient in the control group eight months postoperatively and not observed in the GRF group. Four patients (two from each group) of 7 who developed postoperative stroke died during follow-up (Table 4). Cox's proportional haz-

Table 2. Demographic data

	All patients			Isolated ascending replacement		
	GRF (–) *n* = 28	GRF (+) *n* = 21	*P* value	GRF (–) *n* = 13	GRF (+) *n* = 10	*P* value
Operation (min)	546 ± 196	558 ± 257	0.8588	415 ± 82	445 ± 124	0.5093
CPB (min)	254 ± 106	243 ± 78	0.6804	189 ± 29	196 ± 36	0.5863
AXC (min)	132 ± 36	131 ± 35	0.9308	114 ± 16	119 ± 22	0.5191
SCP (min)	100 ± 67	98 ± 75	0.9453	57 ± 21	55 ± 34	0.8767
CA (min)	64 ± 23	63 ± 24	0.8444	55 ± 14	56 ± 17	0.8942
Min RT (°C)	19 ± 5	21 ± 2	0.2227	18 ± 6	21 ± 1	0.3752
Blood loss (L)	3.9 ± 2.6	3.6 ± 4.4	0.7368	2.4 ± 1.2	2.3 ± 1.1	0.8218
Transfusion (L)	4.3 ± 2.8	3.4 ± 2.9	0.2791	3.3 ± 1.6	2.8 ± 1.1	0.4195
Banked RBC (L)	1.8 ± 1.3	1.4 ± 1.3	0.1991	1.2 ± 0.6	1.0 ± 0.6	0.5134

GRF, gelatin resorcin formalin; CPB, cardiopulmonary bypass; AXC, aortic cross-clamping; SCP, selective cerebral perfusion; CA, circulatory arrest of the lower torso; Min RT, mimimum rectal temperature; RBC, transfused red blood cells.

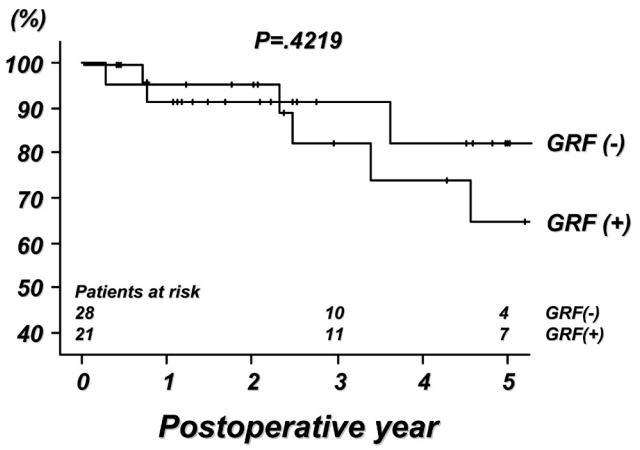

Fig. 1. Actuarial survival curve after emergent surgery for acute Stanford type A aortic dissection with (bold line) or without (thin line) use of gelatin resorcin formalin (GRF) glue.

Table 3. Postoperative morbidities

	GRF (–) *n* = 28	GRF (+) *n* = 21	*P* value
30-day mortality	0	0	N.A.
In-hospital mortality	2 (7%)	1 (5%)	0.7308
Reexploration for bleeding	2 (7%)	3 (14%)	0.4137
Postoperative hemofiltration	4 (14%)	1 (5%)	0.2758
Respiratory insufficiency (ventilation > 72 h)	8 (29%)	6 (29%)	N.A.
Neurologic morbidity	10 (36%)	6 (29%)	0.5977
Stroke	4 (14%)	3 (14%)	N.A.
Temporary neurologic dysfunction	6 (21%)	3 (14%)	0.5228
Drainage for late pericardial effusion	8 (29%)	3 (14%)	0.2356

GRF, gelatin resorcin formalin; N.A., not applicable.

ard model identified 6 significant predictors for late death in univariate analysis. However, none was significant in multivariate analysis (Table 5).

Late reoperation

Late reoperations were necessary in four patients (two from each group). From the control group, a 67-year-old female patient developed distal anastomotic pseudoaneurysm resulting from suture loosening 34 months after

Table 4. Cause of midterm death and postoperative survival month. Patients who developed postoperative stroke are marked with an asterisk (*).

Death	GRF (–) 3	GRF (+) 5
Related to postoperative morbidity	1 (9 m*)	2 (3 m*, 30 m)
Subarachnoid hemorrhage	0	2 (28 m, 41 m*)
Sudden death	1 (8 m*)	0
Renal failure	0	1 (55 m)
Lung carcinoma	1 (43 m)	0

GRF, gelatin resorcin formalin; m, month.

Table 5. Cox's proportional hazard model to identify predictor for midterm death

	Univariate *P* value	Multivariate *P* value	OR	95% CI
Duration of operation	0.0175	0.6030	1.002	0.995–1.008
Duration of selective cerebral perfusion	0.0099	0.1086	1.025	0.995–1.057
Postoperative max serum creatinine level	0.0178	0.2038	2.923	0.559–15.286
Postoperative hemofiltration	0.0022	0.8511	2.357	0.0003–18207
Reexploration for bleeding	0.0201	0.1302	25.455	0.384–1685
Postoperative neurologic morbidity	0.0366	0.1975	5.975	0.394–90.612

OR, odds ratio; CI, confidential interval.

the initial replacement of the ascending aorta and total aortic arch without the use of GRF glue. She underwent successful placement of the stented elephant trunk in the distal aortic arch through a resternotomy approach. In her initial operation, however, dissection had existed only in the ascending aorta and proximal aortic arch, and distal anastomosis had been performed on the distal neck of the nondissecting degenerative aortic arch aneurysm; therefore the distal anastomosis of this patient was excluded for analysis for reoperation.

Another patient, a 56-year-old male, underwent successful total aortic arch replacement because of its late expansion 48 months after initial replacement of the ascending aorta without the use of GRF glue.

From the GRF group, a 71-year-old male patient had undergone a replacement of the ascending aorta and proximal arch using GRF glue at both anastomoses and subsequent omental transposition resulting from methicillin-resistant *Staphylococcus aureus* mediastinitis 12 days after the initial operation. Ten months later, he developed a distal anastomotic pseudoaneurysm and underwent a successful re-replacement of the ascending aorta and proximal arch. Pathological findings in the glued area disclosed that the medial elastic lamellae were maintained, and no tissue necrosis, inflammatory change, or hemosiderin deposition was evident. The GRF glue was substituted by hyalinizing fibrotic scar (Fig. 2).

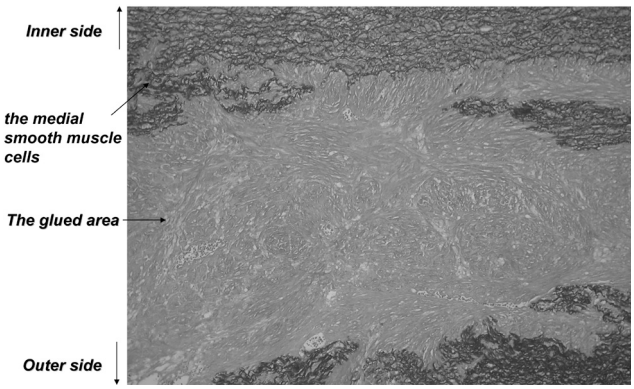

Fig. 2. Pathologic findings in the glued area of the distal native aorta from a 71-year-old male who developed distal anastomotic pseudoaneurysm. (Elastica van Gieson staining)

A 69-year-old female patient who developed progressive aortic valve insufficiency underwent aortic valve replacement 66 months after replacement of the ascending aorta and total aortic arch with the use of GRF glue. Because the internal surface of noncoronary sinus showed a yellowish color change, this sinus was also replaced with a Dacron graft. However, the cause of late aortic valve insufficiency seemed unclear. Pathological findings in the glued area were similar to the other case with a distal anastomotic pseudoaneurysm (Fig. 3). The postoperative

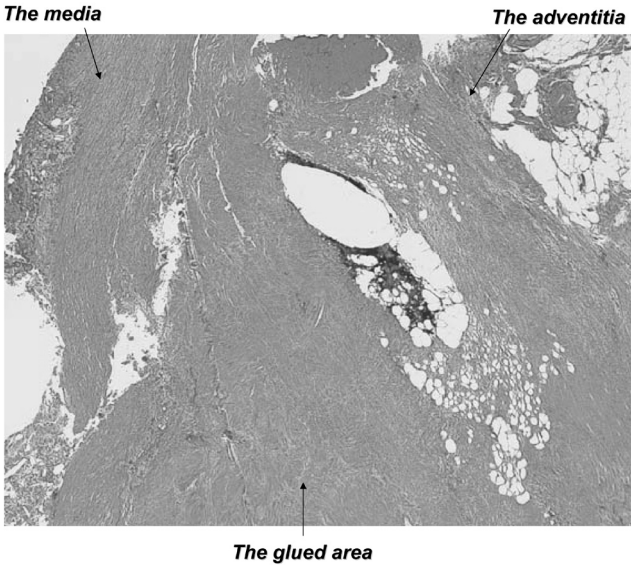

Fig. 3. Pathologic findings in the glued area of the noncoronary sinus from a 69-year-old female who developed late aortic valve insufficiency. (hematoxylin and eosin staining)

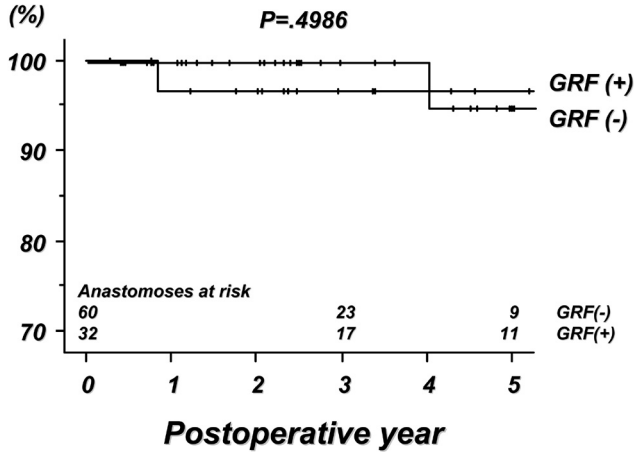

Fig. 4. Actuarial freedom from reoperation curve after emergent surgery for acute Stanford type A aortic dissection with (bold line) or without (thin line) use of gelatin resorcin formalin (GRF) glue.

courses of these four patients were uneventful.

Of 92 anastomoses, excluding 3 full root replacements and 3 anastomoses performed on the nondissecting aorta (proximal, 1; distal, 2), the actuarial freedom rate from reoperation at 3 and 5 years after the operation was quite equivalent between groups (97% ± 3% and 97% ± 3% in the GRF group and 100% and 95% ± 5% in the control group, respectively, $P = 0.4986$) (Fig. 4). Cox's proportional hazard model identified no significant predictor for late reoperation.

Comments

Our midterm clinical follow-up data suggested that the use of GRF glue for acute dissection was not associated with an increased risk of reoperation. Therefore the use of GRF glue in an operation for acute dissection seems as clinically safe as other options when applied appropriately with felt reinforcement.

There has been substantial evidence that GRF glue has had a positive impact on perioperative bleeding, mortality, and incidence of reoperation.[2–7] Kazui and colleagues[8] reported that the use of GRF glue decreased in-hospital mortality to 10.5%, from 23%. Bachet and co-workers[2,15] also commented that it fell to 21%, from 45%. The latest most favorable results reported from Hata and associates[4] achieved 6% in-hospital mortality. Surprisingly, we have experienced no 30-day mortalities regardless of the use of GRF glue. This may be because our hospital is a referral hospital; thus moribund patients might be less frequently sent to us.

On the other hand, late adverse events, such as pseudoaneurysm, redissection, or distal embolization, related to the use of GRF glue have also been reported.[8–10] Because the toxicity of formaldehyde was supposed to cause these events, the Food and Drug Administration has not approved its use in the United States. Instead, Bioglue, which uses no formaldehyde as an activator, has been widely used in many countries, including the U.S.[16] Nevertheless, late adverse events of this new glue have also been reported.[17,18] Furthermore, because it contains bovine albumin, Bioglue is not currently available in some countries, including Japan, for fear of bovine spongiform encephalopathy and the new variant of Creutzfeldt-Jakob disease.

The late fate of the false lumen is also matter of debate. Nguyen and associates[6] observed the higher rate of persistent false lumen perfusion of 68% following felt reinforcement alone compared with the lower rate of 55% following GRF glue treatment: the latter seems similar to our results (57% distal false lumen patency following GRF glue treatment). On the other hand, Hata and colleagues[4] reported excellent distal false lumen patency of 14%. The technical difference to obliterate a false channel between theirs and ours is the use or nonuse of inner felt reinforcement. We use only outer felt reinforcement to simplify the anastomosis. Nakajima and colleagues[19] failed to show a beneficial effect of the reduced dose of F-acti-

vator on the incidence of midterm redissection. They used only outer felt reinforcement in some of their patients.

Study limitations

First, the current clinical investigation has been performed as a retrospective nonrandomized analysis since 1992. GRF glue has been applied in 21 cases since 1995 as an alternative procedure, though the follow-up period was not significantly different between groups. It has been reported that late reoperation after the use of GRF glue occurred at 5.70 ± 4.47 years after the initial operation and occasionally at more than 10 years.[7] Therefore our patients should need further follow-up to draw a concrete finding. A prospective randomized control trial would provide definitive data with respect to the usefulness of GRF glue. Second, six surgeons have performed the operations, and there were some technical differences in detail between them. The tensile strength of the glue depends on the presence of moisture, the temperature, the ratio of two components, the duration of the reaction, and the degree of initial compression.[20] Nevertheless, the surgeon did not appear to be a predictor for late death or reoperation. Therefore we judged that the effects of the technical differences of various surgeons on our results might be minimum. Third, there was also technical variation to tailor false lumen in the control group. Although the usefulness of fibrin glue in an operation for acute dissection has been reported,[21] its tensile strength is obviously lower than that of GRF glue,[20,22] and an increased risk for reoperation following fibrin glue treatment has also been reported.[5] The greatest advantage of fibrin glue in an application for acute dissection may be that it can be absorbed rapidly and completely with minimal tissue reaction, whereas GRF glue exists for a long time.[22]

Conclusion

Early operative results and midterm follow-up data suggest that the use of GRF glue for acute dissection is as clinically safe as other options when applied appropriately. Since the primary goal of an operation for acute dissection may be the saving of patients from life-threatening rupture, the use of GRF glue seems justified and clinically safe. We hope that the current study will preserve the liberal use of GRF glue for acute dissection by a surgeon's choice. But we strongly recommend the use of additional felt reinforcement to avoid late reoperation, even when GRF glue is used.

Appendix 1

Any inquiries concerning GRF glue for U.S. readers should be sent to following office:

C.R. BARD INTERNATIONAL INC.
111 Spring Street, Murray Hill, New Jersey 07974, USA
Phone: +1 908-277-8439, Fax: +1 908-277-8236
Person in charge: Ms. Suzanne Skinner, Forecasting/Inventory Planner

Appendix 2

Variables evaluated for Cox's proportional hazard model to identify a predictor for late death or reoperation

Preoperative variables
- Age
- Gender
- Height
- Weight
- Body surface area
- Marfan's syndrome
- Shock
- History of aortic surgery
- Chronic obstructive pulmonary disease
- Consciousness loss
- Hypertension
- Diabetes mellitus
- Chronic renal failure
- Serum creatinine level
- Peripheral arterial disease
- Aortic valve insufficiency > II°

Intraoperative variables
- Operator
- Concomitant total aortic arch replacement
- Concomitant coronary artery bypass grafting
- Concomitant operation
- Isolated ascending aortic replacement
- Duration of circulatory arrest of the lower torso
- Duration of aortic cross clamping
- Duration of selective cerebral perfusion
- Duration of cardiopulmonary bypass
- Duration of operation
- Amount of blood loss
- Amount of transfusion
- Amount of banked red blood cell transfusion
- Use of GRF glue at any site
- Use of GRF glue at proximal anastomosis
- Use of GRF glue at distal anastomosis

Use of fibrin glue
Use of elephant trunk technique
Use of outer felt strip reinforcement
Minimum rectal temperature
Minimum bladder temperature
Postoperative variables
Respiratory insufficiency (mechanical ventilation > 72 h)
Duration of mechanical ventilation
Hemofiltration
Maximum serum creatinine level
Neurologic morbidity
Stroke
Temporary neurologic dysfunction
Reexploration for bleeding
Drainage for late pericardial effusion
Patency of the false lumen

Acknowledgment

We thank Fumihiro Sata, MD, PhD, for his help in statistical analysis.

References

1. Guilmet D, Bachet J, Goudot B, Laurian C, Gigou F, et al. Use of biological glue in acute aortic dissection. Preliminary clinical results with a new surgical technique. *J Thorac Cardiovasc Surg* 1979; **77**: 516–21.
2. Bachet J, Goudot B, Dreyfus G, Banfi C, Ayle NA, et al. The proper use of glue: a 20-year experience with the GRF glue in acute aortic dissection. *J Card Surg* 1997; **12**(2 Suppl): 243–55.
3. Niederhauser U, Kunzli A, Seifert B, Schmidli J, Lachat M, et al. Conservative treatment of the aortic root in acute type A dissection. *Eur J Cardiothorac Surg* 1999; **15**: 557–63.
4. Hata M, Shiono M, Sezai A, Iida M, Negishi N, et al. Type A acute aortic dissection: immediate and midterm results of emergency aortic replacement with the aid of gelatin resorcin formalin glue. *Ann Thorac Surg* 2004; **78**: 853–7.
5. Casselman FP, Tan ES, Vermeulen FE, Kelder JC, Morshuis WJ, et al. Durability of aortic valve preservation and root reconstruction in acute type A aortic dissection. *Ann Thorac Surg* 2000; **70**: 1227–33.
6. Nguyen B, Muller M, Kipfer B, Berdat P, Walpoth B, et al. Different techniques of distal aortic repair in acute type A dissection: impact on late aortic morphology and reoperation. *Eur J Cardiothorac Surg* 1999; **15**: 496–501.
7. Kirsch M, Soustelle C, Houel R, Hillion ML, Loisance D. Risk factor analysis for proximal and distal reoperations after surgery for acute type A aortic dissection. *J Thorac Cardiovasc Surg* 2002; **123**: 318–25.
8. Kazui T, Washiyama N, Bashar AH, Terada H, Suzuki K, et al. Role of biologic glue repair of proximal aortic dissection in the development of early and midterm redissection of the aortic root. *Ann Thorac Surg* 2001; **72**: 509–14.
9. Fukunaga S, Karck M, Harringer W, Cremer J, Rhein C, et al. The use of gelatin-resorcin-formalin glue in acute aortic dissection type A. *Eur J Cardiothorac Surg* 1999; **15**: 564–70.
10. von Oppell UO, Karani Z, Brooks A, Brink J. Dissected aortic sinuses repaired with gelatin-resorcin-formaldehyde (GRF) glue are not stable on follow up. *J Heart Valve Dis* 2002; **11**: 249–57.
11. Kirsch M, Ginat M, Lecerf L, Houel R, Loisance D. Aortic wall alterations after use of gelatin-resorcinol-formalin glue. *Ann Thorac Surg* 2002; **73**: 642–4.
12. Shiiya N, Kunihara T, Imamura M, Murashita T, Matsui Y, et al. Surgical management of atherosclerotic aortic arch aneurysm using selective cerebral perfusion: 7-year experience in 52 patients. *Eur J Cardiothorac Surg* 2000; **17**: 266–71.
13. Borst HG, Laas J, Buhner B. Efficient tissue gluing in aortic dissection. *Eur J Cardiothorac Surg* 1994; **8**: 160–1.
14. Nakajima T, Kawazoe K, Izumoto H, Kataoka T, Kazui T. Effective use of fibrin glue for acute aortic dissection. *Ann Thorac Surg* 2005; **79**: 1793–4.
15. Bachet J, Goudot B, Teodori G, Brodaty D, Dubois C, et al. Surgery of type A acute aortic dissection with Gelatine-Resorcine-Formol biological glue: a twelve-year experience. *J Cardiovasc Surg (Torino)* 1990; **31**: 263–73.
16. Chao HH, Torchiana DF. BioGlue: albumin/glutaraldehyde sealant in cardiac surgery. *J Card Surg* 2003; **18**: 500–3.
17. Furst W, Banerjee A. Release of glutaraldehyde from an albumin-glutaraldehyde tissue adhesive causes significant in vitro and in vivo toxicity. *Ann Thorac Surg* 2005; **79**: 1522–9.
18. LeMaire SA, Carter SA, Won T, Wang X, Conklin LD, et al. The threat of adhesive embolization: BioGlue leaks through needle holes in aortic tissue and prosthetic grafts. *Ann Thorac Surg* 2005; **80**: 106–11.
19. Nakajima T, Kawazoe K, Izumoto H, Kamada T, Kataoka T, et al. Influence of Gelatin-Resorcin-Formalin glue on mid-term redissection after aortic repair. *Surg Today* 2005; **35**: 112–6.
20. Albes JM, Krettek C, Hausen B, Rohde R, Haverich A, et al. Biophysical properties of the gelatin-resorcin-formaldehyde/glutaraldehyde adhesive. *Ann Thorac Surg* 1993; **56**: 910–5.
21. Seguin JR, Picard E, Frapier JM, Chaptal PA. Aortic valve repair with fibrin glue for type A acute aortic dissection. *Ann Thorac Surg* 1994; **58**: 304–7.
22. Basu S, Marini CP, Bauman FG, Shirazian D, Damiani P, et al. Comparative study of biological glues: cryoprecipitate glue, two-component fibrin sealant, and "French" glue. *Ann Thorac Surg* 1995; **60**: 1255–62.