Case Report

Giant Yolk Sac Tumor Operated under Percutaneous Cardiopulmonary Support (PCPS) and Aspiration Device

Shin-ichi Yamashita, MD[1,3], Masahide Nakagawa, MD[1], Kentaro Takaji, MD[2], Jun-ichi Kei, MD[2], and Katsunobu Kawahara, MD[3]

We here report the case of an 18-year-old man with a giant yolk sac tumor that is resected under percutaneous cardiopulmonary support (PCPS). Because this patient had severe dyspea when he lay in a supine position, we resected the tumor. We used PCPS during the operation for the induction and maintenance of ventilation because his trachea and left main bronchus were collapsed by the tumor. Also, we used a vacuum aspiration device that is commonly used for facilitating difficult vaginal deliveries. We propose that several devices, such as a PCPS and vacuum aspiration device, are useful for the operation of a mediastinal tumor with dyspnea. (Ann Thorac Cardiovasc Surg 2008; 14: 184–186)

Key words: yolk sac tumor, percutaneous cardiopulmonary support, aspiration device, operation

Introduction

A yolk sac tumor is a highly malignant cell neoplasm in the mediastinal tumor. It was first reported by Teilum in 1959, who suggested that the tumor had morphological features that reproduced the extraembryonic structures of the embryo. Clinically, patients have such symptoms as dyspnea, cough, chest pain, pleural effusions, and a large mass in the mediastinum.[1)] We here report the case of a giant mediastinal tumor resected by several devices, such as percutaneous cardiopulmonary support (PCPS).

Case

An 18-year-old male patient was admitted in a supine position with severe dyspnea. Although he had a cough and chest pain, he did not present SVC syndrome.

A couple of days before admission to our hospital, he visited another hospital and was diagnosed with a mediastinal tumor by a computed tomography (CT) scan (Fig. 1). The scan showed a giant mediastinal tumor and multiple nodule of bilateral lung. The left main bronchus and trachea were collapsed and stenotic by the weight of the tumor. However, he had an examination of a needle aspiration biopsy there, but it was not well diagnosed.

We decided on an emergency operation to resect the mediastinal tumor to relieve his complaint despite the suspicion of lung metastases. Because the patient could not lie in a supine position, we used several devices for the anesthesia and surgical operation.

First we devised the Ambu CardioPump, which is an innovative device that allows rescuers to apply alternating compression and aspiration to a patient's chest in an emergency situation; this is to pull up the chest wall to reduce the pressure of his tumor and to keep the space of the trachea. However, this device was not effective during the incision.

Second, we introduced a percutaneous cardiopulmonary support (PCPS) on the left side lateral position, and

From Departments of [1]Surgery and [2]Cardiovascular Surgery, National Hospital Organization, Kumamoto Medical Center, Kumamoto; [3]Department of Surgery II, Oita University Faculty of Medicine, Oita, Japan

Received December 13, 2006; accepted for publication May 28, 2007
Address reprint requests to Shin-ichi Yamashita, MD.: Department of Surgery II, Oita University Faculty of Medicine, 1–1 Idaigaoka, Hasamamachi, Yufu 879–5593, Japan.

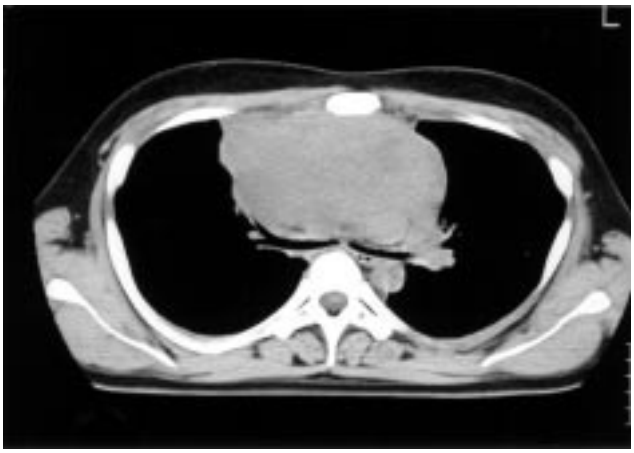

Fig. 1. A computed tomography (CT) scan revealed a mediastinal tumor and stenosis of the trachea and main bronchus.

Fig. 2. The vacuum aspiration device to pull up the tumor directly after median sternotomy to reduce the respiratory pressure and the total flow of percutaneous cardiopulmonary support (PCPS).

the patient was intubated for general anesthesia in the same position. During the general anesthesia during the supine position, the ventilation was difficult because of less ventilation volume and high respiratory pressure. The patient's ventilation and circulation were assisted by PCPS until the end of the tumor's resection.

Third, we used a vacuum aspiration device, which is normally used for facilitating difficult vaginal deliveries (Fig. 2), to pull up the tumor directly after median sternotomy in order to reduce the total flow of PCPS (to 2.0 L/min, from 3.5). After complete resection of the tumor, PCPS was left off, and bilateral multiple lung nodules were resected by means of reduction surgery.

The postoperative course was well passed even though the patient had an infection of his right inguinal part. However, the residual tumor enlarged and metastasized with too much faster progression. The patient died of the tumor 33 days after the operation. A pathological examination revealed the finding consistent with a yolk sac tumor.

Discussion

Yolk sac tumors of the mediastinum are highly malignant neoplasms that are usually unresectable at the initial diagnosis and frequently metastasize to the lungs, brain, liver, and bones.[1] Although patients are usually treated with chemotherapy, such as CDDP, they have poor results.[1,2]

In this report, we introduce the usefulness of several devices for respiratory support during the resection of the mediastinal tumor. PCPS is applied for cardiopulmonary resuscitation or severe cardiac dysfunction.[3] It is sometimes used in thoracic surgery, such as sleeve pneumonectomy, to assist ventilation.[3–5]

Although the patient was not sufficiently ventilated until the end of the tumor's resection, his oxygenation was well maintained with a flow 2.0–3.5 L/min of PCPS.The complication of the PCPS system may be embolism, thrombosis, bleeding, and immunodeficiency. In this case, we could find no increase of bleeding; however, the patient had an infection at his femoral site. Ultimately, these immunodeficiency states caused a rapid regrowth of the tumor. We could complete the operation safely, but should consider the negatives of this system.

Not only the PCPS system, but also the vacuum aspiration device is useful to reduce the pressure, and this device is normally used for aspiration vaginal deliveries. This device is useful for a decrease of the respiratory pressure during the mechanical ventilation and could accomplish the reduction of total PCPS flow. Several combinations of these devices lead the operation successful.

The therapy of malignant mediastinal tumor is still controversial. We decided on the operation for the reduction of symptom, i.e., severe dyspnea; however, another therapy, such as chemotherapy, might be applied with mechanical ventilation until the tumor reduction.

In conclusion, we here reported the case of a safe operation for giant mediastinal tumor by using PCPS and an aspiration device. This system is useful for the rescue of ventilation insufficiency caused by a giant mediastinal tumor.

References

1. Moran CA, Suster S. Primary germ cell tumors of the mediastinum: I. Analysis of 322 cases with special emphasis on teratomatous lesions and a proposal for histopathologic classification and clinical staging. *Cancer* 1997; **80**: 681–90.
2. Mönig SP, Schmidt R, Krug B. Yolk sac tumor of the anterior mediastinum: the role of palliative surgery. *Am Surg* 1997; **63**: 948–50.
3. Kodama K, Higashiyama M, Yokouchi H, Takami K, Yasuda T, et al. Use of percutaneous cardiopulmonary support (PCPS) for extended surgery in patients with T4 tumor. *Kyobu Geka* 2000; **53**: 721–8 (in Jpse with Engl abst).
4. Asato Y, Amemiya R, Kiyoshima M, Shioyama Y, Asato M. Pulmonary artery stenting for recurrent lung cancer after left pneumonectomy. *Ann Thorac Surg* 2002; **73**: 1962–4.
5. Ishikawa N, Sato H, Hiranuma C, Takizawa M. A surgical intervention using percutaneous cardiopulmonary support for contralateral pneumothorax following pneumonectomy. *Ann Thorac Cardiovasc Surg* 2001; **7**: 235–6.