Case Report

Off-Pump Coronary Artery Bypass Surgery in Dextrocardia: A Report of Two Cases

Murali Chakravarthy, MD, DA, DNB, Vivek Jawali, MS, MCh, and Devananda Nijagal, MS, MCh

Dextrocardia is a rare condition that may be congenital (situs inversus) or aquired (pseudodextrocardia). Since individuals with this ailment have normal cardiac physiology and function, they may live normal lives. Similar to the general population, however, they might be susceptible to ischemic heart disease and present to a cardiothoracic surgical department for coronary artery bypass surgery. We report two cases: one of dextrocardia (situs inversus) and another resulting from an elevation of the left hemidiaphragm, causing pseudodextrocardia. To operate on patients with dextrocardia, surgeons may need to make a few modifications. These include using the right internal mammary artery as a conduit for the "left" anterior descending artery, lengthening the left internal mammary artery to reach the left anterior descending artery, and sometimes the operating surgeon may need to stand at the left side of the operating table. The careful planning of work on the conduits in the preoperative period requires prudence. This report highlights the surgical difficulties during operations on patients with situs inversus or pseudodextrocardia. (Ann Thorac Cardiovasc Surg 2008; 14: 187–191)

Key words: dextrocardia, off pump coronary artery bypass surgery, internal mammary artery, diaphragm, eventration

Introduction

Dextrocardia associated with situs inversus totalis is known to occur with an incidence of 1:10,000,[1)] and the individuals with this condition survive long enough to suffer from ischemic heart disease requiring interventions.[1,2)] Therefore in our clinical practice, we do come across some cases of atherosclerotic heart disease in these patients requiring coronary artery bypass grafting surgery (CABG). At times, eventration of the left hemidiaphragm may displace the heart to the right and present as "pseudodextrocardia." Certain modifications in the surgical techniques are required in these patients for a successful outcome while performing CABG. The aim of this report is to highlight the surgical difficulties while operating on patients with situs inversus or pseudodextrocardia.

From Wockhardt HeartIinstitute, Bangalore, Karnataka, India

Received February 27, 2007; accepted for publication July 4, 2007
Address reprint requests to Murali Chakravarthy, MD, DA, DNB: Wockhardt Heart Institute, Bangalore, Karnataka–560076, India.

Case Reports

Case 1

A 41-year-old gentleman, weighing 84 kg (185 lb) and 180 cm (5 ft 10 in) tall, with exercise angina was diagnosed to have ischemic heart disease; coronary angiogram revealed triple vessel coronary artery disease and was referred to our center for CABG.. He was a smoker, 10 cigarettes daily for the past 15 years. During routine preoperative chest X-ray we detected a shift of mediastinal structures to the right because of eventration of diaphragm (Fig. 1). A computerized tomography showed eventration of the left hemidiaphragm up to T5 vertebral level (Fig. 2). Pulmonary function test results were normal. A fluoroscopy showed no paradoxical movement of

Fig. 1. Chest X-ray of case 1.

Fig. 2. Computerized scan of chest in case 1.

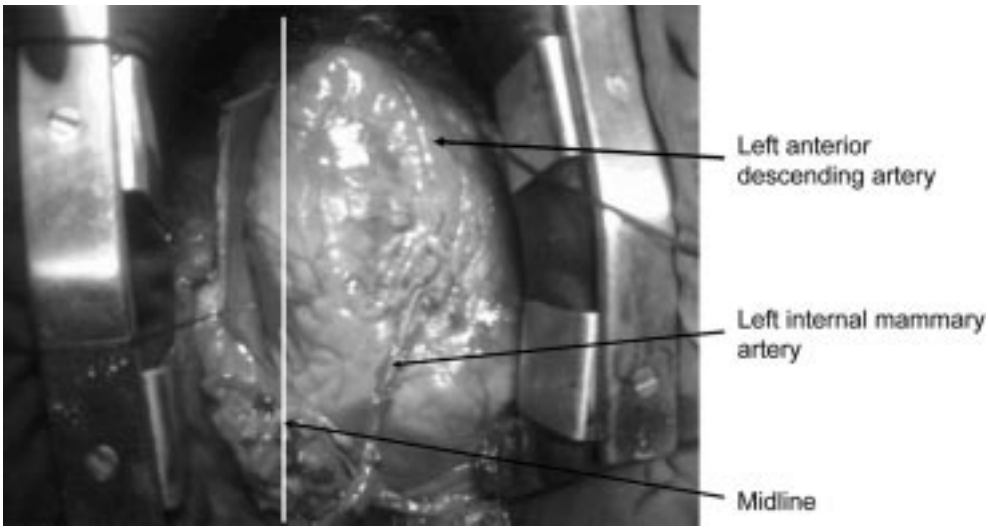

Fig. 3. Showing a shift of heart to the right.

the left hemidiaphragm or abnormal disposition of the abdominal organs, such as liver and stomach. We offered to perform off-pump coronary artery bypass (OPCAB) surgery, which is the technique of first choice at our center. We did not plan to plicate the left hemidiaphragm, since the patient had normal pulmonary function tests and diaphragmatic movements and was asymptomatic. On the day of surgery, before it commenced, invasive monitoring lines were inserted under local anesthesia. Surgery commenced via midsternotomy under general anesthesia. The left internal mammary artery (LIMA) was harvested by extrapleural technique (without opening the pleura). The patient was heparinized by administering 3 mg/kg heparin intravenously; this resulted in an adequate activated clotting time of 300 s.

On opening the pericardium, we noticed that the heart was "pushed" to the right side of the chest. Unusually, the authors found the heart rotated anticlockwise, the left pulmonary artery obscuring the aorta, and the "left" anterior descending artery in the midline (Fig. 3). The surgery was performed with the operating surgeon standing on the right side of the patient. The sternal retractor had to be selectively opened more to the right in order to visualize the entire heart. Proximal anastomoses (saphenous vein and free radial artery upon saphenous vein hood) were done first. The aorta had to be brought into vision by retracting the left main pulmonary artery to the left and rotating the aorta clockwise. The length of the saphenous vein required for the posterior descending artery was longer than usual. Care was taken to position the graft

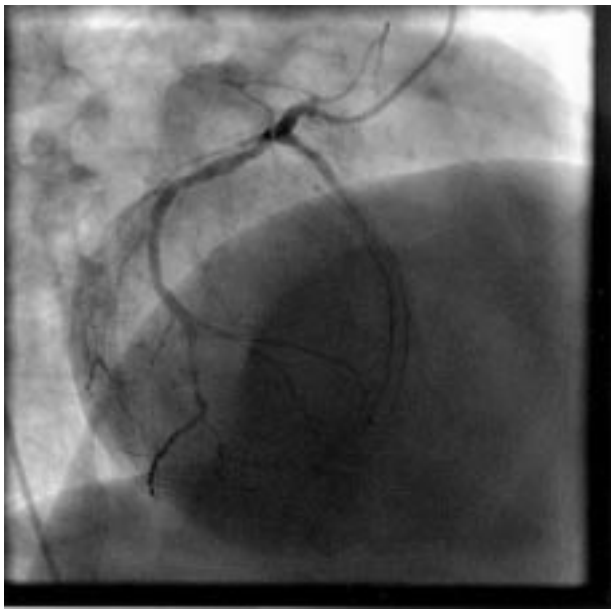

Fig. 4. Showing a "mirror image" angiogram of left coronary artery.

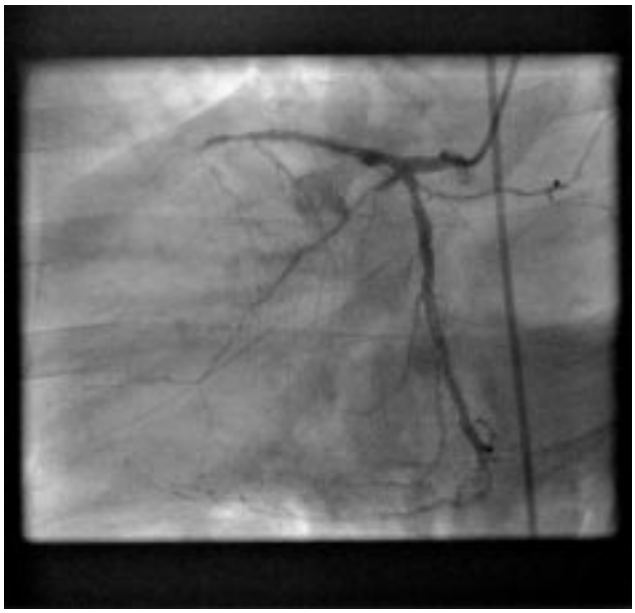

Fig. 5. Right anterior oblique view of the left coronary artery.

correctly, considering the current native position of the aorta.

The left anterior descending (LAD) artery required a distal graft, and even the "full length" of LIMA did not reach the LAD because of the shift of the heart to the right and its anticlockwise rotation. After further proximal dissection and skeletonizing the LIMA, we could mobilize the distal end to LAD without traction of the conduit. OPCAB surgery was performed using Octopus\@3 (Medtronic Inc., Minneapolis, MN 55432-5604, USA) for tissue stabilization. The obtuse marginal artery was more anterior than usual, and we had no difficulty in grafting or maintaining hemodynamic stability; it was grafted with free radial artery conduit. The grafting of the posterior descending artery caused hypotension (because the heart had to be de-rotated and the starfish [Medtronic Inc.] was used to visualize the posterior descending artery well) that was corrected by administering an intravenous infusion of dopamine 5 mcg/kg/min, bolus of 150 mL of sodium chloride solution, and turning the table to an anti-Trendelenberg position. After completion of the grafting, residual heparinization was reversed by the intravenous administration of 200 mg of protamine. The surgery lasted 215 min, and the intraoperative blood loss by the gravimetric method was 450 mL. The patient was transferred to the intensive care unit, mechanically ventilated for 2 h, and then extubated. He received no blood transfusion. Postoperative analgesia was provided by administering an infusion of a mixture containing 0.16% bupivacaine and 5 mg of fentanyl/mL at the rate of 3 mL/h. Physiotherapy was commenced on the day of surgery, and the patient could be mobilized on postoperative day 2.The patient had no problems and was discharged on the fifth postoperative day.

Case 2

An 81-year-old gentleman weighing 56 kg (123 lb) was admitted to the hospital with complaints of ongoing chest pain associated with breathlessness. Physical examination was normal, but for an emphysematous chest. Chest X-ray showed dextrocardia, and abdominal ultrasound examination confirmed the presence of situs inversus totalis. He was receiving an infusion of nitroglycerin, heparin, and insulin. His coronary angiogram revealed triple vessel disease and dextrocardia. The anterior descending artery had 80% proximal lesion, 90% lesion in the obtuse marginal artery, and 80% lesion in the "right coronary" artery (Figs. 4, 5, and 6).

Because of his unstable angina, he was taken up for emergency coronary revascularization. Under general anesthesia, the chest was opened through midsternotomy. The right internal mammary artery and saphenous vein of adequate length were harvested. Proximal anastomoses on the ascending aorta were performed first using reversed saphenous vein with the operating surgeon standing on the right side of the patient, and the distal anastomoses

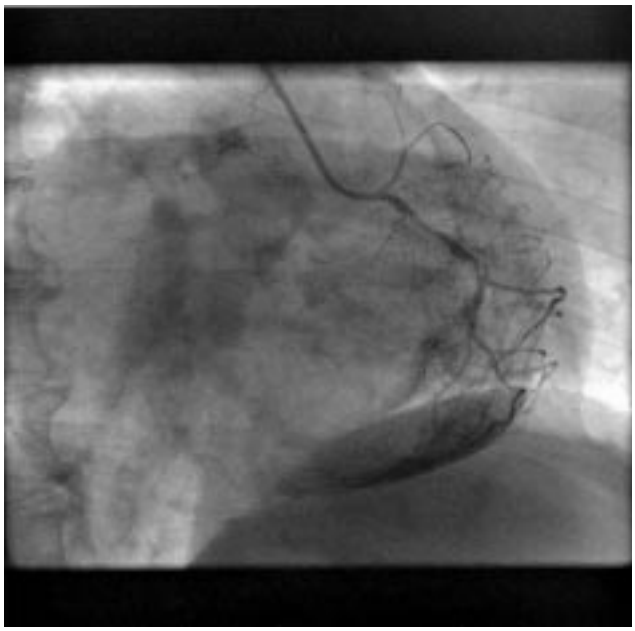

Fig. 6. Coronary an angiogram of the right coronary artery.

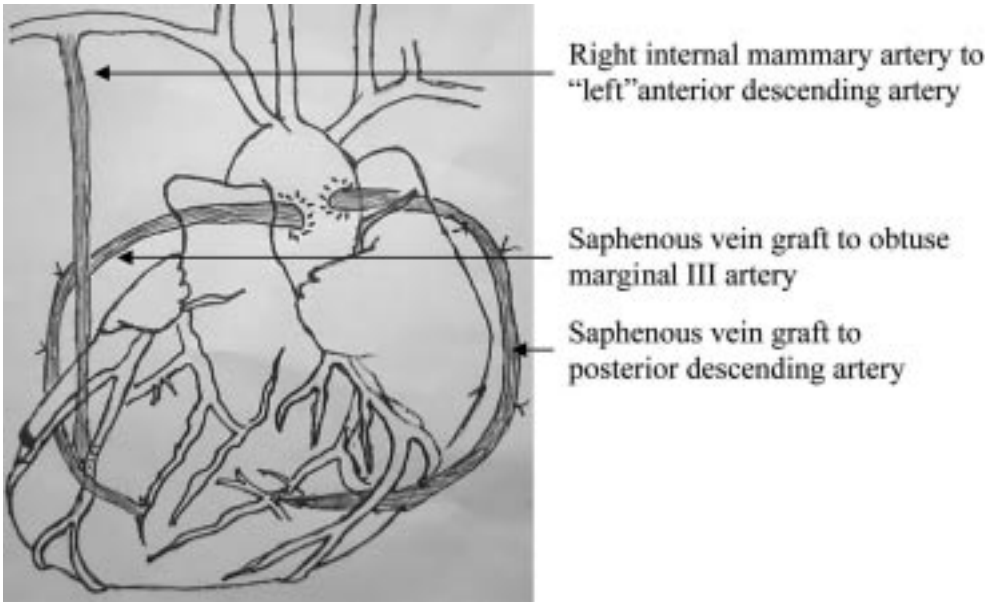

Fig. 7. Showing grafts in the dextrocardia position.

were performed with the surgeon on the left side of the patient. An in situ right internal mammary artery was anastomosed to the anterior descending artery by the off-pump technique, using Octopus\@3 for tissue stabilization. Saphenous vein grafts were sewn on to the diagonal, obtuse marginal, and "right coronary artery" using the same technique (Fig. 7). The duration of surgery was 190 min; blood transfusion was not required in the postoperative period. There were no complications in the postoperative period, and the patient was discharged on the 5th postoperative day.

Discussion

Performing a coronary artery bypass surgery may be technically more demanding on patients who have dextrocar-

dia or displacement of the heart by intrathoracic structures, as mentioned in our report. These two reports suggest that successful surgery is possible if adequate modifications are made during surgery. There are a few reports of myocardial revascularization in dextrocardiac patients with the internal mammary artery to the anterior descending artery and vein grafts to the other vessels.[1,3,4] These authors suggest that in spite of the altered coronary anatomy, it is recommended that the right internal mammary artery be the first choice of graft for the anterior descending artery for a "*situs inversus*" situation.[4] But in case 1, since there was no *situs inversus*, we decided to use the LIMA to graft LAD. Even the full length of LIMA proved short because of the rotation and displacement of the heart. We presume that under such circumstances, it may be worthwhile opening the pericardium and measuring the approximate lengths before harvesting and disconnecting the conduits. We also suggest that conduits of adequate lengths be chosen, and performing proximal anastomosis first gives us the freedom to choose an appropriate length of the conduit before performing the distal anastomosis.

We performed the surgery by the off-pump technique using the right internal mammary artery to the anterior descending artery, and there is one more report of performing the coronary artery bypass grafting by the off-pump technique in a patient with dextrocardia[3] using both mammary arteries. Surgery poses extra problems, even if the surgeon stands on the left side of the operating table; technically it is more difficult for a right-handed surgeon. In our experience with these cases, our operating time was slightly more prolonged than usual; however, performing surgery on the pump may pose more technical problems with caval cannulation, retrograde cardioplegia cannulation, and other cannulations of the breast and the vascular structures that may be required during the course of surgery. Myocardial revascularization has been reported in dextroversion[5] and will probably be technically more challenging because the relationships between the cardiac chambers and the other structures (that is, superior and inferior vena cavae, liver, and stomach) are modified. A look at the cardiac anatomy in our second case suggested that if a cardiopulmonary bypass was required, aortic and caval cannulations would be formidable tasks.

Cases such as our second one, if associated with compromised pulmonary function, should get good postoperative pain relief so that effective physiotherapy can be administered. Any mode of pain therapy, such as continuous epidural infusion, patient controlled analgesia by an intravenous infusion of drugs will help. In patients with eventration or intrathoracic problem on the left side with compromised pulmonary function, preserving the pleural integrity and effective physiotherapy may contribute to their quick recovery.

References

1. Abensur H, Ramires JA, Dallan LA, Jatene A. Right mammary-coronary anastomosis in a patient with situs inversus. *Chest* 1988; **94**: 886–7.
2. Hynes KM, Gau GT, Titus JL. Coronary heart disease in situs inversus totalis. *Am J Cardiol* 1973; **31**: 666–9.
3. Tabry IF, Calabrese J, Zammar H, Abou-Kasem K, Akeilan H, et al. Case report: off-pump total myocardial revascularization for dextrocardia and situs inversus. *Heart Surg Forum* 2001; **4**: 251–3.
4. Erdil N, Cetin L, Sener E, Demirkiliç U, Sa? C. Situs inversus and coronary artery disease. *Asian Cardiovasc Thorac Ann* 2002; **10**: 53–4.
5. Totaro P, Coletti G, Lettieri C, Pepi P, Minzioni G. Coronary artery bypass grafts in a patient with isolated cardiac dextroversion. *Ital Heart J* 2001; **2**: 394–6.