Case Report

Repair of Ventricular Septal Perforation with Asymmetrical Conical Patch Exclusion

Hiroki Sato, MD, PhD, Nobuaki Suzuki, MD, Toshio Baba, MD, PhD, Tetsuyuki Ueda, MD, PhD, Tohru Mawatari, MD, PhD, Osamu Izumiyama, MD, PhD, Kiyofumi Morishita, MD, PhD, and Tadashi Hasegawa, MD, PhD

We report a case of repair of the postinfarction ventricular septal perforation (VSP), using an equine pericardium tailored in an asymmetrical conical shape for exclusion (modified sack technique) and an additional direct patch closure of VSP. An asymmetrical conical patch is easily sutured to the normal septum away from the VSP edge by using the longer part of the cone border. The postoperative left ventriculogram 1.5 months after surgery revealed a minor leakage from the patch to the excluded left ventricle. However, no residual left to the right shunt was found in calculation from the oxygen saturation in blood samples. Echocardiography 1 year after surgery showed no residual patch leakage at all. We suggest that this modified sack technique is a simple and easy method by which to exclude the VSP. (Ann Thorac Cardiovasc Surg 2008; 14: 192–195)

Key words: ventricular septal rupture, conical patch, equine pericardium

Introduction

Ventricular septal perforation (VSP) has been recognized as a fatal complication of acute myocardial infarction. The infarction exclusion technique with a xeno-pericardial patch[1] is widely applied to repair the VSP. The technique is that a properly tailored bovine pericardial patch is initially sutured to a healthy endocardium of the septum and then to the free wall of the left ventricle. The size and shape of the patch must be determined to preserve the normal shape of the ventricle. This technique can maintain the postoperative right and left ventricular function. However, the exclusion procedure is a difficult surgical technique because of the need for repair with a continuous suture requiring a large patch placed in a relatively small area.

From Department of Cardiovascular and Thoracic Surgery, Hakodate Municipal Hospital, Hakodate, Japan

Received May 10, 2007; accepted for publication July 2, 2007
Address reprint requests to Hiroki Sato, MD, PhD, Department of Cardiovascular and Thoracic Surgery, Hakodate Municipal Hospital, 1–10–1 Minato-cho, Hakodate, Hokkaido 041–8680, Japan.

In the contrast, Matsuda and associates[2] described a new technique for VSP exclusion with a conical porcine pericardial patch (called the sack technique). They made a conical sack from a porcine pericardium. They placed four stay sutures on the healthy endocardium proximal to the infarct in the septum and lateral ventricular wall. These sutures were then run through the base of the conical sack and knotted, and continuous running sutures were placed between the knots. The authors concluded that this technique provides a good operative view and an easy decision of the suture line.

However, the equine pericardial patch, whose maximum size is 10×10 cm, can now be used only in Japan. A conical sack as large as the one Matsuda made cannot be created from a pericardium of such small size. We made an asymmetrical conical patch to overcome this problem. This technique facilitates the suture of the deep septum away from the VSP. We report this procedure and discuss the surgical treatment of VSP.

Case Report

A 75-year-old woman was referred to our hospital for a

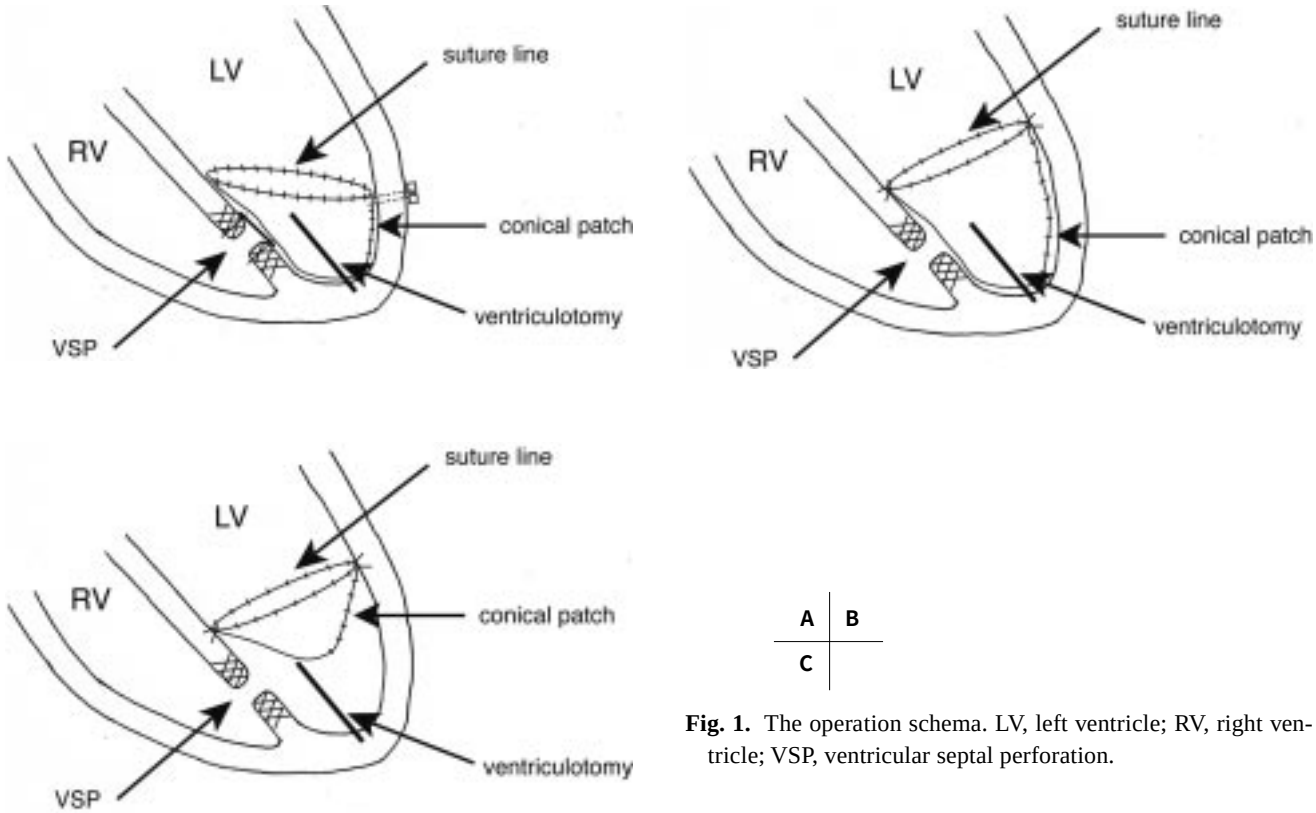

Fig. 1. The operation schema. LV, left ventricle; RV, right ventricle; VSP, ventricular septal perforation.

surgical repair of VSP associated with myocardial infarction of the anterior wall. A preoperative coronary angiogram showed a total occlusion in the left anterior descending artery (LAD) just proximal to the first diagonal artery. A percutaneous coronary intervention (PCI) of the LAD lesion was performed. When the patient was admitted to our hospital, a left-to-right shunt was 36% at the ventricular level, and the pulmonary-to-systemic flow ratio (Qp/Qs) was 1.31 under intra-aortic balloon pumping (IABP) support. Since the VSP shunt flow was not large and hemodynamic conditions were stable, we decided not to operate immediately and waited until the fragile infarcted myocardium underwent fibrosis.

Two weeks after admission, the patient was taken to the operation room to repair the VSP. A cardiopulmonary bypass was established with moderate systemic hypothermia. An aneurysmal dilatation of the left ventricle was seen on the anterior-apical portion. A left anterior ventriculotomy was made parallel to the LAD. Stay sutures were passed through the ventricular muscle to facilitate an exposure of the ventricular cavity. A VSP (12×7 mm) was identified in the lower part of the interventricular wall. During core cooling, the equine pericardium patch, measuring 10×10 cm, was trimmed into an asymmetrical conical sack. Four 3-0 polypropylene stay sutures with Teflon felt pledgets were placed. Two "U" stay sutures were placed on the healthy endocardium proximal to the infarct in the septum, and the remaining two were brought outside the lateral ventricle wall. These sutures were then run through the base of the conical patch. An asymmetrical conical patch can then be easily sutured to the normal endocardium in the septum by using the longer portion of the cone border. The equine pericardium was lowered into the ventricular cavity, and the four stay sutures were knotted. Continuous running sutures were placed between the knots (Fig. 1A). After the exclusion procedure, the VSP was closed with the pericardial patch by six 4-0 polypropylene interrupted sutures. The myocardium around the VSP was still fragile. Therefore the interrupted suture was tied gently (Fig. 2, top). The pericardial patch was inflated with the cardioplegic solution to examine its size and shape after all procedures were finished (Fig. 2, bottom). The left ventriculotomy was closed with a buttressed suture (2-0 Ticron suture) on a Teflon felt strip. No additional coronary bypass grafting was performed. The bypass and aortic cross-clamp times were 195 and 102 min, respectively.

The cardiopulmonary bypass was discontinued with-

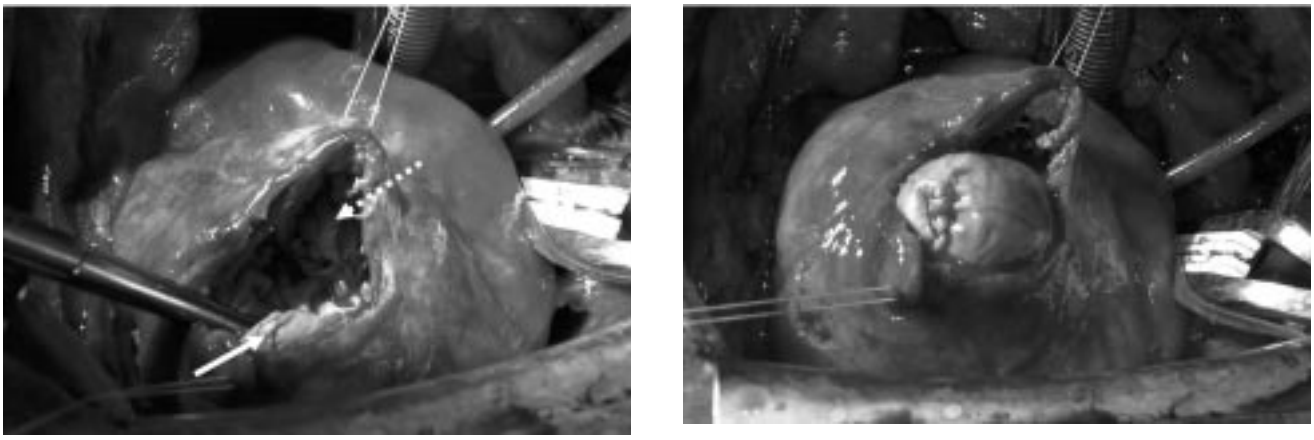

Fig. 2. Intraoperative view. Left: White arrow shows an asymmetrical conical patch. The white dotted arrow shows the VSP patch. Right: Expanded conical patch. The patch was expanded well and close to left ventricular apex.

out difficulty. The IABP was removed on postoperative day 2. A postoperative left ventriculogram 1.5 months after surgery revealed minor leakage (Fig. 3). However, no residual left-to-right shunt was found by calculation from oxygen saturation in blood samples. Echocardiography 1 year after surgery showed no residual leakage. The patient remains in good health to date at 13 months after surgery.

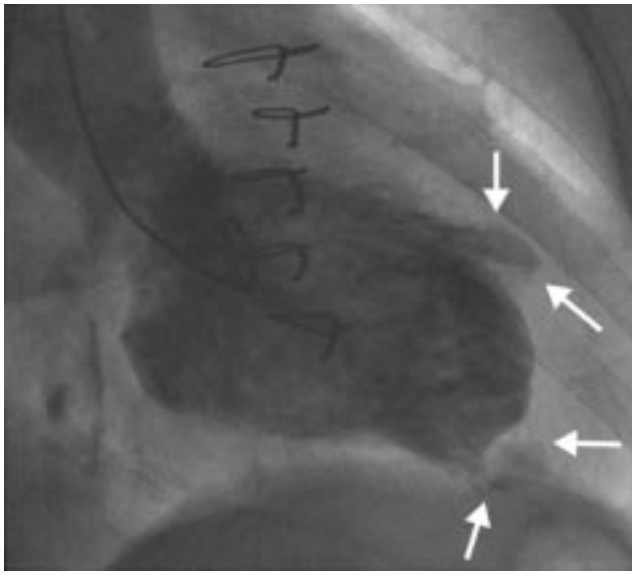

Fig. 3. Postoperative left ventriculogram. Spherical shape of the left ventricular apex was seen with minor leakage from the patch (white arrow).

Discussion

VSP has been recognized as one of the fatal complications of acute myocardial infarction. Cooley and associates first reported the surgical repair of postinfarction VSP in 1957.[3] Daggett and associates established surgical repair for the VSP in 1977.[4] However, the outcomes of surgical repair have not been gratifying. In 1990, Komeda and associates reported the infarction exclusion technique with a xeno-pericardial patch.[1] This technique has improved early results, but the exclusion procedure requires complicated surgical skills.

Matsuda and associates[2] described a new technique for VSP exclusion with a conical porcine pericardial patch (sack technique, Fig. 1B). They applied a conical sack sewn in an inverted fashion with its convex side toward the left ventricular base on the left ventricular endocardium with the suture line at a level proximal to the infarction and parallel to the mitral annular plane. The sack was then reverted wih the convex side toward the left ventricular apex. They concluded that the sack technique provides a good operative view and shortens operation time. It is a simple technique, and the suture line is very easy to determine because it is always a circle. One disadvantage of this technique is that the size of the sack must be decided beforehand. If the sack is too small to fit the cavity, the suture line may be stressed in the diastolic phase of the cardiac cycle. Matsuda and associates[2] used 8 × 16 cm porcine pericardium, so they could create a big sack that had enough convexity. However, such a large patch material is not commercially available in Japan, and 10 × 10 cm equine pericardium is used. In our previous VSP case, we made a conical patch using an equine pericardium with the sack technique. The operation was easy, and no residual left-to-right shunt was observed. But the

convex depth was not enough to obtain a left ventricular apex shape that was elliptical (Fig. 1C). So we made an asymmetrical conical patch from 10 ×10 cm equine pericardium to preserve a good elliptical apex shape. The postoperative left ventriculogram revealed a good elliptical shape. Shibata and associates[5] reported an alternative method for VSP exclusion by a two-patch technique. They used two bovine patches; each patch was individually sutured to the septum and anterolateral ventricular wall. Each patch was trimmed and sutured in the left ventricular cavity. This method enables the surgeon to change the size and shape of the sack. This method still requires a complicated intracardiac procedure that compares to our technique.

The asymmetrical conical patch we made had a 5-cm long border and a 3-cm short border and was 7 cm in diameter. The procedure was carried out smoothly, and the postoperative course was uneventful. The postoperative left ventriculogram 1.5 months after surgery revealed a minor leakage. Fortunately, no residual left-to-right shunt was found in calculation from oxygen saturation in the blood samples. This suggests that the patch that closed the VSP avoided a left-to-right shunt, and it also facilitated a thrombo-occlusion of the excluded left ventricular cavity. In fact, echocardiography 1 year after surgery showed no residual patch leakage at all.

We suggest that this modified sack technique is a simple method that makes it easy to exclude the VSP.

References

1. Komeda M, Fremes SE, David TE. Surgical repair for postinfarction ventricular defect. *Circulation* 1990; **82**(suppl IV): 243–7.
2. Matsuda K, Oda T, Terai H, Hanyu M, Ban T. New surgical technique for repair of ventricular septal perforation. *Ann Thorac Surg* 1995; **60**: 1430–1.
3. Cooley DA, Belmonte BA, Zeis LB, Schnur S. Surgical repair of ruptured interventricular septum following acute myocardial infarction. *Surgery* 1957; **41**: 930–7.
4. Daggett WM, Guyton RA, Mundth ED, Buckley MJ, McEnany MT, et al. Surgery for post-myocardial infarct ventricular septal defect. *Ann Surg* 1977; **186**: 260–71.
5. Shibata T, Suehiro S, Ishikawa T, Hattori K, Kinoshita H. Repair of postinfarction ventricular septal defect with joined endocardial patches. *Ann Thorac Surg* 1997; **63**: 1165–7.