Case Report

Extensive Patch Angioplasty of the Left Main Ostial Stenosis Using a Rhombic-Shaped Pulmonary Autograft

Takashi Miura, MD, Kenji Yamazaki, MD, Shinichiro Kihara, MD, Masayuki Miyagishima, MD, Kensuke Kobayashi, MD, Koichi Sugimoto, MD, and Hiromi Kurosawa, MD

A rhombic shaped pulmonary autograft patch was applied to enlarge an ostial stenosis of the left main coronary artery (LMCA) in a 25-year-old woman diagnosed with vasculitis syndrome. The patch increased the width of the ostial stenosis and made a funnel-shaped connection. At eighteen months of follow-up, a coronary angiogram by computed tomography showed no restenosis at the LMCA. The rhombic-shaped pulmonary autograft patch might be an ideal shape and material for angioplasty of the ostial stenosis of the LMCA. (Ann Thorac Cardiovasc Surg 2008; 14: 263–266)

Key words: vasculitis, ostial stenosis, patch angioplasty, pulmonary artery

Introduction

Patch angioplasty is one of the surgical options in patients with left main ostial stenosis.[1] To get sufficient coronary blood flow, the stenosis needs to be widened. Here we report a case of ostial stenosis repair to produce sufficient diameter, using a rhombic-shaped pulmonary autograft.

Case Report

A 25-year-old woman with angina pectoris showed an isolated 99% stenosis at the ostium of the left main coronary artery (LMCA) (Fig. 1A). The patient had no risk factors of atherosclerosis. The symptoms and clinical findings did not fill Ishikawa's definitive criteria of Takayasu arteritis.[2] Also, A24, B39, B52, and DQ-1 human leukocyte antigen (HLA) haplotypes were not detected.[3] Moreover, other diseases such as Bechet's or Kawasaki were not identified. Therefore she was diagnosed with vasculitis syndrome.

The procedure was performed on October 13, 2005. After a median-sternal incision and pericardiotomy, a dissection was made between the aorta and the main pulmonary artery (MPA). A moderate adhesion was identified between them. A cardiopulmonary bypass (CPB) was initiated via the ascending aorta with bicaval drainage and moderate hypothermia. Under total bypass, the MPA was divided at its bifurcation. A rhombic-shaped patch, 30 mm wide and 25 mm long, was obtained from the anterior wall of the MPA. No inflammatory changes were detected in the MPA. After the dissection of the LMCA, using an ultrasonic scalpel, the aorta was clamped. The heart was arrested by injections of cold blood cardioplegia into the aortic root and coronary sinus. Additional administrations of cardioplegia were given in intermittent retrograde fashion. An incision was made in the midportion of the LMCA and was extended to its ostium. It was also extended to the left anterior descending artery (LAD) by a 5 mm incision because of the short length of the LMCA. Subsequently, an oblique aortic incision, 10 mm long, was made from the anterolateral wall of the

From Department of Cardiovascular Surgery, The Heart Institute of Japan, Tokyo Women's Medical University, Tokyo, Japan

Received June 11, 2007; accepted for publication August 20, 2007
Address reprint requests to Takashi Miura, MD: Department of Cardiovascular Surgery, Nagasaki University, Graduate School of Medicine, 1–7–1 Sakamoto, Nagasaki, 852–8501, Japan.

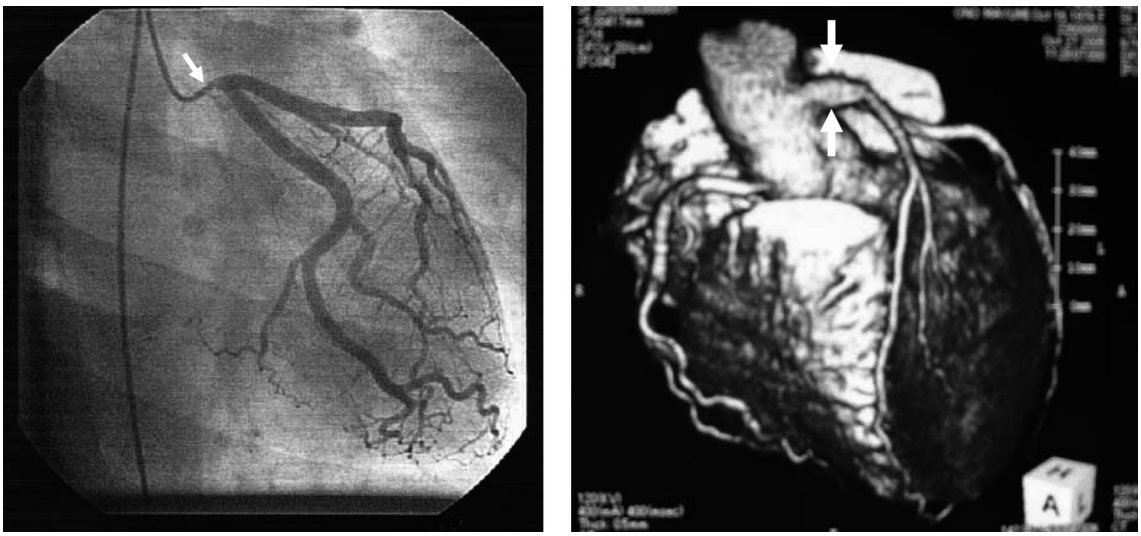

A | B

Fig. 1.
A: A preoperative left coronary angiogram showing a 99% stenosis at the ostium.
B: A postoperative coronary angiogram by computed tomography showing the funnel shape of the entrance to the LMCA.

aorta to the ostium of the LMCA, with care not to cut the aortic valve. The ostial stenosis was opened by joining the aortic and coronary incisions together across its site. The ostial diameter was 2 mm or less with severe intimal thickening of all surfaces. The aortic wall also showed fibrous thickening of the media and adventitia. However, the intimae of the distal portion of the LMCA and the LAD were intact. The pulmonary autograft was carefully sewn into the LMCA, using a 7-0 prolene suture (Ethicon Inc., Somerville, NJ). The diagonal line of the patch (30 mm long) was aligned with the short axis of the LMCA so as to build a ceiling. The patch was applied to enlarge the LMCA and sewn into the adjacent aortic and LAD incisions to avoid kinking of the patch (Figs. 2 and 3). Air in the LMCA was evacuated by performing a terminal warm blood retrograde cardioplegia. After venting was completed, the aorta was declamped. The restoration of the pulmonary artery was performed with the autopericardium under the beating heart. The CPB was discontinued without complications with 75 min of cross lamping and 162 min of pump time. The electrocardiogram did not change after weaning of the CPB. The postoperative coronary angiogram by computed tomography on the 14th day showed that the ostium had increased in diameter by 8 mm and was funnel shaped. The patient was discharged from the hospital on the 22th day after surgery. At eighteen months of follow-up, a coronary angiogram by computed tomography showed no restenosis of the LMCA (Fig. 1B).

Discussion

Patch angioplasty of the ostial stenosis of the LMCA is one of the surgical options in ostial stenosis, as is CABG. Excellent results for these procedures were reported by Dion et al.[1] and Jegaden et al.[4] Patch angioplasty provides physiologically antegrade blood flow, allows percutaneous transluminal angioplasty later, and saves bypass material. The technical points of the patch angioplasty were described by Dion et al.[1] In this patient, we applied the anterior approach with the division of the MPA and retrograde cardioplegia proposed by Dion et al.,[1] which allowed a good exposure of the LMCA and myocardial protection.

The properties of the patch material, including its size, antithrombotic effect, and possibility of the development of restenosis have been discussed in many reports.[1,5,6] However, the importance of the shape of the patch has not been discussed. Therefore we had an interest in the relationship between the configuration of the stenosis of the LMCA and the patch shape. In this case, the configuration of the stenosis was an ostial stenosis with intimal thickening of all surfaces. Therefore we applied a rhombic-shaped patch to

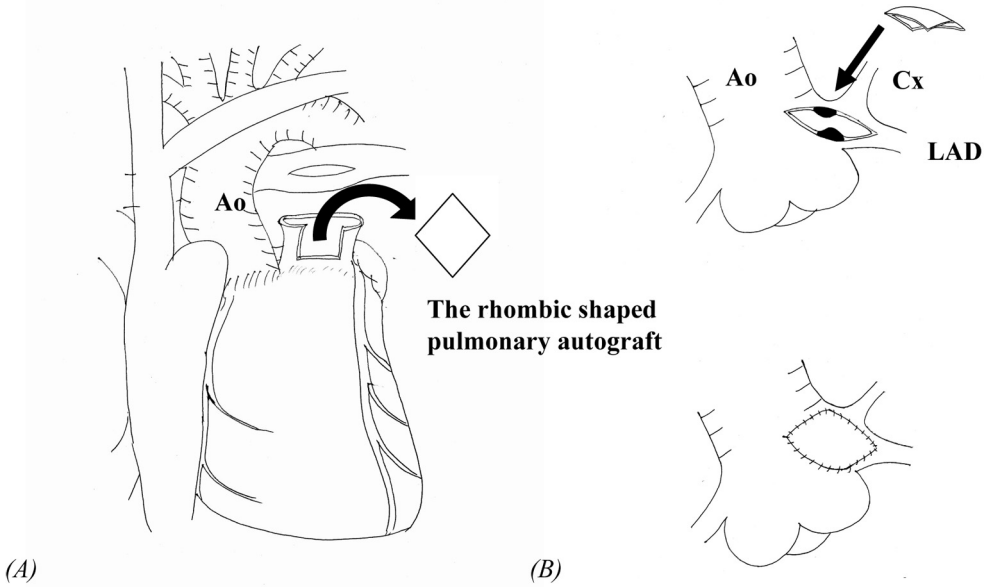

Fig. 2.
A: A rhombic-shaped patch, 30 mm wide and 25 mm long, was obtained from the anterior wall of the MPA.
B: The pulmonary autograft was carefully sewn into the LMCA, using a 7-0 prolene suture (Ethicon Inc., Somerville, NJ). The diagonal line of the patch (30 mm long) was aligned with the short axis of the LMCA so as to build a ceiling.
Ao, aorta; LAD, left anterior descending artery; Cx, circumflex artery.

enlarge the ostium so as to build a ceiling in the short axis of the LMCA. The patch was sewn into the LAD and the aorta to keep it from kinking.

We selected a pulmonary autograft because of its adequate width, identical embryological origin with the wall of the aorta, elastic and fibrinolytic properties, and the ability to withstand a high pressure without the development of dilatation and calcification after the operation.[5] Autovein or autopericardium were not applied because they might be expected to be less durable than autoarterial patches.[5,6] Also, an internal mammary artery was not selected because of its limited width.

The preoperative clinical findings in this patient did not fulfill Ishikawa's definitive criteria of Takayasu's arteritis.[2] However, this patient might belong in the category of the Takayasu's arteritis from the findings of the aorta during the procedure. Takayasu's arteritis has pulmonary artery lesions in 45%–56.1%[7,8] of patients. Therefore careful clinical follow-up is needed to monitor a recurrence of the restenosis of the new ostium.

Although our experience is limited, we believe that the rhombic-shaped pulmonary autograft patch is an ideal shape and material for angioplasty of the ostial

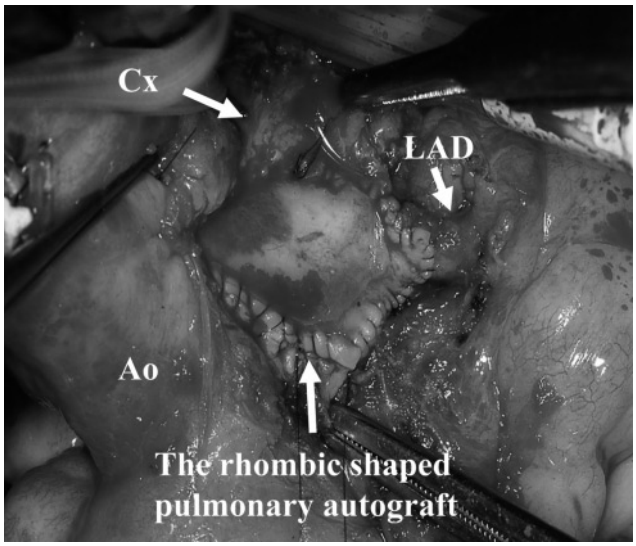

Fig. 3. The rhombic-shaped pulmonary autograft increased the size of the LMCA and the adjacent aortic and LAD incisions so as to avoid kinking of the patch.
Ao, aorta; LAD, left anterior descending artery; Cx, circumflex artery.

stenosis of the LMCA.

References

1. Dion R, Elias B, El Khoury G, Noirhomme P, Verhelst R, et al. Surgical angioplasty of the left main coronary artery. *Eur J Cardiothorac Surg* 1997; **11**: 857–64.
2. Ishikawa K. Diagnostic approach and proposed criteria for the clinical diagnosis of Takayasu's arteriopathy. *J Am Coll Cardiol* 1988; **12**: 964–72.
3. Takeuchi Y, Matsuki K, Saito Y, Sugimoto T, Juji T. HLA-D region genomic polymorphism associated with Takayasu's arteritis. *Angiology* 1990; **41**: 421–6.
4. Jegaden O, Eker A, Durand de Gevigney G, Montagna P, Ossette J, et al. Surgical angioplasty of the coronary trunks: an alternative to bypass techniques. *Coron Artery Dis* 1994; **5**: 519–24.
5. Malyshev M, Gladyshev I, Safuanov A, Siniukov D, Borovikov D, et al. Surgical angioplasty of the left main coronary artery and/or proximal segment of the right coronary artery by pulmonary autograft patch. *Eur J Cardiothorac Surg* 2004; **25**: 21–5.
6. Suma H, Amano A, Nabuchi A. Left main coronary artery patch plasty with internal mammary artery. *Cardiovasc Surg* 1994; **2**: 223–5.
7. Lupi E, Sánchez G, Horwitz S, Gutierrez E. Pulmonary artery involvement in Takayasu's arteritis. *Chest* 1975; **67**: 69–74.
8. Sharma S, Kamalakar T, Rajani M, Talwar KK, Shrivastava S. The incidence and patterns of pulmonary artery involvement in Takayasu's arteritis. *Clin Radiol* 1990; **42**: 177–81.