Case Report

A Case of Abdominal Aortic Aneurysm with Horseshoe Kidney

Satoru Makita, MD,[1] Tomoya Yoshizaki, MD, PhD,[2] and Noriyuki Tabuchi, MD, PhD[2]

A 69-year-old male who had an abdominal aortic aneurysm with horseshoe kidney is reported. Preoperative 3-dimensional computed tomoangiography (3DCTA) images confirmed two accessory renal arteries diverging from the aneurysm to the isthmus. We operated on the abdominal aortic aneurysm using the left retroperitoneal approach, which provided excellent exposure of the aneurysm without dividing the renal isthmus. This exposure showed us the accessory arteries, so we could easily recognize these arteries visualized by 3DCTA, and we could reconstruct the larger one of two accessory arteries. Preoperative 3DCTA was very useful for the operation of the abdominal aortic aneurysm with horseshoe kidney. The postoperative course was uneventful. (Ann Thorac Cardiovasc Surg 2009; 15: 129–132)

Key words: horseshoe kidney, abdominal aortic aneurysm, left retroperitoneal approach, accessory renal artery

Introduction

The horseshoe kidney, one of the commonest anomalies of the kidney, is thought to occur in 0.25% of the population with the frequency doubled in males.[1)] The isthmus connecting the lower poles may be a fibrous band or may contain functional parenchymal tissue. The arterial anomalies supplying the horseshoe kidney have been reported in 60% to 74% of patients.[2,3)] When these patients accompany the abdominal aortic aneurysm, it is important to obtain detailed information about the arteries supplying the horseshoe kidney before the operation. In the present case, by using 3-dimensional computed tomoangiography (3DCTA) we could successfully obtain precise information about these accessory arteries. During the operation to replace the abdominal aortic aneurysm, we could easily recognize them as visualized by 3DCTA, and one of the largest was reconstructed. The postoperative course was uneventful.

From [1]Department of Cardiothoracic Surgery, Ome Municipal General Hospital, Tokyo; and [2]Department of Cardiovascular Surgery, Yokohama City Minato Red Cross Hospital, Yokohama, Japan

Received March 31, 2008; accepted for publication April 9, 2008
Address reprint requests to Satoru Makita, MD: Department of Cardiothoracic Surgery, Ome Municipal General Hospital, 4–16–5 Higashiome, Ome, Tokyo 198–0042, Japan.

Case Report

A 69-year-old male treated for hypertension was hospitalized with acute dissection localized in the descending thoracic aorta (Stanford Type B, DeBakey Type IIIa). Computed tomography (CT) revealed that he presented an infrarenal abdominal aortic aneurysm (70 mm in diameter), which extends to the bifurcation of common iliac arteries, and also a horseshoe kidney. The thrombosed aortic dissection was treated conservatively. When the patient was in the chronic stage two months after onset of the dissection, an operation of the abdominal aortic aneurysm was scheduled. Two accessory arteries were confirmed by 3DCTA images, one of which was a very narrow accessory artery (Fig. 1) originating near the bifurcation of iliac arteries and leading to the lower end of the isthmus of the horseshoe kidney. The other artery was very short, but wide from the anterior surface of the

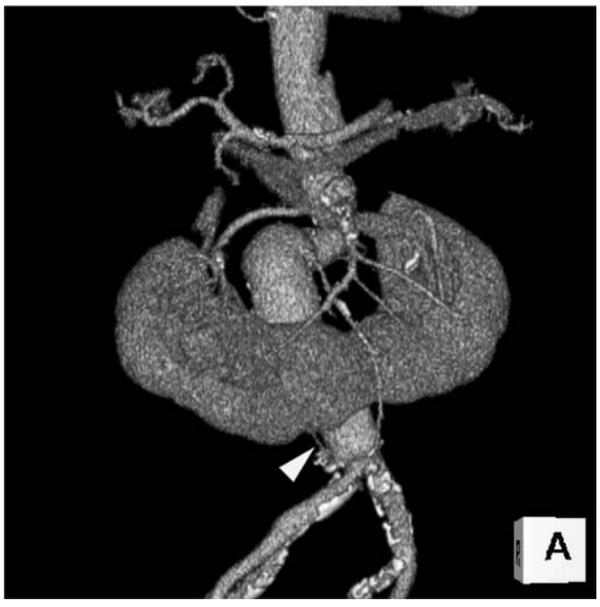

Fig. 1. The anterior view of the preoperative 3DCTA showed the smaller of two accessory arteries.

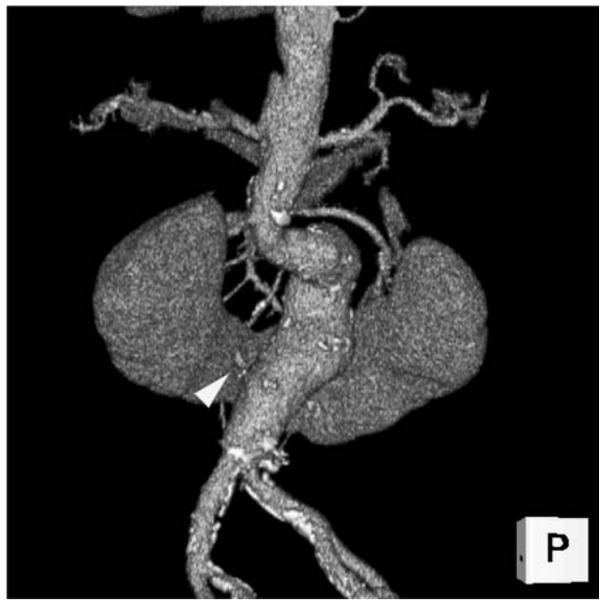

Fig. 2. The posterior view of the preoperative 3DCTA showed the larger one of two accessory arteries at the dorsal surface of the horseshoe kidney's isthmus.

abdominal aortic aneurysm to the dorsal surface of the isthmus (Fig. 2).

A surgical procedure was performed in the right semilateral position using Risberg's incision, an oblique incision in the left retroperitoneal approach. The renal isthmus was easily separated from the aneurismal aorta. The short accessory artery that diverged from the anterior surface of the aneurysm was identified. It was 5 mm in diameter. The abdominal aorta was clamped under the left and right main renal arteries. An 18 × 9 mm bifurcated Dacron graft (18 × 9 mm, Gelsoft™, Vascutek) was inserted. The right leg was anastomosed to the right common iliac artery. Because of severe calcification, the left common iliac artery was closed, and the left leg was anastomosed to the left external iliac artery in end-to-side fashion. After the distal anastomosis of the prosthesis was completed, 60 ml of cold saline (4°C) was infused into the accessory renal artery. The accessory artery was interposed by the great saphenous vein and anastomosed to the right leg of the prosthesis (Fig. 3). It was then clamped for 140 minutes. Another small accessory renal artery, observed by the preoperative 3DCTA, was confirmed in the far end of the isthmus. However, we did not reconstruct this small artery (less than 2 mm in diameter) because we could not find the opening inside the aneurysm.

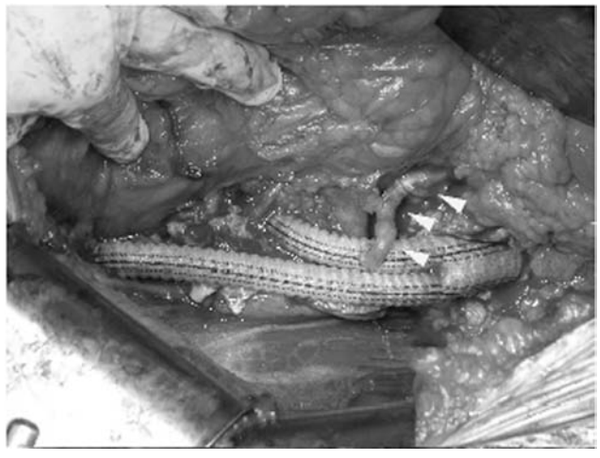

Fig. 3. The larger accessory artery was reconstructed with the great saphenous vein.

The patient showed a good postoperative course, and no blood transfusion was required. The postoperative abdominal 3DCT showed the successful replacement of the aortic aneurysm, and the patency of the reconstructed accessory renal artery was confirmed (Fig. 4). There were no signs of renal infarction. The patient was discharged on the 12th postoperative day with no postoperative change in renal function.

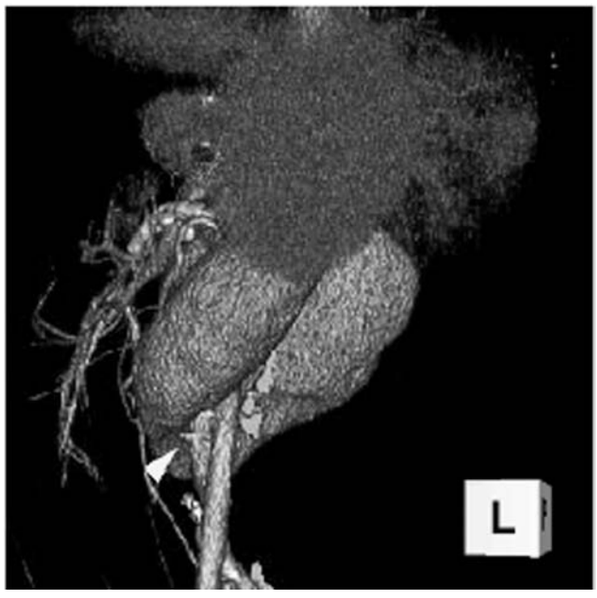

Fig. 4. Postoperative 3DCTA confirmed the reconstructed accessory artery.

Discussion

A horseshoe kidney occurs in approximately 0.25% of the population, or about 1 in 400 persons. It is twice as common in males as in females.[1] Numerous cardiovascular anomalies have been reported to accompany it.[4–6] The blood supply to the horseshoe kidney can be quite variable, especially in the isthmus and lower poles. The abnormalities of blood supply have been reported in 60% to 74% of patients with horseshoe kidneys.[2,3,7] Usually, the isthmus and lower poles have their own accessory renal artery from the aorta or iliac arteries. Anatomically, the blood supply to the horseshoe kidney is controlled segmentally by the accessory arteries, and the collateral blood flow between the segments is minimum. Therefore the ligation of the accessory arteries might result in ischemia of the renal isthmus.[8] O'Hara et al. reported that the occurrence of the renal ischemia was as high as 74% and recommended reconstructing the accessory artery whenever its diameter is 2 mm or more.[7] To reconstruct the accessory arteries, it is important to obtain detailed information about the arteries supplying the horseshoe kidney and also about the anatomical relationships between the horseshoe kidney, the accessory arteries, and the aneurysm. A CT scan provides the most detailed information about the horseshoe kidney in 90% of all cases,[7] whereas angiography reveals the association between the horseshoe kidney and the accessory arteries in only 67%.[7] In the present study, we could obtain precise information about the accessory arteries to the horseshoe kidney by using 3DCTA. Therefore we could easily recognize these arteries as visualized by 3DCTA and successfully reconstruct the largest of them. We ligated the other accessory artery, which appeared extremely difficult to reconstruct because its diameter was less than 2 mm. The renal function did not deteriorate after surgery, and no renal infarction was found in the postoperative CT. Our experience is in agreement with O'Hara that an accessory artery with a diameter of more than 2 mm needs reconstruction. Stroosma et al.[9] studied 176 cases in the literature and concluded that ligation of a small accessory artery diverging from an aneurysm did not affect postoperative renal functions.

The choice of a retroperitoneal approach appears important in the present case. We expect that the reconstruction of the accessory artery might be extremely difficult if we choose a transperitoneal approach, because the accessory artery was quite short and connected to the back wall of the isthmus of the horseshoe kidney. To obtain the good view of the whole aneurysm, some authors reported that they resected the isthmus in the transperitoneal approach. After resection of the isthmus, however, there are possibilities of hemorrhage, of formation of a hematoma in the retroperitoneum, or of vascular prosthesis infection associated with urine leakage. Stroosma et al.[9] documented that of the 134 elective operations, 115 were performed using the transperitoneal approach. In 31 cases, the isthmus of the horseshoe kidney was resected. Five cases developed renal failure, of which 4 had the isthmic resection. One case of isthmic resection was reported to have developed retroperitoneal hematoma resulting from a hemorrhage at the resection site and underwent the surgical operation again.

We consider that the preoperative 3DCTA is quite informative for the arteries supplying the horseshoe kidney. A surgical procedure is best performed in the retroperitoneal approach to avoid resection of the isthmus. And an accessory artery with a diameter of more than 2 mm requires reconstruction.

References

1. Bauer SB. Anomalies of the upper urinary tract. Campbell's Urology, 8th ed., Walsh PC, Retik AB, Vaughan ED, Jr, eds. Saunders: Philadelphia, 2002; pp 1903–6.

2. Gleen JF. Analysis of 51 patients with horseshoe kidney. *N Engl J Med* 1959; **261**: 684–7.
3. Connelly TL, McKinnon W, Smith RB 3rd, Perdue GD. Abdominal aortic surgery and horseshoe kidney. *Arch Surg* 1980; **115**: 1459–63.
4. Grainger R, Murphy DM, Lane V. Horseshoe kidney—a review of the presentation, associated congenital anomalies and complications in 73 patients. *Ir Med J* 1983; **76**: 315–7.
5. Segura JW, Kelalis PP, Burke EC. Horseshoe kidney in children. *J Urol* 1972; **108**: 333–6.
6. Zondek LH, Zondek T. Horseshoe kidney and associated congenital malformations. *Urol Int* 1964; **18**: 347–56.
7. O'Hara PJ, Hakaim AG, Hertzer NR, Krajewski LP, Cox GS, et al. Surgical management of aortic aneurysm and coexistent horseshoe kidney: review of a 31-year experience. *J Vasc Surg* 1993; **17**: 940–7.
8. Bietz DS, Merendino KA. Abdominal aneurysm and horseshoe kidney: a review. *Ann Surg* 1975; **181**: 333–41.
9. Stroosma OB, Kootstra G, Schurink GW. Management of aortic aneurysm in the presence of a horseshoe kidney. *Br J Surg* 2001; **88**: 500–9.