Review

Periannular Extension of Infective Endocarditis

Ning Kang, MD, Song Wan, MD, PhD, FRCS, Calvin S.H. Ng, MD, FRCS, and Malcolm J. Underwood, MD, FRCS

The periannular extension of infection is one of the most dangerous complications in patients with infective endocarditis (IE) and can significantly impact on the prognoses of these patients. The accurate detection and delineation of periannular complications are crucial in patient management, which may also provide guidance for surgical intervention. Echocardiography is the preferred imaging examination in both native and prosthetic valvular infections. However, it remains a great challenge for surgeons to successfully treat infections from panresistant organisms. Although *staphylococci* are reported to be the most common cause of aorto-cavitary fistulae, the association between this pathogen and clinical characteristics and patient outcome remains to be proven. Conversely, it has been observed that *S. aureus* is the most common cause of aorto-cavitary fistulae in patients with native valve endocarditis. The optimal management of patients with periannular extension of IE requires a multidisciplinary approach, with surgical input being an integral part of the treatment associated with the evolution of complex reconstructive techniques. (Ann Thorac Cardiovasc Surg 2009; 15: 74–81)

Key words: fistula, infective endocarditis, aortic valve, mitral valve

Introduction

The earliest reports of infective endocarditis (IE) date back to 1554 when Fernel first described it in his book *Medicini*. Subsequently, throughout the 18th and 19th centuries, numerous references were made to the disease by such well-known physicians as Morgagni and Virchow.[1] It was not until 1885, however, that a Canadian, Sir William Osler, amalgamated the work of others and presented a comprehensive account of the disease in three Gulstonian Lectures at the Royal College of Physicians.[1] Although IE is most commonly associated with a process that involves valve leaflets, it may also affect the chordae, myocardium, paraprosthetic tissue, implanted shunts, conduits and fistulae. Moreover, patients with congenital heart defects are at increased risk of developing IE.[2]

Periannular extension of IE occurs in about 10 to 40% of native valve IE and is more commonly seen in the aortic position.[3] However, in patients with prosthetic valve IE, the incidence may increase to 56 to 100%, with the prosthetic valve annulus being the primary site of infection.[3] Potential complications from a periannular extension of IE include periannular abscesses, pseudoaneurysm formation of the mitral-aortic intervalvular fibrosa, and the subsequent development of aorto-cavitary fistulous tract. Such conditions may lead to increased mortality resulting from congestive heart failure (CHF) and therefore predispose a greater need for surgical intervention.[2,3] In a recent retrospective, multicenter analysis of 4,681 episodes of IE, 76 patients (1.6%) developed aorto-cavitary fistulae.[4] It is important to note that this occurred only in the aortic position and was more

From Division of Cardiothoracic Surgery, Department of Surgery, The Chinese University of Hong Kong, Prince of Wales Hospital, Shatin, Hong Kong, People's Republic of China

Received June 4, 2008; accepted for publication July 28, 2008
Address reprint requests to Song Wan, MD, PhD, FRCS: Division of Cardiothoracic Surgery, Department of Surgery, The Chinese University of Hong Kong, Prince of Wales Hospital, Shatin, NT, Hong Kong, People's Republic of China.
©2009 The Editorial Committee of *Annals of Thoracic and Cardiovascular Surgery.* All rights reserved.

frequently found in prosthetic than in native valve endocarditis (5.8% vs. 3.6%). Sixty-six of these patients (87%) underwent surgical treatment.[4)]

Pathophysiology

When annular infection affects contiguous tissue, pyogenesis, and tissue necrosis may result in the formation of an abscess cavity. The weakened necrotic myocardium may expand and rupture, thus creating intracardiac fistulous communications or even pericardial shunts. In native aortic valve IE, this generally occurs at the weakest portion of the annulus, which is near the membranous septum and the atrioventricular node. Anatomic vulnerability explains why abscesses often develop at this particular site. Heart block is another frequently encountered complication. Anguera et al.[4)] observed that in 78% of these 4,681 cases of periannular abscess (with a median abscess diameter of 12 mm), the site of origin of the fistulous tract was equally distributed among the three sinuses of the Valsalva, and the four cardiac chambers were also equally involved. The most common fistulous tracts included the right coronary sinus to the right ventricle, the noncoronary sinus to the right ventricle, and the left coronary sinus to the left atrium. Nearly half of the patients developed moderate to severe aortic regurgitation.[4)]

In patients with aortic regurgitation that is secondary to aortic valve endocarditis, the regurgitant jet may cause the local spread of infection as it strikes the subaortic structures. Such a condition can lead to aneurysmal change or perforation of the anterior mitral valve leaflet. If the jet impinges on the mitral-aortic intervalvular fibrosa (a fibrous interannular tissue between the base of the anterior mitral leaflet and the left and noncoronary aortic cusps), it may result in the formation of abscess or pseudoaneurysm.[1,5)] This stems from the mitral-aortic intervalvular fibrosa being relatively avascular and having little resistance to infection.[6)] Kasper et al.[7)] also proposed that the direct extension of IE from the mitral valve leaflets and direct contact with vegetation are possible underlying mechanisms for this type of infection. Less commonly, a pseudoaneurysm of the mitral-aortic intervalvular fibrosa may cause rupture either into the pericardial sac, thus resulting in fatal hemopericardium, or into the left atrium with increased mitral regurgitation.[8)] Such a pseudoaneurysm may also remain intact and appear as a pulsatile echo-free cavity in systole posterior to the aortic root.[8)]

In some cases (19%–23% of those reported by Anguera et al. in 2006[6,9)]), progressive periannular infection may disrupt ventricular-aortic continuity or the mitral-aortic trigone and lead to catastrophic intracardiac fistulae. Even if they are hemodynamically tolerable, such lesions usually never heal with medical treatment alone, but require urgent surgical intervention.[2)]

Clinical Features

The onset of a new murmur and persistent swinging fever (probability value 0.31)[10)] should alert the clinician to the possibility of periannular complications of IE. Furthermore, the occurrence of electrical conduction disturbances, such as atrioventricular block or a newly developed bundle-branch block, are also important indicators.[1,2,5)] In fact, electrocardiogram evidence of a newly developed atrioventricular block has a positive predictive value of 88% for abscess formation.[3)] The acute onset of heart failure with or without associated organ dysfunction (i.e., renal and hepatic impairment) is often overlooked, but it may suggest the new formation of fistula or the development of hemopericardium. In the multicenter clinical observation by Anguera et al.,[4)] patients with aorto-cavitary fistulae had high incidence of heart failure (over 60%) and mortality (over 40%). The authors found that moderate or severe heart failure was an independent risk factor for death, although severe aortic regurgitation was not associated with increased mortality.[4)] Nevertheless, transesophageal echocardiography (TEE) is the modality of choice in evaluating potential periannular extension.[4,11–13)]

Microbiology

Numerous organisms can cause IE, but *staphylococci* and *streptococci* are responsible for most IE cases. The organisms that should be included in the differential diagnoses include *S. aureus*, viridans group *streptococci*, *enterococci*, coagulase-negative *staphylococci*, *Streptococcus bovis*, and the HACEK organisms (a group of fastidious, oral gram-negative bacilli—the *Hemophilus* species [*Hemophilus parainfluenzae*, *Hemophilus aphrophilus* and *Hemophilus paraphrophilus*], *Actinobacillus actinomycetemcomitans*, *Cardiobacterium hominis*, *Eikenella corrodens*, and the *Kingella* species),[14)] besides such emerging infectious agents as *Tropheryma whipplei*, *Bartonella* spp., and *Rickettsia* spp.[15)] More recently, reported series from major referral centers have suggested that *S. aureus* has

surpassed viridans *streptococci* as the most common cause of endocarditis in this setting.[16)]

In a study by Anguera et al., *staphylococci* were the most common microorganisms, being responsible for 35 (46%) episodes of aorto-cavitary fistulae. *S. aureus*, in particular, was more frequent in native endocarditis than it was in prosthetic valve endocarditis (29% vs. 10%, p <0.05), though the opposite was the case with coagulase-negative *staphylococci* (48% vs. 9%, P = 0.001).[4)] Some methicillin-resistant strains were identified among both pathogens. Other microorganisms that have been implicated in aorto-cavitary fistulae formation include *streptococci* (33%), *enterococci* (5%), and a few fungal or polymicrobial infections.[4)]

Surgical Management

It is well recognized that CHF accounts for almost 90% of deaths in patients with IE. Therefore evidence of structural complications or cardiac extension of the infection, especially in the presence of CHF, indicates surgical intervention.[17,18)] In a study of 108 patients with a high prevalence of CHF (75%) secondary to IE, medical therapy alone (n = 85) was associated with significantly higher mortality (51%) than surgical intervention was (n = 23, 9%, P = 0.0001).[19)] Therefore early surgery is recommended for patients with native valve endocarditis and moderate or severe heart failure.[17–21)] Graupner et al.[3)] further emphasized the importance of early surgical intervention in the presence of the periannular extension of IE to eradicate the infection and to correct hemodynamic disorders, even if no differences were shown in the presence or size of vegetations or the frequency of embolism. However, surgical procedures in patients with the periannular extension of IE may be more complicated and are associated with higher mortality and morbidity than are simple valve replacements or the repair of uncomplicated active endocarditis.[21)] Surgery often requires the drainage of abscess cavities, the excision of necrotic tissue, and the closure of fistulous tracts. Extensive destruction of the periannular supporting tissues may further complicate the implantation of valvular prosthesis.

Regardless of the preoperative echocardiographic detection of periannular complications, the classic indications for surgical intervention remain, such as heart failure, persistent signs of infection (usually coexistent with CHF), and major central nervous system embolic events. In particular, patients with *staphylococcal* native valve endocarditis should undergo early surgical intervention regardless of their hemodynamic status[17)] because the organism is notoriously difficult to eradicate with medical therapy alone. In patients with isolated right-sided IE and embolic phenomena, however, a more conservative approach is recommended; this type of IE has a less pronounced impact on hemodynamics and has a reported mortality rate of less than 10%.[17,20)]

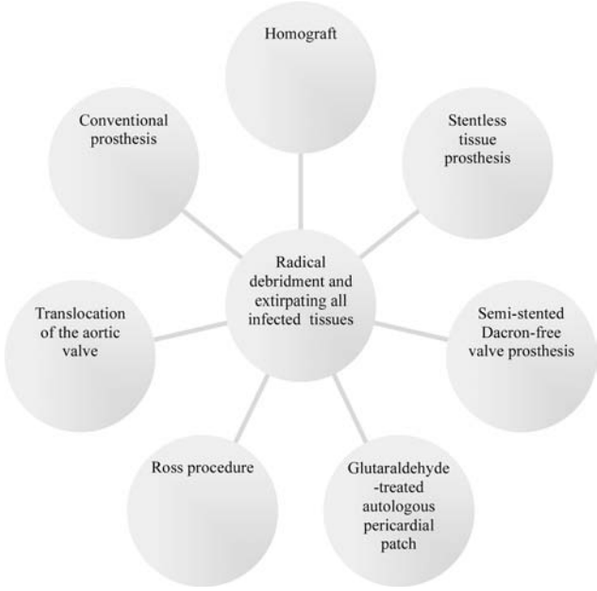

Fig. 1. Techniques applied for aortic periannular extension of endocarditis.

It is worth mentioning that a small number of patients with the periannular extension of infection may be treated successfully without surgical intervention.[20,21)] These patients may include those who have small (< 1 cm) abscesses in the absence of such serious complications as heart block, valvular dehiscence, or insufficiency, and those without echocardiographic evidence of abscess progression over the full course of medical therapy. Such patients should be monitored closely with serial TEE at intervals of two, four, and eight weeks after the completion of antimicrobial treatment.

1. Periannular extension of aortic valve IE

Figure 1 summarizes some of the techniques that are used for the aortic periannular extension of endocarditis. In general, repair is preferable to replacement in the situation of aortic and mitral valve IE, though repair is less frequently feasible for the aortic valve than it is for the mitral valve. Lesions that are limited to one cusp and that

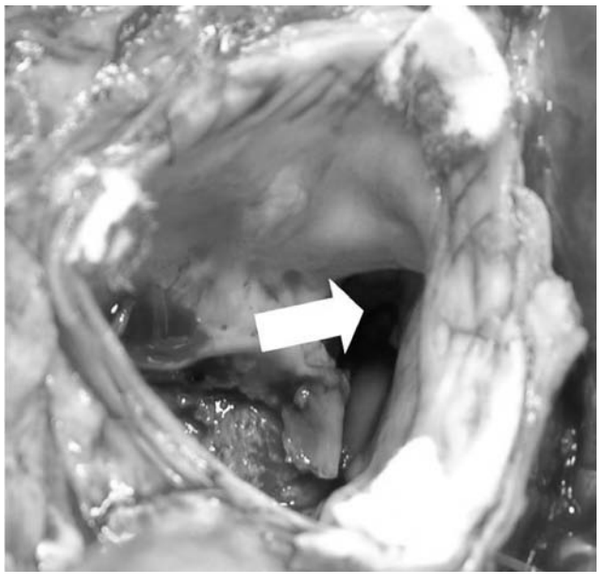

Fig. 2. Aortic prosthetic valve endocarditis.
Arrow indicates periannular abscess.

spare the annulus can be removed and reconstructed with tailored pericardium. When the annulus is involved (Fig. 2), annuloplasty should accompany cusp reconstruction. If the abscess or other structural damage extensively involves the aortic structures, aortic root replacement should then be the procedure of choice. The involvement of the aortomitral curtain and the anterior mitral leaflet requires a complicated surgical approach through both the left atrium and the ascending aorta to perform the extensive debridement and reconstruction of the left atrium and the atrial septum. Homografts, which often include the anterior mitral leaflets, offer the optimal material for repairing such defects, sometimes with a pericardial patch that also serves as an anchor for suturing the aortic homograft in place. Alternatively, the aortomitral curtain of the aortic homograft can be used to repair the defect that results from the debridement.[22]

1.1 Homograft

In 1972, Donaldson and Ross proposed the aortic homograft to replace an infected aortic valve, and this was reported in 1984.[23] In 2005, Yankah et al.[24] presented their 17-year clinical results of aortic root reconstruction with a cryopreserved aortic homograft in 161 patients with periannular aortic root abscess from active aortic valve endocarditis. These results showed 9.3% operative mortality; 91% freedom from recurrent infection at 10 years; 82.9% freedom from reoperation at 17 years; and 87% survival at 11 years, compared with 61% for prosthetic valves in other series.[24–26] Furthermore, in a series from the Cleveland Clinic, 103 prosthetic aortic valve endocarditis patients (78% of whom also presented with aortic root abscess) were treated exclusively with an aortic valve homograft. The operative mortality was only 3.9%, and the 5- and 10-year survivals were 73% and 56%, respectively.[27] The instantaneous risk of recurrent endocarditis peaked at nine months, and the freedom from recurrent endocarditis at 5 and 10 years was 95%.[27] Taken together, these studies provide evidence that the aortic homograft has satisfactory durability and a low endocarditis recurrence rate. By virtue of its permeability to serum antibiotics, it is more resistant to biofilm bacterial infection.[21,24] Although it is generally considered to be a more protective conduit against recurrent infection than prosthetic valves are after a radical operation in which active endocarditis associated with periannular aortic root abscess is present at the time of surgery, an undersized homograft was identified as an incremental risk factor for reoperation. Also, the limited availability of homografts in all sizes opens an option for the use of pericardial-covered stentless bioprostheses, such as the Shelhigh Stentless prostheses.[2,5,24]

1.2 Stentless bioprostheses

Siniawski et al.[28] studied a series of patients with annulus abscesses implanted with 75 Shelhigh no-react prostheses, and a control group comprising 68 consecutive patients who were implanted with aortic homografts. The 60-day mortality was 12% in the study group versus 16% in the control group. Recurrent infection occurred in 4% of the patients in both groups. The instantaneous and mean Doppler gradients, the mean effective orifice area, and the left ventricular ejection fraction yielded no significant differences between the treatment groups.[28] Thus their experience with both the Shelhigh no-react superstentless and the stentless aortic valve conduits in patients with native or prosthetic aortic valve endocarditis appears to demonstrate good results, similar to those with cryopreserved homografts. Another series of 108 patients suffering from root abscesses, which used Shelhigh prostheses (27), homografts (17), and two-stented valve prostheses (9), also indicated that double-valve surgery with semistented Dacron-free valve prostheses is associated with a low rate of reinfection and good functioning of the implants.[29]

Table 1. Comparison of multiple conduits for periannular extension of aortic valve endocarditis

Study	Conduit /prosthesis	No. of patients	Periannular aortic root abscesss (%)	Operative mortality (%)	Freedom from recurrent infection (follow-up duration)	Freedom from reoperation (follow-up duration)	Survival rate (%) (follow-up duration)
Yankah et al. (2005)[24]	Homograft in NVE	161	100	9.3	91% (10 years)	82.9% (17 years)	87 (11 years)
Sabik et al. (2002)[27]	Homograft in PVE	103	78	3.9	95% (10 years)	–	73 (5 years) 56 (10 years)
Siniawski et al. (2005)[29]	Shelhigh no-react stentless (prostheses)	75	100	12 (60 days)	96 (17 ± 10 months)		
	Homograft	68	100	16 (60 days)	96 (17 ± 10 months)		
Kon et al. (2002)[34]	Stentless porcine aortic root bioprosthesis	104		3.9	96.9 (8 years)	100 (8 years)	59.8 (8 years)
Schmidtke et al. (2007)[30]	Ross procedure	296		0.3	0 (47.3 ± 28.6 months)		99.7 (47.3 ± 28.6 months)
Avierinos et al. (2007)[35]	Homograft	54	63	9	44 ± 10% (10 years survival-free from the combined endpoint, including recurrence IE, prostheses dysfunctions, and long-term cardiovascular mortality)		
	Conventional prosthesis	73					

NVE, native valve endocarditis; PVE, prosthetic valve endocarditis; IE, infective endocarditis.

1.3 Ross procedure

The Ross procedure may also be a viable option as a replacement valve-conduit for aortic valve IE. Schmidtke et al.,[30] in a series of 296 patients who underwent the Ross procedure using the subcoronary and inclusion technique for endocarditis, found that early mortality was extremely low at 0.3%. Furthermore, there was no late mortality, no recurrence of endocarditis, and no neurological events during the mean follow-up of 47 months. Postoperatively, the patients were in the New York Heart Association Class I status, and the pressure gradient across the autograft was normal[30] (Table 1).

1.4 Other surgical techniques

Nottin et al.[31] indicated that homografts are fraught with high early calcification rates and problems of availability. They published a study based on their 22-year experience of translocation of the aortic valve that permitted the surgical repair of ventriculo-aortic disconnection and aortic root damage following prosthetic valve endocarditis in 21 patients. They showed that this procedure is an alternative to homografts when they are unavailable.[31] Müller et al.[32] planted a freestyle aortic root xenograft in 10 consecutive patients with extensive abscess formation. Although there were two postoperative deaths, all of the other patients were well 12 to 42 months after surgery.[32] Bozbuga et al.[33] performed aortic annular skeletonization by dissecting all of the infection and necrotic tissue within the abscess cavity and the fistula between the ventriculoarterial junction and the sinotubular junction. A glutaraldehyde-treated autologous pericardial patch was used to cover the completely resected annular area, followed by implantation of a freestyle stentless bioprosthesis.[33] At eight years, there was 83.3% freedom from thromboembolic complications, 96.9% from postoperative endocarditis, and 100% from reoperation with the implanted freestyle bioprostheses of Kon et al.[34]

However, Avierinos et al.[35] reported 127 consecutive patients with active aortic endocarditis, of whom 63 (50%) had annulus abscess; 54 (43%) were treated with aortic homograft and 73 (57%) with conventional prosthesis. In-hospital mortality was 9% for both groups. There was also no difference between the two groups in 10-year survival free from combined endpoints (including IE recurrence, prostheses dysfunction, and long-term cardiovascular mortality), which was 44 ± 10%. Sung et al.[36] even demonstrated 13 cases of repairs to disrupted ventriculoaortic continuity caused by complicated aortic root

Table 2. Independent predictors of operative mortality in periannular extension of IE

Study	Independent predictors of operative mortality
Anguera et al. (2005)[4]	Moderate or severe heart failure (OR 3.4, CI 95% 1.0–11.5) Prosthetic valve endocarditis (OR 4.6, CI 95% 1.4–15.4) Urgent or emergency operations (OR 4.3, CI 95% 1.3–16.6)
David et al. (2007)[21]	Preoperative cardiogenic and/or septic shock (P = 0.03) Abscess in both aortic and mitral annuluses (P = 0.08)

OR, odds ratio; CI, confidence interval.

infection, with no patch material to decrease possible risk of the recurrence of infection. All but one patient did well with no evidence of paravalvular leakage or recurrent infections over a 22-month follow-up period.[36]

2. Periannular extension of mitral valve IE

Annular and periannular abscesses are less frequently observed in mitral valve endocarditis (14%) than they are in aortic valve endocarditis (52%).[37] Annular abscesses most often occur in the posteroinferior portion, intervalvular fibrous body, or both areas of the mitral valve complex. The resection of these abscesses is usually required to eradicate the infection, and such interventions are associated with high operative mortality.[21] A well-defined, small abscess can be drained and debrided, and the remaining defect repaired with a pericardial patch. When discontinuity is present between the left ventricle and the left atrium, a modified technique for valve replacement can be used. This consists of interrupted horizontal mattress sutures with pledgets placed on the left ventricle side of the mitral annulus, carried up through the left atrium side of the debrided annulus, and then pulled through the sewing ring of the prosthetic valve. However, the distance between the edge of the left ventricle and the left atrium after debridement and the fragility of the infected tissue pose a failure risk for such a technique either during the operation or in the postoperative period.[22]

To avoid excessive tension on a weakened ventricular or atrial structure, a good alternative is to reconstruct the annulus with the pericardium. Fresh autologous pericardium is the best material for reconstructing the areas of the mitral and tricuspid annuli that are subtended by the cardiac muscle. Glutaraldehyde-fixed pericardium or Dacron fabric are more appropriate for patching areas of the intervalvular fibrous body and large segments of the noncoronary aortic sinus and aortic annulus.[21] A prosthetic valve is then placed with pledgetted sutures in the upper portion (atrial side) of the pericardial patch, known as the intra-atrial implantation of a mitral prosthesis.[22,38] Furthermore, biological glue can be used as a good adjunct to such a reconstructive procedure, which greatly reduces the risk of postoperative atrium-ventricle discontinuity.[22] Besides utilizing pericardial tissue for annular reconstruction, Turkoz et al.[39] also reported 2 cases of posterior annular abscess. These patients underwent mitral valve replacement after the application of a flap of evaginated left atrial appendix to cover the atrium and annulus defects.[39]

Outcome and Prognostic Factors

In a recent series of 76 patients with aorto-cavitary fistulization,[4] the overall mortality rate was 41%, despite surgical intervention in 87% of them. The causes of death in these surgically treated patients were multiorgan failure, septic or cardiogenic shock and postoperative hemorrhage.[4] Multivariable analyses identified moderate or severe heart failure, prosthetic valve endocarditis, and emergency operations to be independently associated with an increased risk of in-hospital death. A prolonged interval between the diagnosis of IE and the diagnosis of periannular extension was not statistically associated with increased in-hospital mortality, although the absolute difference of 17% may be considered clinically important.[4] David et al. also identified preoperative cardiogenic and/or septic shock and abscess in both the aortic and mitral annuli to be independent predictors of operative mortality (15.5%)[21] (Table 2).

Graupner et al.[3] found that aortic infection, prosthetic endocarditis, new AV block, and coagulase-negative *staphylococci* were independent risk factors of periannular complications. The period between symptom onset and diagnosis, the incidence of pericardial effusion, and the persistent signs of infection were similar between patients with and without periannular complications. In patients with these complications, there were no differences in the presence or size of vegetations or the frequency of embolisms.

Summary

The periannular extension of infection is one of the most dangerous complications in patients with IE. It is well recognized that this particular condition has a significant impact on the prognosis of these patients. The accurate detection and delineation of periannular complications are crucial in patient management and may provide guidance for surgical intervention. Echocardiography, particularly TEE, is the preferred imaging examination in both native and prosthetic valvular infections. Although *staphylococci* are reported to be the most common cause of aorto-cavitary fistulae, the association between this pathogen and clinical characteristics and patient outcome remains to be proven. Conversely, it has been repeatedly observed that *S. aureus* is the most common cause of aorto-cavitary fistulae in patients with native valve endocarditis. Although in the so-called post-antibiotic era it still remains a great challenge to successfully treat simple infections from panresistant organisms,[14] the optimal management of patients with periannular extension of IE requires a multidisciplinary approach, with surgical input being an integral part of the treatment associated with the evolution of complex reconstructive techniques.

References

1. Lester SJ, Wilansky S. Endocarditis and associated complications. *Crit Care Med* 2007; **35** (8 Suppl): S384–91.
2. Bayer AS, Bolger AF, Taubert KA, Wilson W, Steckelberg J, et al. Diagnosis and management of infective endocarditis and its complications. *Circulation* 1998; **98**: 2936–48.
3. Graupner C, Vilacosta I, San Román J, Ronderos R, Sarriá C, et al. Periannular extension of infective endocarditis. *J Am Coll Cardiol* 2002; **39**: 1204–11.
4. Anguera I, Miro JM, Vilacosta I, Almirante B, Anguita M, et al. Aorto-cavitary fistulous tract formation in infective endocarditis: clinical and echocardiographic features of 76 cases and risk factors for mortality. *Eur Heart J* 2005; **26**: 288–97.
5. Baddour LM, Wilson WR, Bayer AS, Fowler VG Jr, Bolger AF, et al. Infective endocarditis: diagnosis, antimicrobial therapy, and management of complications: a statement for healthcare professionals from the Committee on Rheumatic Fever, Endocarditis, and Kawasaki Disease, Council on Cardiovascular Disease in the Young, and the Councils on Clinical Cardiology, Stroke, and Cardiovascular Surgery and Anesthesia, American Heart Association: endorsed by the Infectious Diseases Society of America. *Circulation* 2005; **111**: e394–434.
6. Anguera I, Miro JM, Evangelista A, Cabell CH, San Roman JA, et al. Periannular complications in infective endocarditis involving native aortic valves. *Am J Cardiol* 2006; **98**: 1254–60.
7. Kasper KJ, Chandrasekaran K, Bowman R, Karalis DG, Young NA, et al. Left ventricular outflow tract to left atrial communication due to mitral valve endocarditis. *Am Heart J* 1993; **125**: 1792–7.
8. Parashara DK, Jacobs LE, Kotler MN, Yazdanfar S, Spielman SR, et al. Angina caused by systolic compression of the left coronary artery as a result of pseudoaneurysm of the mitral-aortic intervalvular fibrosa. *Am Heart J* 1995; **129**: 417–21.
9. Anguera I, Miro JM, San Roman JA, de Alarcon A, Anguita M, et al. Periannular complications in infective endocarditis involving prosthetic aortic valves. *Am J Cardiol* 2006; **98**: 1261–8.
10. Blumberg EA, Karalis DA, Chandrasekaran K, Wahl JM, Vilaro J, et al. Endocarditis-associated paravalvular abscess. Do clinical parameters predict the presence of abscess? *Chest* 1995; **107**: 898–903.
11. Daniel WG, Mügge A, Martin RP, Lindert O, Hausmann D, et al. Improvement in the diagnosis of abscesses associated with endocarditis by transesophageal echocardiography. *N Engl J Med* 1991; **324**: 795–800.
12. Karalis DG, Bansal RC, Hauck AJ, Ross JJ Jr, Applegate PM, et al. Transesophageal echocardiographic recognition of subaortic complications in aortic valve endocarditis. Clinical and surgical implications. *Circulation* 1992; **86**: 353–62.
13. Omari B, Shapiro S, Ginzton L, Robertson JM, Ward J, et al. Predictive risk factors for periannular extension of native valve endocarditis. Clinical and echocardiographic analyses. *Chest* 1989; **96**: 1273–9.
14. Paterick TE, Paterick TJ, Nishimura RA. Steckelberg JM. Complexity and subtlety of infective endocarditis. *Mayo Clin Proc* 2007; **82**: 615–21.
15. Millar BC, Moore JE. Emerging issues in infective endocarditis. *Emerg Infect Dis* 2004; **10**: 1110–6.
16. Fowler VG Jr, Miro JM, Hoen B, Cabell CH, Abrutyn E, et al. *Staphylococcus aureus* endocarditis: a consequence of medical progress. *JAMA* 2005; **293**: 3012–21.
17. Ferguson E, Reardon MJ, Letsou GV. The surgical management of bacterial valvular endocarditis. *Curr Opin Cardiol* 2000; **15**: 82–5.
18. Chamoun AJ, Conti V, Lenihan DJ. Native valve infective endocarditis: what is the optimal timing for surgery? *Am J Med Sci* 2000, **320**: 255–62.
19. Croft CH, Woodward W, Elliott A, Commerford PJ, Barnard CN, et al. Analysis of surgical versus medical therapy in active complicated native valve endocarditis. *Am J Cardiol* 1983; **51**: 1650–5.
20. Vlessis AA, Hovaguimian H, Jaggers J, Ahmad A, Starr A. Infective endocarditis: ten-year review of medical and surgical therapy. *Ann Thorac Surg* 1996; **61**: 1217–22.
21. David TE, Regesta T, Gavra G, Armstrong S, Maganti

MD. Surgical treatment of paravalvular abscess: long-term results. *Eur J Cardiothoracic Surg* 2007; **31**: 43–8.
22. Mesana TG, Jahangiri B. Surgical management: indications and technical issues. In: Chan KL, Embil JM, eds. Endocarditis: Diagnosis and Management. London: Springer-Verlag, 2006; pp 105–19.
23. Donaldson RM, Ross DM. Homograft aortic root replacement for complicated prosthetic valve endocarditis. *Circulation* 1984; **70** (3 Pt 2): I178–81.
24. Yankah AC, Pasic M, Klose H, Siniawski H, Weng Y, et al. Homograft reconstruction of the aortic root for endocarditis with periannular abscess: a 17-year study. *Eur J Cardiothoracic Surg* 2005; **28**: 69–75.
25. Haydock D, Barratt-Boyes B, Macedo T, Kirklin JW, Blackstone E. Aortic valve replacement for active infectious endocarditis in 108 patients. A comparison of freehand allograft valves with mechanical prostheses and bioprostheses. *J Thorac Cardiovasc Surg* 1992; **103**: 130–9.
26. d'Udekem Y, David TE, Feindel CM, Armstrong S, Sun Z. Long-term results of operation for paravalvular abscess. *Ann Thorac Surg* 1996; **62**: 48–53.
27. Sabik JF, Lytle BW, Blackstone EH, Marullo AG, Pettersson GB, et al. Aortic root replacement with cryoprserved allograft for prosthetic valve endocarditis. *Ann Thorac Surg* 2002; **74**: 650–9.
28. Siniawski H, Lehmkuhl H, Weng Y, Marullo AG, Pettersson GB, et al. Stentless aortic valves as an alternative to homografts for valve replacement in active infective endocarditis complicated by ring abscess. *Ann Thorac Surg* 2003; **75**: 803–8.
29. Siniawski H, Grauhan O, Hofmann M, Pasic M, Yankah C, et al. Aortic root abscess and secondary infective mitral valve disease: results of surgical endocarditis treatment. *Eur J Cardiothoracic Surg* 2005; **27**: 434–40.
30. Schmidtke C, Dahmen G, Sievers HH. Subcoronary Ross procedure in patients with active endocarditis. *Ann Thorac Surg* 2007; **83**: 36–9.
31. Nottin R, Al-Attar N, Ramadan R, Azmoun A, Therasse A, et al. Aortic valve translocation for severe prosthetic valve endocarditis: early results and long-term follow-up. *Ann Thorac Surg* 2005; **79**: 1486–90.
32. Müller LC, Chevtchik O, Bonatti JO, Müller S, Fille M, et al. Treatment of destructive aortic valve endocarditis with the Freestyle Aortic Root Bioprosthesis. *Ann Thorac Surg* 2003; **75**: 453–6.
33. Bozbuga N, Erentug V, Erdogan HB, Kirali K, Ardal H, et al. Surgical treatment of aortic abscess and fistula. *Tex Heart Inst J* 2004; **31**: 382–6.
34. Kon ND, Riley RD, Adair SM, Kitzman DW, Cordell AR. Eight-year results of aortic root replacement with the freestyle stentless porcine aortic root bioprosthesis. *Ann Thorac Surg* 2002; **73**: 1817–21.
35. Avierinos JF, Thuny F, Chalvignac V, Giorgi R, Tafanelli L, et al. Surgical treatment of active aortic endocarditis: homografts are not the cornerstone of outcome. *Ann Thorac Surg* 2007; **84**: 1935–42.
36. Sung K, Lee YT, Park PW, Park KH, Jun TG, et al. Minimizing foreign material in the reconstruction of infected complex annuloaortic disruption. *Ann Thorac Surg* 2004; **78**: 2191–2.
37. Baumgartner FJ, Omari BO, Robertson JM, Nelson RJ, Pandya A, et al. Annular abscesses in surgical endocarditis: anatomic, clinical, and operative features. *Ann Thorac Surg* 2000; **70**: 442–7.
38. Nataf P, Jault F, Dorent R, Vaissier E, Bors V, et al. Extra-annular procedures in the surgical management of prosthetic valve endocarditis. *Eur Heart J* 1995; **16** (Suppl B): 99–102.
39. Turkoz R, Gulcan O, Uguz E, Cihan HB. Mitral valve replacement after application of atrial appendix flap in endocarditis with posterior annular abscess. *Eur J Cardiothoracic Surg* 2004; **26**: 837–8.