Case Report

Surgical Resection and Reconstruction for Primary Malignant Sternal Tumor

Shinji Hirai, MD,[1] Hiroaki Nobuto, MD,[2] Kazunori Yokota, MD,[3] Yosuke Matsuura, MD,[1]
Shinnosuke Uegami, MD,[1] Katsutoshi Sato, MD,[1] Norimasa Mitsui, MD,[1]
Takashi Sugita, MD,[2] and Yoshiharu Hamanaka, MD[1]

We report a very rare and successful surgery for primary malignant tumor of the sternum. A 73-year-old male, previously healthy, was admitted to our hospital because a chest computed tomography scan detected an abnormal shadow that suggested a sternal tumor destroying part of the sternum body. Aspiration needle biopsy demonstrated a primary sternal chondrosarcoma measuring 3 × 4 cm in diameter. The sternum below the second intercostal space was resected along with a 1-cm width of cartilage below the third rib on each side. Sternal reconstruction was performed with Composix mesh™, titanium mesh, and Marlex mesh, using a right pectoralis major muscle flap translation. The patient was extubated just after surgery, and the postoperative course was uneventful. This procedure may be useful for repairing the detect after wide sternotomy. (Ann Thorac Cardiovasc Surg 2009; 15: 182–185)

Key words: primary sternal tumor, chondrosarcoma, sternal reconstruction

Introduction

A primary malignant sternal tumor is very rare and has long been considered a challenging problem. The development of surgical techniques for sternal reconstruction has expanded the role of surgery, and radical resection is thought to offer a definitive cure. However, the optimal surgical procedure remains controversial.[1)] We report a successful surgery for primary sternal chondrosarcoma that was treated by subtotal sternectomy, then reconstructed with Composix mesh™ (C. R. Bard, Inc., NJ, USA), titanium mesh (Mondeal Medical Systems GmbH, Germany), and Marlex mesh (C. R. Bard, Inc., NJ, USA), using a right pectoralis major (PM) muscle flap.

From Departments of [1]Thoracic and Cardiovascular Surgery and [2]Orthopedic Surgery, Hiroshima Prefectural Hospital; and [3]Department of Orthopedic Surgery, Hiroshima University Hospital, Hiroshima, Japan

Received November 12, 2007; accepted for publication April 7, 2008
Address reprint requests to Shinji Hirai, MD: Department of Thoracic and Cardiovascular Surgery, Hiroshima Prefectural Hospital, 1–5–54 Ujinakanda, Minami-ku, Hiroshima 734–8530, Japan.

Case Report

A 73-year-old male, previously healthy, was admitted to our hospital because a chest computed tomography (CT) scan detected an abnormal shadow that suggested a sternal tumor destroying part of the sternum body, and magnetic resonance imaging (MRI) showed a hypotonic mass on T1-weighted images (Fig. 1). Aspiration needle biopsy demonstrated a primary sternal chondrosarcoma measuring 3 × 4 cm in diameter. Laboratory data revealed no abnormalities, and a subtotal sternotomy was performed. A midline skin incision was made. The line of resection was 2 cm beyond the margin of the tumor. The sternum below the second intercostal space was resected with a 1-cm width of cartilage below the third rib on each side. Both internal thoracic vessels were ligated at the second rib space. There was no invasion of the surrounding tissue, enabling us to remove the tumor

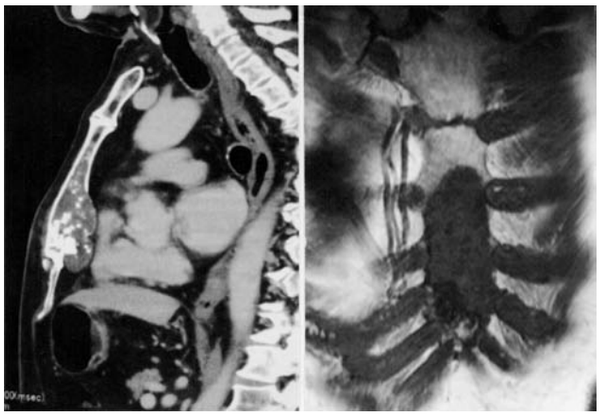

A | B

Fig. 1.
A: A computed tomography (CT) scan showed a sternal tumor destroying part of the sternum body.
B: A magnetic resonance imaging (MRI) showed a hypotonic mass on T1-weighted images.

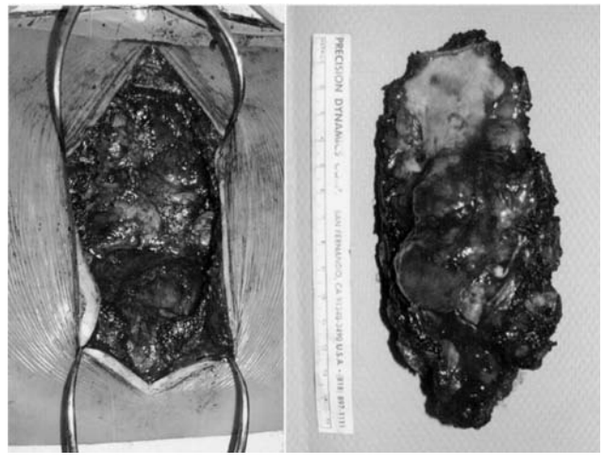

Fig. 2. The sternum below the second intercostal space was resected with a 1-cm width of cartilage below the third rib on each side, and the defect measured approximately 7 × 15 cm.

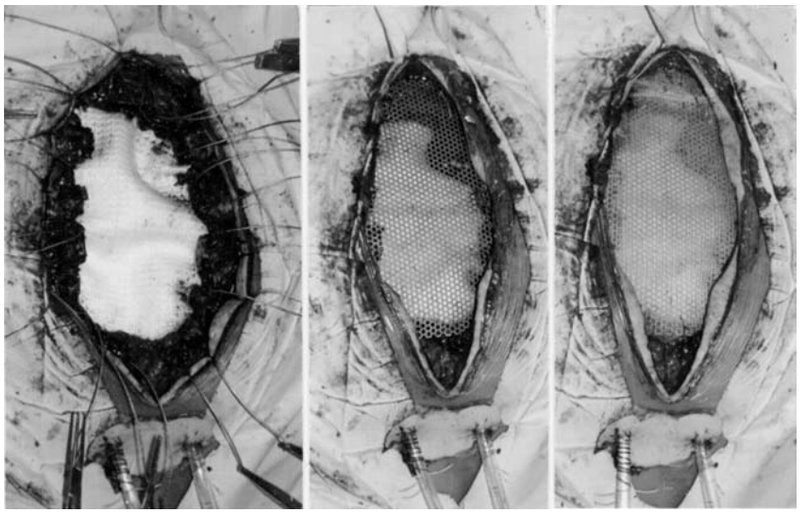

A | B | C

Fig. 3.
A: A Composix mesh™ was fixed with 1-0 vicryl to the inferior walls of the ribs and sternum and achieved a seal of the anterior mediastinal space of the defect.
B: A titanium mesh, which was adjusted to the defect in size, was fixed with titanium wire to the superior walls of the ribs and sternum.
C: A sheet of Marlex mesh was folded back 1 cm on the titanium mesh and fixed there with 3-0 vicryl.

en bloc. The defect measured approximately 7 × 15 cm (Fig. 2). Sternal reconstruction was performed with Composix mesh™, titanium mesh (original size 20 × 10.5 cm, 0.6 mm thick), and Marlex mesh, using a right PM muscle flap translocation. A Composix mesh™ was fixed with 1-0 vicryl to the intercostal muscle of the resected ribs, then attached to the inferior walls of the ribs and sternum, achieving a seal of the anterior mediastinal space of the defect (Fig. 3A). Titanium mesh, which was adjusted to the defect in size, was fixed with titanium wire to the superior walls of the ribs and sternum (Fig. 3B). A sheet of Marlex mesh was folded back 1 cm on the titanium mesh and fixed there with 3-0 vicryl (Fig. 3C). After these procedures, the region of the sternal defect was covered with a right-sided PM muscle flap translocation (Fig. 4). The patient was extubated just after surgery, and the postoperative course was uneventful with no symptoms, such as flail chest or regional effusion. A chest X-ray and chest CT 6 months after surgery showed that the titanium mesh was intact (Fig. 5).

Discussion

Primary malignant tumors of the sternum are very rare

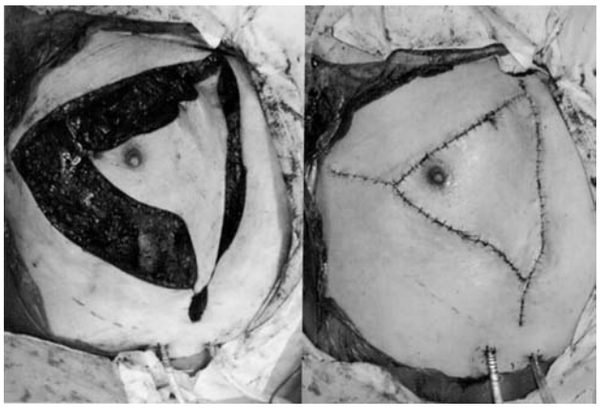

Fig. 4. After the above procedures, the region of the sternal defect was covered with a right-sided pectoralis major (PM) muscle flap translocation.

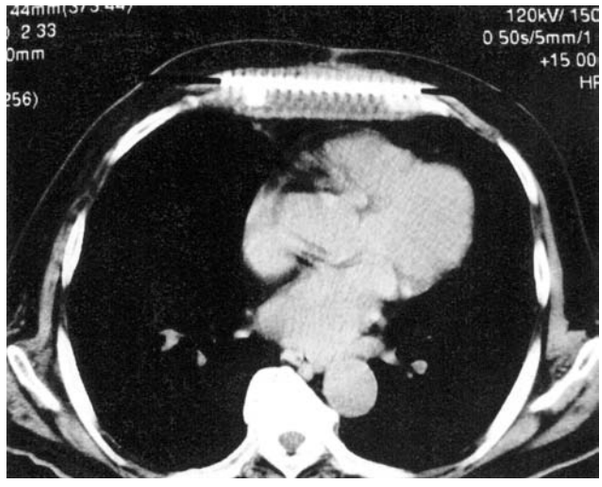

Fig. 5. A chest computed tomography (CT) 6 months after surgery reveals that the site of the sternal defect showed smooth wound healing.

and most of them are sarcomas, including several histological types. In primary tumors, radical resection may provide a permanent eradication of the disease and a good prospect for long-term survival. Most authors recommend that the incision be placed 2 to 4 cm from the margin of the tumor to minimize the risk of local recurrence.[2–4]

Reconstruction of the defect is important to promote good pulmonary function, protect endothoracic organs from infection and trauma, and maintain cosmetic integrity.[5] However, reconstruction after a wide sternotomy remains controversial. Prosthetic materials for reconstruction must achieve the objective function without inducing foreign body response, provide for smooth wound healing, and resist infection.[5] However, the choices of prosthetic material can be confusing. Therefore various types of this material and techniques have been used in the past, depending on the size and site of the defect and the surgeon's preference: Marlex mesh, Composix mesh™, prolene mesh, vicryl nets, polytetrafluoroethylene (PTFE) patch, methylmethacrylate, stainless steel mesh, resin plate, or metal plate.[1,4–15] We also thought that chest wall stability, protection of endothoracic organs, and lung expansion after a wide sternotomy to minimize the risk of local recurrence can be best attained by a rigid prosthetic replacement. However, because a rigid prosthetic replacement might be rejected or cause septic complications, the combination of rigid prosthetic material and soft tissue coverage and muscular or musculotaneous flaps is advantageous.

Therefore we recommend a rigid prosthetic replacement constructed with titanium mesh spread between Marlex mesh and Composix mesh™, using the right PM muscle flap, to limit flail chest after a wide sternotomy. We achieved a seal of the anterior mediastinal space of the defect using Composix mesh™. This material is composed of two layers of Marlex mesh with a thin heat-sealed layer of expanded PTFE (ePTFE) and thus achieves the twin benefits of reduced mechanical stress and minimal adhesion to intrathoracic organs, providing more elasticity, easier handling, and greater stability than conventional polypropylene nets. On the Composix mesh™, we fixed a titanium mesh covered with Marlex mesh. These meshes are widely used materials as a rigid prosthetic replacement because of their resistance, manageability, durability, and absence of foreign body reactions and septic complications. Recently, Briccoli et al.[16] used Marlex mesh and titanium plates to prevent paradoxical movement of the thoracic wall after sternotomy for high-grade tumors. We preferred titanium mesh to titanium plates because it compensates for the limited resiliency of Marlex mesh, remains rigid in all directions, and allows good intrathoracic organ protection in all areas of defect. Futhermore, although Haraguchi et al.[12] used the sandwiched Marlex mesh and stainless steel mesh, we prefer titanium mesh to stainless steel mesh because it will not disrupt future CT or MRI examinations. Single or bilateral PM muscle and myocutaneous flaps were frequently used to reconstruct defects of the upper sternum or chest wall.[7] These flaps have been reported to provide excellent blood supply and to show good performance in potentially infected areas. Further-

more, the complication rates are less than those for other flaps used in thoracic reconstruction.[6)]

Although our surgical procedure is somewhat complex and the cost of titanium mesh is not covered by medical insurance, our experience suggests that this procedure provides chest wall stability, protection of endothoracic organs, and good pulmonary function, making it an appropriate technique for repairing the defect after wide sternotomy. The use of this method is expected to increase survival and decrease complications.

Conclusion

We report a successful surgery for primary sternal chondrosarcoma that was treated by a subtotal sternotomy and reconstructed with titanium mesh, Marlex mesh, and Composix mesh™ using a right PM muscle flap.

This procedure may be useful for repairing the defect after a wide sternotomy.

References

1. Chapelier AR, Missana MC, Couturaud B, Fadel E, Fabre D, et al. Sternal resection and reconstruction for primaly malignant tumors. *Ann Thorac Surg* 2004; **77**: 1001–7.
2. King RM, Pairolero PC, Trastek VF, Piehler JM, Payne WS, et al. Primary chest wall tumors: factors affecting survival. *Ann Thorac Surg* 1986; **41**: 597–601.
3. Martini N, Huvos AG, Burt ME, Heelan RT, Bains MS, et al. Predictors of survival in malignant tumors of the sternum. *J Thorac Cardiovasc Surg* 1996; **111**: 96–106.
4. Incarbone M, Nava M, Lequaglie C, Ravasi G, Pastorino U. Sternal resection for primary or secondary tumors. *J Thorac Cardiovasc Surg* 1997; **114**: 93–9.
5. Tunçözgür B, Elbeyli L, Güngör A, Işık F, Akay H. Chest wall reconstruction with autologas rib grafts in dogs and report of a clinic case. *Eur J Cardiothorac Surg* 1999; **16**: 292–5.
6. Mansour KA, Anderson TM, Hester TR. Sternal resection and reconstruction. *Ann Thorac Surg* 1993; **55**: 838–43.
7. Soysal O, Walsh GL, Nesbitt JC, McMurtrey MJ, Roth JA, et al. Resection of sternal tumors: extent, reconstruction, and survival. *Ann Thorac Surg* 1995; **60**: 1353–9.
8. Nakasone T, Kimino K, Yamashita H, Kishikawa M. A case of skeletal reconstruction for a primary sternal chondrosarcoma. *Kyobu Geka* 1998; **51**: 193–8. (in Jpse.)
9. Shimada K, Handa M, Kondo T, Sato N, Yoshida H, et al. A resected case of mediastinal liposarcoma with reconstruction of chest wall. *Nihon Kokyuki Geka Gakkai Zasshi* 2000; **14**: 39–43. (in Jpse.)
10. Ozawa K, Yamazaki K, Sugimoto H, Kajiura Y, Sato K, et al. Three cases of full thickness chest wall resection and reconstruction for a solitary sternal metastasis of breast carcinoma. *Nihon Kokyuki Geka Gakkai Zasshi* 2001; **15**: 476–9. (in Jpse.)
11. Osawa H, Sato T, Tanaka A, Tanaka T, Maekawa K. Concomitant operation for lung cancer and metastatic sternal tumor: a case report. *Nihon Kokyuki Geka Gakkai Zasshi* 2001; **15**: 752–7. (in Jpse.)
12. Haraguchi S, Yamashita Y, Yamashita K, Hioki M, Matsumoto K, et al. Sternal resection for metastasis from thyroid carcinoma and reconstruction with the sandwiched Marlex and stainless steel mesh. *Jpn J Thorac Cardiovasc Surg* 2004; **52**: 209–12.
13. Pyle JW, Ash JL, Husssain SM, Reid N, Anderson RC. Sternal resection and reconstruction after renal cell carcinoma metastatic to the sternum. *J Thorac Cardiovasc Surg* 2005; **129**: 1177–8.
14. Imai K, Minamiya Y, Saito H, Kawai H, Ito M, et al. Giant cell tumor of the sternum. *Jpn J Thorac Cardiovasc Surg* 2006; **54**: 405–8.
15. Yoshida K, Kobayashi N, Kurai M, Hyogotani A, Kondo R, et al. A subtotal sternectomy successfully reconstructed with Composix mesh™. *Ann Thorac Cardiovasc Surg* 2006; **12**: 420–4.
16. Briccoli A, Manfrini M, Rocca M, Lari S, Giacomini S, et al. Sternal reconstruction with synthetic mesh and metallic plates for high grade tumours of the chest wall. *Eur J Surg* 2002; **168**: 494–9.