

Closure of Pneumonectomy Stump Fistula Using Custom Y and Cuff-Link-Shaped Silicone Prostheses

Henri G. Colt, MD, and Septimiu D. Murgu, MD

Large postpneumonectomy stump fistulas pose a significant problem for thoracic surgeons and interventional bronchoscopists. We present a case of successful rigid bronchoscopic repair of a complete right pneumonectomy stump dehiscence using a custom-built stent made of a sculpted silicone Y stent sutured to a new cuff-link-shaped DJ-Fistula stent. This resulted in rapid symptom resolution, weaning from mechanical ventilation and discharge home in a patient with bronchogenic carcinoma, respiratory failure, and significant other comorbidities that precluded repeat thoracotomy. (Ann Thorac Cardiovasc Surg 2009; 15: 339–342)

Key words: pneumonectomy stump, fistula, silicone stent

Introduction

Bronchial stump fistula is challenging and difficult in the treatment of complications of lung resection.^{1,2)} In patients who are not surgical candidates, operators have used adhesives, metallic coils, stents, endobronchial valves or spigots, and other bronchoscopic modalities³⁾ to occlude the fistula and prevent empyema, respiratory insufficiency, and death. We describe a way in which two different types of silicone stents, sewn together to create a single Y-stent with an occluded bronchial stump limb, can be used to satisfactorily close a large fistulous track, remove a patient from mechanical ventilation, and provide long-term relief from symptoms.

Case Report

A 79-year-old male with multiple comorbidities, including severe chronic obstructive lung disease, systemic

hypertension, coronary artery disease, abdominal aortic aneurysm, carotid artery stenosis, and thyroid carcinoma, was referred to our institution with a large right pneumonectomy stump fistula. He had been diagnosed with squamous cell carcinoma six months earlier at another institution. Following initial right upper lobectomy and radical dissection of mediastinal nodes, positive surgical margins prompted completion pneumonectomy several days later. Postoperative hemorrhage required repeat thoracotomy within 48 hours after completion pneumonectomy. The postoperative course was complicated by prolonged mechanical ventilation for respiratory failure, pulmonary embolism, deep venous thrombosis warranting anticoagulation, and placement of inferior vena cava filter. A tracheotomy was performed on postop day 7. Three weeks after surgery, flexible bronchoscopy revealed a pneumonectomy stump fistula. A chest tube was placed into the right hemithorax with negligible return of fluid, but with the presence of a massive air leak. Sputum cultures were positive for *Pseudomonas aruginosa*, and the patient was started on intravenous imipenem and amikacin. The patient was considered inoperable and was referred to our institution for possible bronchoscopic repair of his pneumonectomy stump fistula nine days later. Rigid bronchoscopy revealed complete dehiscence at the stump site (Fig. 1A). A 12-mm EFER-Dumon ventilating rigid bronchoscope could be easily moved through

From University of California, Irvine, Orange, USA

Received May 12, 2008; accepted for publication September 8, 2008

Address reprint requests to Henri G. Colt, MD: Pulmonary and Critical Care Division, UCI Medical Center, 101 the City Drive, Bldg. 53, Rm. 119, Orange, California 91916, USA.

©2009 The Editorial Committee of *Annals of Thoracic and Cardiovascular Surgery*. All rights reserved.

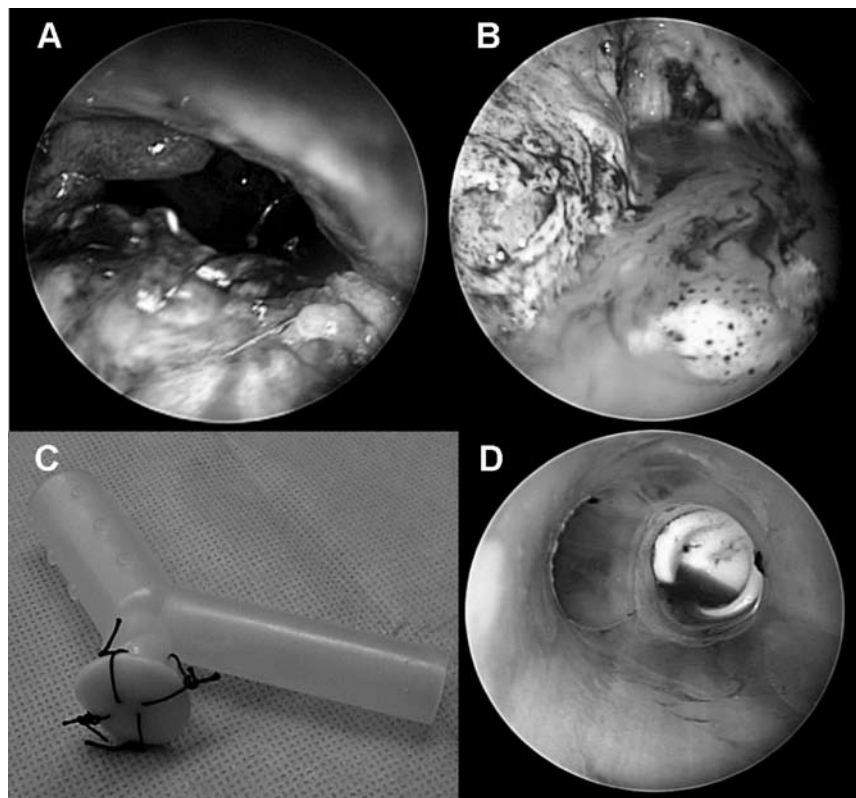


Fig. 1. **A:** Rigid bronchoscopic view of the complete right postpneumonectomy stump dehiscence.
B: Right thoracic cavity with fluid seen through the right bronchial stump.
C: This is a combined studded Y-shaped and DJ Fistula silicone stent.
D: The combined stent inside the airway completely covering the fistula.

the fistulous track into the right hemithorax (Fig. 1B). All fluid was removed by aspiration. The stump itself was inflamed and necrotic, and the fistula was 12 mm in diameter.

A custom-sculpted studded silicone Y stent (Bryan Corp., Woburn, MA) and a new cuff-link-shaped silicone prosthesis (DJ-Fistula™, Bryan Corp., Woburn, MA) were used to close the fistula. The Y stent was large, 16 mm wide (tracheal limb) by 13 mm wide (bronchial limbs). The stent was trimmed so that the tracheal limb was 3 cm long, the right bronchial limb 1 cm long, and the left bronchial limb 3 cm long. The left bronchial limb was trimmed at an angle to slightly bypass the initial horizontal portion of the left main bronchus. The right bronchial limb was trimmed so that its distal extremity would barely enter the right hemithorax.

A large cuff-link-shaped silicone prosthesis, originally designed to be used to occlude tracheobronchial-esophageal fistulas, was then sewn onto the right bronchial limb of the Y stent (Fig. 1C). The cuff-link-shaped prosthesis (DJ-Fistula™, Bryan Corp., Woburn, MA) is made of three portions: a 20-mm mushroom-shaped top, a 4-mm central limb, and a 10-mm elliptical-shaped distal aspect. The smaller distal limb was pushed into the distal lumen

of the right bronchial limb of the Y stent, after which four silk sutures were placed to tie the larger mushroom-shaped aspect to the Y stent, securing the cuff-link-shaped prosthesis to the distal extremity of the right bronchial limb of the Y stent. The rigid bronchoscope, which had been inserted through the patient's tracheostomy, was removed, and by using rigid forceps, we inserted the stent through the open tracheostomy and positioned it onto the carina so that the left bronchial limb could be guided down into the left main bronchus, and the right bronchial limb could be guided into the open right pneumonectomy stump. The rigid bronchoscope was reinserted into the airways, and rigid forceps were used to gently push the right bronchial limb cuff-link-shaped stent into position within the stump, completely occluding the fistulous track (Fig. 1D). Surgicel was then applied distally onto the stump surface lateral to the stent, and fibrin glue was deposited onto the surgicel to prevent micro leaks. A diagram of the stents and their positioning in the airway is illustrated in Fig. 2A. The patient was then extubated, and a #8 Shiley tracheotomy tube was inserted. The distal aspect of the tube was positioned so that it was 2 cm above the proximal aspect of the tracheal limb of the Y stent. The patient

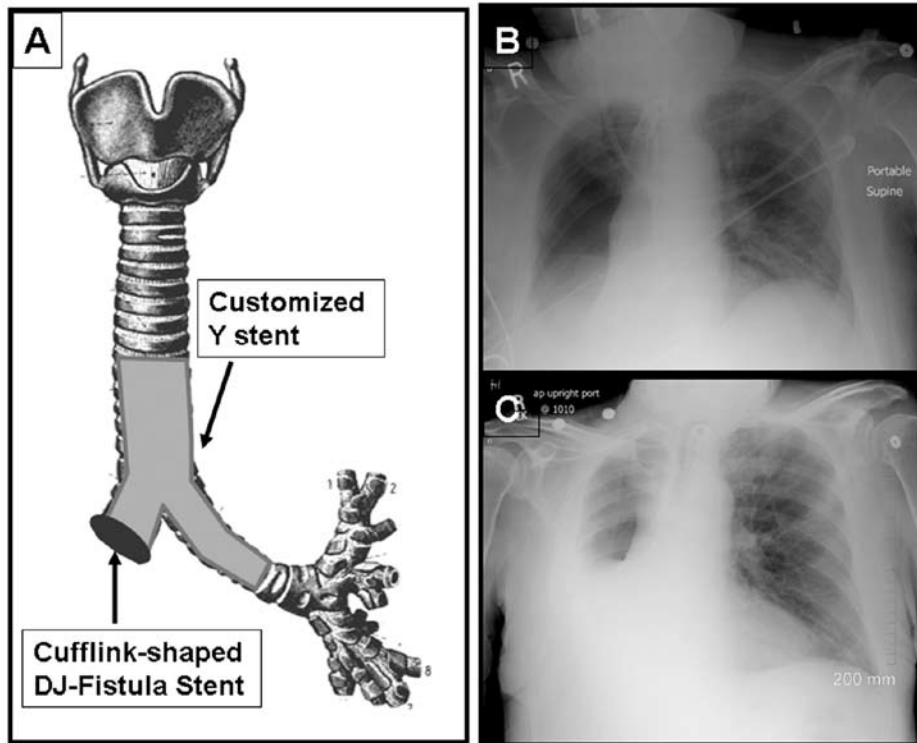


Fig. 2. A: A diagram showing stents positioning in the airway. The cuff-link-shaped DJ fistula stent is attached to the distal extremity of the right bronchial limb of the customized Y stent. B: Chest radiograph obtained at the time of rigid bronchoscopy showing the right hydropneumothorax with fluid level present in the infrahilar region. C: Chest radiograph obtained 3 months postintervention shows an increase in the fluid level now seen at the level of pulmonary hilum.

was then connected to the ventilator and moved to the medical intensive care unit.

Immediately, the patient's large airleak postoperatively ceased. Broad spectrum antibiotics were continued, and the patient was transferred back to the referring hospital in satisfactory condition, with instructions to perform serial flexible bronchoscopy to remove airway secretions, if any were present. Follow-up bronchoscopies revealed minimal secretions and a clean stent. The patient's airleak was completely resolved, and the large bore chest tube was removed one week later. The patient was weaned from mechanical ventilation and a Passy-Muir speaking valve was placed on the tracheostomy tube. The patient was discharged 4 weeks after stent insertion. A chest radiograph obtained three months after the procedure showed improvement in the right-sided hydropneumothorax (Figs. 2B and 2C). The tracheostomy tube was subsequently removed, and one year later the patient is at home and continues to do well.

Discussion

Patients with large, central stump fistulas who are not surgical candidates may benefit from airway stent placement.³ In this setting, a large stent must seal the stump

fistula as tight as possible to prevent aspiration pneumonia and empyema and to allow satisfactory single lung ventilation if the patient is requiring mechanical ventilation. Stent selection would depend on the size and location of the fistula, as well as on the physical properties of the stent and the operator's ability to manage potential stent-related complications.³

Y-shaped silicone stents usually have a short or long tracheal limb, a long 2–5-cm left main bronchial limb, and a shorter 1–3-cm right main bronchial limb. The Y stent, however, has patent distal bronchial limbs and thus cannot completely occlude a major postpneumonectomy stump dehiscence. For this purpose, modified versions of the Y stent have included occlusion of one of the bronchial limbs to occlude or cover the airway defect in patients who are not surgical candidates.^{4–6} Ferraroli et al. shortened the right limb of a studded Dumon Y stent and closed the right distal bronchial limb with silicone material cut from the stent itself.⁵ This resulted in successful occlusion of a 2-mm bronchial stump fistula. Another modified version of the Y stent consists of requesting the manufacturer to customize the stent at the time of manufacture by shortening the right bronchial limb and sealing its distal aspect. Such a stent was used successfully in a patient with a major right bronchial

stump fistula and respiratory failure.⁶⁾ Because such a customized stent must be ordered and manufactured, however, may limit wider applicability and also delay the time of therapeutic intervention.

Expandable metal stents seem to be an acceptable alternative to silicone stents for covering large bronchopleural fistulas. A large and long straight expandable metal stent, usually made of nitinol, such as the covered Ultraflex stent (Boston Scientific, Natick, MA) can be inserted so that the covered portion of the main body of the stent occludes the bronchial stump fistula, while the distal aspect of the stent extends down into the contralateral healthy bronchus and the proximal portion extends up into the trachea.⁷⁾ A partially covered nitinol stent has also been specifically designed for the treatment of bronchial stump fistula.⁸⁾ This stent has a bronchial limb with a bullet-shaped configuration that includes an occluded distal extremity and a main body that constitutes the tracheal limb. Expandable stents can be placed using fluoroscopic guidance and either rigid or flexible bronchoscopy. Uncovered metal stents can be used at the main carina level to actually promote granulation tissue formation, causing subsequent occlusion of a carinal fistulous tract (personal communication, Atul Mehta, 2007).

In this manuscript, we described how a commercially available, recently designed cuff-link-shaped silicone prosthesis known as the tracheoesophageal DJ-Fistula stent can be sutured onto the distal right bronchial limb of a studded Y-shaped stent to immediately occlude a large right pneumonectomy stump fistula. The DJ-Fistula stent, which is available in various sizes, was developed specifically to palliate small tracheoesophageal fistulas.⁹⁾ It consists of a top portion that seals the tracheal defect, a vertical axis that blocks the passage between the trachea and the esophagus, and a lower elliptical-shaped portion that anchors the stent in position in the esophageal lumen.

This combined studded Y-shaped and DJ-Fistula silicone stent can be inserted using a rigid bronchoscope and large forceps. In our case, the patient's tracheostomy allowed us to insert a stent that was large enough to completely occlude the large stump dehiscence. One concern, however, is that the silk sutures we used might not endure over the long term. A bronchoscopy performed at an out-of-state institution, however, showed these sutures to be intact 10 months after stent insertion. The potential durability of silk versus other products, such as nylon used for in-dwelling airway stents, warrants further study. Fibrin sealant was additionally administered to prevent micro leaks around the stent itself, while the patient's pleural

cavity was completely drained by first inserting the rigid bronchoscope into the pleural space at the time of rigid bronchoscopy, and subsequently by the conventional insertion of a large-bore thoracostomy tube.

To our knowledge, this is the first report of the use of such a stent to successfully close a large bronchial stump fistula in a critically ill patient who was not a surgical candidate. This approach can be used as a permanent solution for patients with poor life expectancy to improve their quality of life, or as a temporary bridge until a patient's clinical condition improves to allow repeat thoracotomy.

Acknowledgments

We thank Dr. Shahriyar Tavakoli, MD, and the nursing staff of Eisenhower Medical Center, Rancho Mirage, CA, for their assistance in caring for this patient.

References

1. Wright CD, Wain JC, Mathisen DJ, Grillo HC. Post-pneumonectomy bronchopleural fistula after sutured bronchial closure: incidence, risk factors, and management. *J Thorac Cardiovasc Surg* 1996; **112**: 1367–71.
2. Sirbu H, Busch T, Aleksic I, Schreiner W, Oster O, et al. Bronchopleural fistula in the surgery of non-small cell lung cancer: incidence, risk factors, and management. *Ann Thorac Cardiovasc Surg* 2001; **7**: 330–6.
3. Lois M, Noppen M. Bronchopleural fistulas: an overview of the problem with special focus on endoscopic management. *Chest* 2005; **128**: 3955–65.
4. Tayama K, Eriguchi N, Futamata Y, Harada H, Yoshida A, et al. Modified Dumon stent for the treatment of a bronchopleural fistula after pneumonectomy. *Ann Thorac Surg* 2003; **75**: 290–2.
5. Ferraroli GM, Testori A, Cioffi U, De Simone M, Alloisio M, et al. Healing of a bronchopleural fistula using a modified Dumon stent: a case report. *J Cardiothorac Surg* 2006; **1**: 16.
6. Tsukada H, Osada H. Use of a modified Dumon stent for postoperative bronchopleural fistula. *Ann Thorac Surg* 2005; **80**: 1928–30.
7. García Franco CE, Aldeyturriaga JF, Gaviria JZ. Ultraflex expandable metallic stent for the treatment of a bronchopleural fistula after pneumonectomy. *Ann Thorac Surg* 2005; **79**: 386.
8. Han X, Wu G, Li Y, Li M. A novel approach: treatment of a bronchial stump fistula with a plugged bullet-shaped angled stent. *Ann Thorac Surg* 2006; **81**: 1867–71.
9. Diaz-Jimenez P. New cufflink-shaped silicone prosthesis for the palliation of malignant tracheobronchial-esophageal fistula. *J Bronchol* 2005; **12**: 207–9.