

A Rare Case of Infective Endocarditis Complicated by *Trichosporon Asahii* Fungemia Treated by Surgery

Kenta Izumi, MD, Yoichi Hisata, MD, and Shiro Hazama, MD

The patient was a 58-year-old male. He consulted our hospital because of weight loss and fever. Computed tomography (CT) revealed renal infarction. Nine days after admission, CT showed hemorrhagic cerebral infarction in the right frontal lobe. A blood culture revealed *streptococcus oralis*, and echocardiography revealed vegetation in the mitral and aortic valves, suggesting infective endocarditis (IE). Fever (39°C or higher) was noted 23 days after admission. A blood culture revealed *Trichosporon asahii* (T. asahii), suggesting T. asahii fungemia. An intravenous drip of fluconazole at 400 mg/day was initiated, and two-valve replacement was performed 34 days after admission. Following surgery, the patient became negative for β -D glucan and was discharged 85 days after admission. We report the present case of IE complicated by T. asahii fungemia, which is rare in patients other than malignant blood disease or tumor patients, showing a poor prognosis in which survival was achieved by surgery. (*Ann Thorac Cardiovasc Surg* 2009; 15: 350–353)

Key words: *Trichosporon asahii*, infective endocarditis, fungemia, surgery, deep-seated trichosporonosis

Introduction

Deep-seated trichosporonosis is a type of fatal opportunistic infection that develops in immunocompromised hosts, such as patients with malignant blood tumors or neutropenia. This disorder is characterized by systemic dissemination, in some patients causing pneumonia, intraocular inflammation, multiple fungal liver abscesses, and skin abscesses.^{1,2)} The mortality rate ranges from 64% to 83%.³⁾ The prognosis of this type of deep mycosis is poorer than that of candidiasis, the same type of yeastlike fungal infection.

We encountered a patient with bacterial endocarditis,

complicated by *Trichosporon asahii* (T. asahii) fungemia, in whom cerebral and renal embolism was initially detected. Aortic and mitral valve replacement was performed, and an antifungal agent was administered. The result was the patient's achieving survival. Until now there has been no reported case of active infective endocarditis (IE) complicated by T. asahii fungemia and cured by surgical treatment. Therefore we report this rare case.

Case Report

The patient was a 58-year-old male. The height, body weight, blood pressure, pulse, respiratory rate, and body temperature were 166 cm, 45 kg, 124/70 mmHg, 78/min (regular), 14 times/min, and 38.3°C, respectively. On auscultation, Levine 3/6 systolic murmurs were heard, with a peak at the cardiac apex. The patient had been treated for hypertension and had undergone no surgery. He consulted our hospital because of weight loss, anorexia, and fever. Systemic computed tomography (CT) revealed renal infarction, suggesting acute bacterial nephritis. The white blood cell count (WBC) and C-reactive protein

From Division of Cardiovascular Surgery, Sasebo City General Hospital, Nagasaki, Japan

Received October 14, 2008; accepted for publication October 31, 2008

Address reprint requests to Kenta Izumi, MD: Division of Cardiovascular Surgery, Sasebo City General Hospital, 9-3 Hirase-cho, Sasebo, Nagasaki 857-8511, Japan.

©2009 The Editorial Committee of *Annals of Thoracic and Cardiovascular Surgery*. All rights reserved.

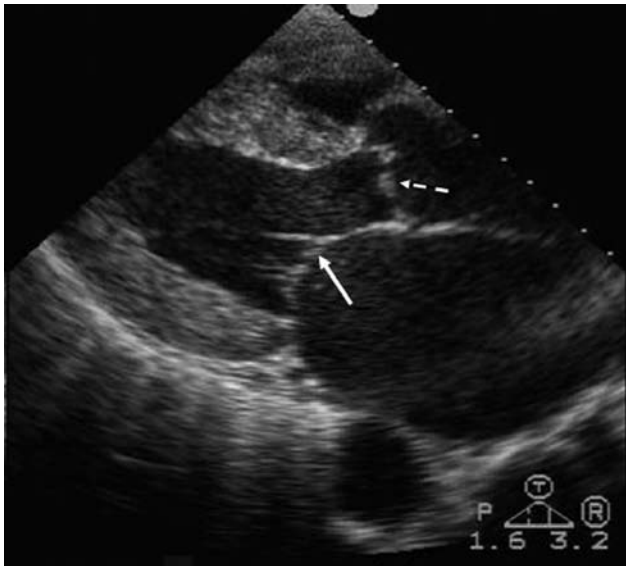


Fig. 1. Echocardiography.
Vegetations on mitral valve (arrow) and aortic valve (dotted arrow).

(CRP) level were increased to 9,800/l and 11.5 mg/dl, respectively. On blood culture the day after admission, *streptococcus* oralis was detected. Treatment with sulbactam sodium/ampicillin sodium (6 g \times 2/day) was initiated. The patient was negative for tumor markers. Imaging findings suggested no malignant tumors. Nine days after admission, the consciousness level was reduced, and cephalic CT revealed hemorrhagic cerebral infarction in the right frontal lobe. Echocardiography showed string-like mobile vegetation (15.0 \times 4.5 mm) in the mitral valve and vegetation in the aortic valve cusp (Fig. 1). The grade of mitral valve regurgitation was evaluated as 4°, and that of aortic valve regurgitation as 2°. The left ventricular ejection fraction (LVEF) was 61%, and the diastolic left ventricular diameter (LVDD) was 65 mm. A chest X-ray (Fig. 2) revealed pulmonary congestion. The cardiothoracic ratio was 62%, suggesting heart failure. Under a diagnosis of IE, ampicillin sodium (8 g \times 4/day) and gentamicin sulfate (120 mg \times 2/day) were administered, and heart failure treatment with a diuretic was simultaneously started. The patient was negative for β -D glucan. Thereafter the WBC and CRP values decreased, and pyretolysis was achieved. However, fever (39°C or higher) and an increase in the CRP level (3.5 \rightarrow 10.2 mg/dl) were observed 23 days after admission. A blood culture revealed *T. asahii*. The β -D glucan level was increased to 54.4 pg/ml, and the patient was positive for galactomanan antigen, suggesting *T. asahii* fungemia. Immediately

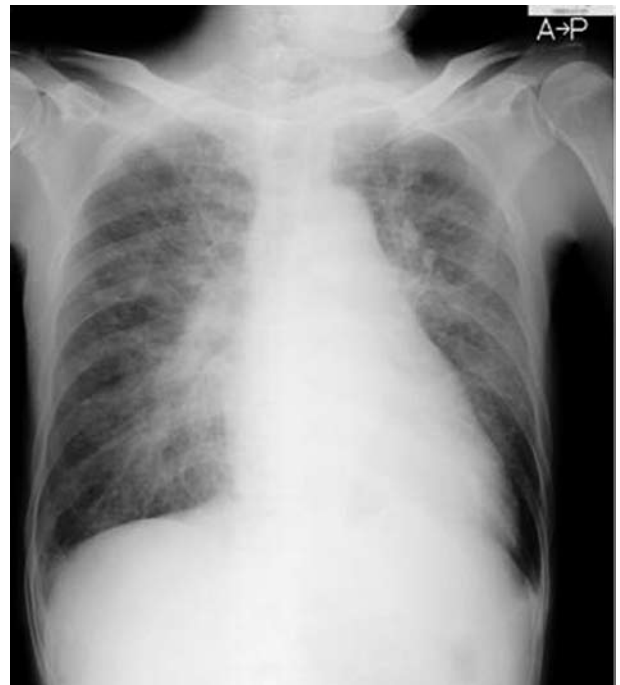

Fig. 2. Chest X-ray photograph.
The cardiothoracic ratio was increased (62%), and pulmonary congestion was noted.

an intravenous drip of fluconazole at 400 mg/day was initiated. Aortic and mitral valve replacement for IE was performed 34 days after admission. Extracorporeal circulation was established by blood withdrawal via the superior vena cava and inferior vena cava and supply from the ascending aorta, and antegrade cardioplegic solution was infused. Under cardiac arrest, the ascending aorta was incised, and the valve was examined. In the right coronary cusp, vegetation measuring 3.5 \times 4 mm was noted (Fig. 3), and aortic valve replacement was performed. When the mitral valve was examined, extensive valve cusp deviation with rupture of the tendon at the anterior cusp was observed (Fig. 3). Mitral valve replacement was performed. Pathological examination showed zony fibrosis and myxoid degeneration and fibrin adhesion with neutrophil infiltration, suggesting vegetation formation in a portion of the two valves. No strain of *streptococcus* oralis was detected. Neither mycelial threads nor conidia of *T. asahii* were detected.

After surgery, ampicillin sodium, gentamicin sulfate, and fluconazole were administered at the same doses as before surgery. The WBC and CRP values favorably decreased. There was no fever. A blood culture after surgery revealed neither *streptococcus* oralis nor *T. asahii* at any

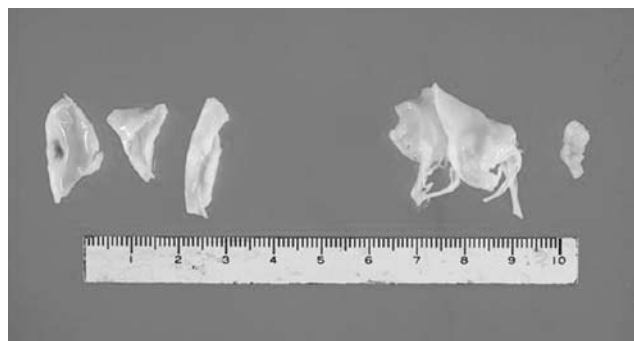


Fig. 3. Intraoperative specimen.

Aortic valve cusp (left) and mitral anterior leaflet and vegetation (right).

point. The patient was negative for β -D glucan, which was measured 2 days after surgery. More than 10 days after surgery, however, the β -D glucan level ranged from 11 to 25 pg/ml, showing an additional increase. After 6 weeks of postoperative follow-up, ampicillin sodium and gentamicin sulfate were discontinued. On confirming a β -D glucan-negative finding 7 weeks after surgery, we switched the intravenous drip of fluconazole to oral administration at 200 mg/day. The patient was discharged 52 days after surgery.

Discussion

Trichosporon species are a type of yeastlike fungi extensively distributed in nature and isolated from the human pharynx and skin. Recently some studies have reported disseminated deep mycosis associated with this type of fungus.¹⁻³⁾ It is emphasized that this type of fungus causes fatal opportunistic infection in immunocompromised hosts. High-risk patients include those after organ transplantation (including bone marrow transplantation), those with burns, prosthetic heart valves, or human immunodeficiency virus infection, and those undergoing peritoneal dialysis.¹⁻³⁾

Among various types of *Trichosporon*, *T. cutaneum* and *T. beigeli* are pathogenic. The former is classified into approximately 20 types. Currently, pathogens such as *T. asahii* and *T. mucoides* are considered to be involved in deep mycosis. Usually, the incidence of trichosporonosis in deep mycosis patients is approximately 5%.²⁾ Neither the diagnosis nor the treatment of this disorder has been established. The mortality rate ranges from 64% to 83%, showing a poor prognosis.³⁾

The route via which *Trichosporon* invades the human body remains to be unclarified. However, it may invade

through the intestinal tract, upper respiratory tract, or a venous catheter. Anticancer chemotherapy-related disorders of the digestive tract mucosa, bone marrow suppression, and broad-spectrum antimicrobial agent-related disturbance of the intestinal flora may be etiologically involved in the onset and deterioration of this disorder.²⁾ No diagnostic procedure other than blood culture has been established. If *Trichosporon* is cultured in blood or cerebrospinal fluid samples, which are essentially sterile, it may be regarded as a causative fungus. Pathologically, when a *Trichosporon* mycelial thread or conidium is observed in a biopsy specimen, a definitive diagnosis is made. Immunostaining with anti-*Trichosporon* antibody is useful.⁴⁾ For a serological test, *Trichosporon* exhibits the glucuronoxylomannan (GXM) antigen, which is known as the *Cryptococcus* capsular antigen, and the detection of this antigen is useful for a rapid diagnosis.⁵⁾ For the same reason, some patients become positive for the *Cryptococcus* antigen. Patients with this disorder are also positive for β -D glucan. However, in the presence of mycosis other than this disorder, positive findings are also noted; therefore the specificity is low. In some hospitals it is being investigated as to whether early diagnosis via the polymerase chain reaction (PCR) method using blood samples is possible.^{6,7)}

No treatment has been established. A study reported that the therapeutic effects of triazoles (fluconazole and voriconazole) were more potent than those of amphotericin B.⁸⁾ Another study recommended combination therapy with triazoles and amphotericin B.⁹⁾ *Trichosporon* shows a spontaneous resistance to candins. In our patient, infection could be favorably controlled by an intravenous drip of fluconazole. In the future, close follow-up must be performed while continuing oral antifungal therapy. In any case, antifungal agents to which this type of fungus is susceptible should be selected.

Concerning surgery, aortic and mitral valve replacements were performed. With respect to the mitral valve, favorable results of mitral valve plasty have been reported. In our patient, however, aortic valve replacement was necessary, and extensive valve cusp deviation, in which correction was considered to be difficult, was noted in the anterior cusp of the mitral valve; therefore valve replacement was selected.

To treat active IE, long-term antibiotic therapy, involving the pre- and postoperative periods, is required. However, when bacteria competing with the fungus are reduced by antibiotics, the fungus may proliferate, resulting in fungemia. Risk factors for fungal infection include

antibiotic therapy for 14 days or more, and persistent systemic infection. In particular, in the treatment of IE, antibiotic therapy is often prolonged, leading to fungal infection in some patients.¹⁰⁾ To our knowledge, there has been no reported case of active IE complicated by *T. asahii* fungemia and cured by surgical treatment. In our patient, hemorrhagic cerebral embolism developed, and heart failure could be controlled by medical treatment. Therefore, to prevent the exacerbation of cerebral complications, surgery was performed 4 weeks after the onset of cerebral embolism. We presented a rare case in which *T. asahii* fungemia occurred during antibiotic therapy for bacterial endocarditis, and survival was achieved by 2-valve replacement and fluconazole therapy.

References

1. Ghiasian SA, Maghsood AH, Mirhendi SH. Disseminated, fatal *Trichosporon asahii* infection in a bone marrow transplant recipient. *J Microbiol Immunol Infect* 2006; **39**: 426–9.
2. Tokimatsu I, Karashima R, Yamagata E, Yamakami Y, Nagai H, et al. Pathogenesis of *Trichosporon asahii* and strategies for infectious control of disseminated trichosporonosis. *Nippon Ishinkin Gakkai Zasshi* 2003; **44**: 181–6. (in Jpse.)
3. Krcmery V Jr, Mateicka F, Kunová A, Spánik S, Gyarfás J, et al. Hematogenous trichosporonosis in cancer patients: report of 12 cases including 5 during prophylaxis with itraconazol. *Support Care Cancer* 1999; **7**: 39–43.
4. Walsh TJ. Trichosporonosis. *Infect Dis Clin North Am* 1989; **3**: 43–52.
5. McManus EJ, Jones JM. Detection of a *Trichosporon beigellii* antigen cross-reactive with *Cryptococcus neoformans* capsular polysaccharide in serum from a patient with disseminated *Trichosporon* infection. *J Clin Microbiol* 1985; **21**: 681–5.
6. Yamagata E, Kamberi P, Yamakami Y, Hashimoto A, Nasu M. Experimental model of progressive disseminated trichosporonosis in mice with latent trichosporonemia. *J Clin Microbiol* 2000; **38**: 3260–6.
7. Nagai H, Yamakami Y, Hashimoto A, Tokimatsu I, Nasu M. PCR detection of DNA specific for *Trichosporon* species in serum of patients with disseminated trichosporonosis. *J Clin Microbiol* 1999; **37**: 694–9.
8. Wolf DG, Falk R, Hacham M, Theelen B, Boekhout T, et al. Multidrug-resistant *Trichosporon asahii* infection of nongranulocytopenic patients in three intensive care units. *J Clin Microbiol* 2001; **39**: 4420–5.
9. Ramos JM, Cuenca-Estrella M, Gutierrez F, Elia M, Rodriguez-Tudela JL. Clinical case of endocarditis due to *Trichosporon inkin* and antifungal susceptibility profile of the organism. *J Clin Microbiol* 2004; **42**: 2341–4.
10. Bross J, Talbot GH, Maislin G, Hurwitz S, Strom BL. Risk factors for nosocomial candidemia: a case-control study in adults without leukemia. *Am J Med* 1989; **87**: 614–20.