Case Report

One-Stage Minimally Invasive Direct CABG by a Transdiaphragmatic Approach Combined with Abdominal Aortic Aneurysm Repair to Avoid Postoperative Cardiovascular Event

Masaki Yamamoto, MD, Hideaki Nishimori, MD, Takashi Fukutomi, MD, Seiichiro Wariishi, MD, Kentaro Hirohashi, MD, and Shiro Sasaguri, MD

Coronary artery disease (CAD) coexists in 40% of cases with abdominal aortic aneurysm (AAA). Previous reports have demonstrated the progression of myocardial ischemia after AAA repair and an increased rate of AAA rupture after coronary artery bypass grafting (CABG). We herein describe the case of a 63-year-old man who underwent CABG combined with AAA repair to prevent perioperative cardiovascular events. Computed tomography revealed an AAA 49 mm in diameter. Coronary angiography demonstrated single-vessel CAD localized to the right coronary artery. The patient underwent percutaneous coronary intervention before aortic surgery. On follow-up coronary angiography, restenosis was detected in the stent. In a second strategy, AAA repair was combined with CABG and performed with the aim of preventing cardiovascular events. A short laparotomy was performed, and an off-pump CABG was performed using the in situ right gastroepiploic artery via a transdiaphragmatic approach without sternotomy. The small abdominal incision provided stability of the surgical retractor sufficient for fixing a heart-stabilizing device. Furthermore, a surgical retractor was used in an inverted V position to ensure sufficient space for the surgery. We conclude that a one-stage operation comprising CABG and AAA repair and using a transdiaphragmatic approach is a safe and reasonable operative procedure. (Ann Thorac Cardiovasc Surg 2009; 15: 354–357)

Key words: transdiaphragmatic approach, coronary artery disease, abdominal aortic aneurysm

Introduction

Patients with an abdominal aortic aneurysm (AAA) often have coexisting coronary artery disease (CAD) because both diseases are atherosclerotic. Approximately 40%–60% of all patients for AAA repair presented CAD.[1,2] Patients with CAD treated by percutaneous coronary intervention (PCI) or coronary artery bypass grafting (CABG) have a clearly decreased mortality rate.[2,3] It has been recommended that coronary revascularization should be performed before AAA repair.[3,4] The transdiaphragmatic approach to the heart, using laparotomy and partial sternotomy, has been reported to be an effective surgical technique.[5] Furthermore, single-vessel disease confined to the right coronary artery (RCA), and that could be approached by this transdiaphragmatic route by laparotomy, may be a better indicator for combined CABG and AAA repair. This one-staged operation strategy is minimally invasive and prevents the risk of complica-

From Department of Surgery II, Faculty of Medicine, Kochi University, Kochi, Japan

Received September 18, 2008; accepted for publication September 24, 2008
Address reprint requests to Masaki Yamamoto, MD: Department of Surgery II, Faculty of Medicine, Kochi University, Oko-cho Kohasu, Nankoku, Kochi 783–8505, Japan.

tions arising from untreated cardiovascular disease.

Case

A 63-year-old man had a 3-year history of chest oppression on effort. A chest X-ray revealed cardiomegaly. Computed tomography revealed a fusiform-type aneurysm of the infrarenal abdominal aorta 49 mm in diameter (Fig. 1). Color Doppler echocardiography showed moderate aortic valve regurgitation resulting from mild organic change. Left ventricular end-diastolic and end-systolic dimensions were 50/28 mm, and the left ventricle ejection fraction was 78%. Coronary angiography demonstrated single-vessel CAD with chronic total occlusion of the RCA (#1) (Fig. 2A). The patient underwent a two-stage strategy of assessment of CAD in the presence of AAA. Catheter interventional therapy was indicated before aortic surgery, and direct PCI for the occluded RCA was performed (Fig. 2B). The lesions were sequentially dilated, and four bare metal stents (Multi-Link Zeta™ 2.5 × 28 mm, Multi-Link Zeta™ 3.0 × 33 mm, Multi-Link Zeta™ 3.0 × 33 mm, and Multi-Link Vision™ 3.5 × 18 mm; Abott Vascular, Santa Clara, CA) were implanted in overlapping fashion. Follow-up coronary angiography was performed, and 75%–90% stent stenosis (#1, #2, and #3) was detected (Fig. 2C). The patient underwent combined CABG on the beating heart with a transdiaphragmatic approach and abdominal aortic replacement because the indicator for repeat intervention was not present and to prevent the risk of complications arising from the cardiac event. Furthermore, the progression of AR and the requirement for aortic valve replacement were predicted. We therefore considered that median sternotomy should be avoided.

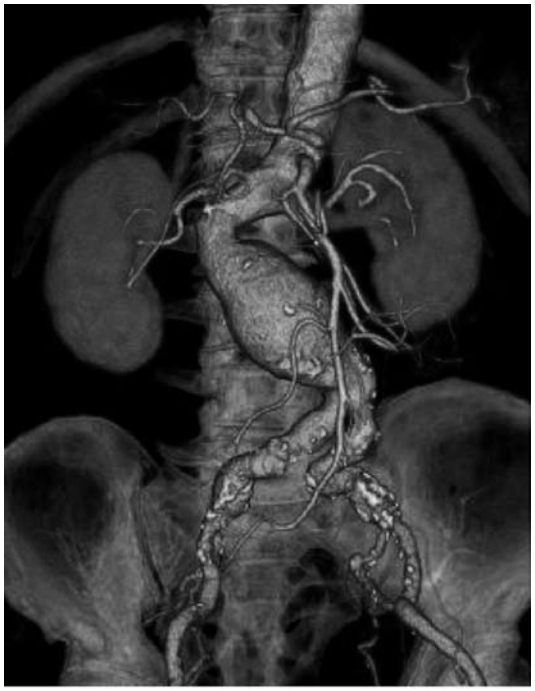

Fig. 1. Preoperative computed tomography scan, indicating a fusiform-type aneurysm of the infrarenal abdominal aorta 49 mm in diameter.

Surgical Technique

After the establishment of general anesthesia, the patient was placed in the spine position. Briefly, a short median laparotomy was performed in the subxiphoid midline, and the right gastroepiploic artery (RGEA) was harvested in a skeletonized fashion (Fig. 3). A retraction of the bilateral costal arches with a Kent retractor and the dorsal extension of the back created a large space between the liver and the diaphragm. After a longitudinal incision of the diaphragm and pericardium to expose the RCA, an additional transverse incision of the diaphragm to the distal side was made to clearly individualize the target coronary artery. In this case we chose the right atrioventricular branch (#4AV) as the target coronary vessel. The heart was stabilized with double suspension sutures behind the retropericardium and stabilizer (Octopus 3™ and Starfish™; Medtronic, Inc., Minneapolis, MN). The small incision in the abdominal wall provided stability of the surgical retractor and stabilizer without the need for partial sternotomy to fix the retractor. After heparinization (100 IU/kg), the distal side of the RGEA was passed through the diaphragm. The elastic thread was snared above the anastomotic site to elevate the heart and to temporarily block the blood flow. The coronary artery was opened, and the distal anastomosis was fashioned with a continuous suture with an 8-0 monofilament. Therefore heparin was not reversed with protamine to maintain anticoagulation during the operation. After the cardiac procedure, the skin incision was extended to lower and the infrarenal abdominal aorta was exposed. The aortic aneurysms were repaired with collagen-coated Dacron bifurcated graft (Gelsoft Plus™ 16 × 8 mm, Vascutek, Inchinnan, UK). The total operative time was 520 minutes, and total blood loss was 580 ml. The endotracheal tube was removed 12 hours after the operation. The patient was discharged in good condition without severe cardiovascular complications and has had a satisfactory postoperative course for 1 year. Follow-up angiography revealed graft patency (Fig. 4).

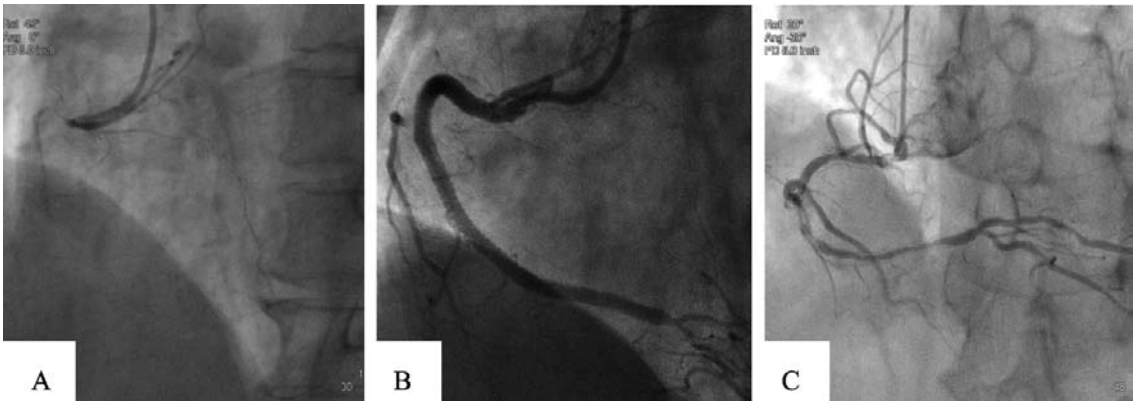

Fig. 2. Coronary angiography of the right coronary artery (RCA).
Left anterior oblique views.
A: Chronic total occlusion in RCA was indicated.
B: Severe calcification in RCA was ablated, followed by the implantation of bare metal stents.
C: Follow-up coronary angiography was performed 6 months after stent placement, and 75%–90% stenosis (#1, #2, and #3) in the stent was detected.



Fig. 3. Surgical procedure of minimally invasive direct coronary artery bypass grafting, using the transdiaphragmatic approach.
A median laparotomy was performed. The heart was exposed and stabilized. The distal anastomosis was made using the in situ right gastroepiploic artery (RGEA).
Arrow, RGEA; arrowhead, #4 atrioventricular branch (#4AV).

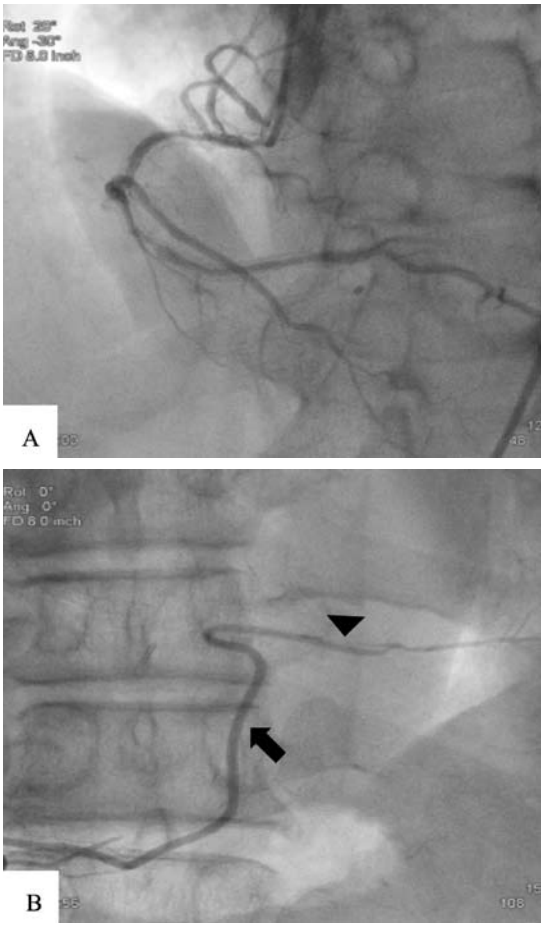

Fig. 4. Postoperative coronary angiography of right coronary artery (RCA) (**A**) and right gastroepiploic artery (RGEA) (**B**).
A: A native coronary arterial perfusion was detected.
B: Graft patency was revealed.
Arrow, RGEA; arrowhead, #4 atrioventricular branch (#4AV).

Discussion

In a previous report, myocardial ischemia progressed in approximately 6%–25% of patients who underwent AAA repair before coronary revascularization; in contrast, other investigators found a rupture rate after CABG of 3.0%–10.5% in patients in whom CAD coexisted with CABG.[6,7] Attia et al. demonstrated that infrarenal aortic cross-clamping caused myocardial ischemia in CAD patients who responded to cross-clamping with an increase

in central venous pressure of 7 mmHg.[8] Swanson et al. suggested that collagen lysis of the aortic wall increases after major unrelated surgery.[9]

This patient had an AAA coexisting with CAD confined to the RCA and underwent the PCI before AAA repair in a two-stage strategy. The follow-up CAG revealed restenosis of the PCI site. There was no indication calling for repeat PCI, though myocardial revascularization should be performed before surgical treatment of the AAA to prevent cardiac events. The simultaneous operation reduced respiratory function after thoracolaparotomy. Therefore excessive surgical stress of a simultaneous operation may be a serious problem in patients with coexisting CAD and AAA. Our simultaneous procedure with a transdiaphragmatic approach through laparotomy without sternotomy or thoracotomy was well adapted to this case because the target coronary artery was confined to the RCA.

Takahashi et al. reported that CAD localized to the RCA can be treated by grafting the RGEA or great saphenous vein through a transdiaphragmatic approach with a simple laparotomy and partial sternotomy.[10] The point of the transdiaphragmatic approach is to make a large space between the diaphragm and the liver.[10] With the patient in the supine position, we generally place a pillow under the patient's back, and we flex the surgical bed in an arrowlike configuration. After longitudinal incision of the diaphragm and pericardium to expose the RCA, an additional transverse incision of the diaphragm to the distal side is made to clearly individualize the target coronary artery, whether it is the right posterior descending artery (#4PD) or the atrioventricular artery (#4AV). Furthermore, we fix the stabilizing devices (Starfish™ and Octopus™) to the surgical retractor to create an immobile field. In this case a minimal laparotomy of approximately 15 cm and the stability of the surgical retractor prevented the need for partial sternotomy to fix the surgical retractor and stabilizing device.

We surmise that transdiaphragmatic minimally invasive direct coronary artery bypass grafting (MID-CAB) without sternotomy or thoracotomy widens the indications for simultaneous CABG for AAA patients with CAD localized to the RCA.

References

1. Bayazit M, Göl MK, Battaloglu B, Tokmakoglu H, Tasdemir O, et al. Routine coronary arteriography before abdominal aortic aneurysm repair. *Am J Surg* 1995; **170**: 246–50.
2. Hertzer NR, Beven EG, Young JR, O'Hara PJ, Ruschhaupt WF 3rd, et al. Coronary artery disease in peripheral vascular patients. A classification of 1000 coronary angiograms and results of surgical management. *Ann Surg* 1984; **199**: 223–33.
3. Golden MA, Whittemore AD, Donaldson MC, Mannick JA. Selective evaluation and management of coronary artery disease in patients undergoing repair of abdominal aortic aneurysms. A 16-year experience. *Ann Surg* 1990; **212**: 415–23.
4. Kioka Y, Tanabe A, Kotani Y, Yamada N, Nakahama M, et al. Review of coronary artery disease in patients with infrarenal abdominal aortic aneurysm. *Circ J* 2002; **66**: 1110–2.
5. Takahara Y, Sudo Y, Ishida K, Matsuura K. Simultaneous coronary arterial bypass surgery using mini-sternotomy and off-pump methods and abdominal aneurysm repair. *Eur J Cardiothorac Surg* 2001; **19**: 935–7.
6. Ascione R, Iannelli G, Lim KH, Imura H, Spampinato N. One-stage coronary and abdominal aortic operation with or without cardiopulmonary bypass: early and midterm follow-up. *Ann Thorac Surg* 2001; **72**: 768–75.
7. Ruby ST, Whittemore AD, Couch NP, Collins JJ, Cohn L, et al. Coronary artery disease in patients requiring abdominal aortic aneurysm repair. Selective use of a combined operation. *Ann Surg* 1985; **201**: 758–64.
8. Attia RR, Murphy JD, Snider M, Lappas DG, Darling RC, et al. Myocardial ischemia due to infrarenal aortic cross-clamping during aortic surgery in patients with severe coronary artery disease. *Circulation* 1976; **53**: 961–5.
9. Swanson RJ, Littooy FN, Hunt TK, Stoney RJ. Laparotomy as a precipitating factor in the rupture of intra-abdominal aneurysms. *Arch Surg* 1980; **115**: 299–304.
10. Takahashi K, Minakawa M, Kondo N, Oikawa S, Hatakeyama M. Coronary artery bypass surgery by the transdiaphragmatic approach. *Ann Thorac Surg* 2002; **74**: 700–3.