Original Article

The Effects of Sheet-Type Absorbable Topical Collagen Hemostat Used to Prevent Pulmonary Fistula after Lung Surgery

Hideaki Miyamoto, MD, Yukinori Sakao, MD, Motoki Sakuraba, MD, Shiaki Oh, MD, Nobumasa Takahashi, MD, Yoshikazu Miyasaka, MD, Taku Akaboshi, MD, and Tomoya Inagaki, MD

Background: Numerous reports have been published on the application of fibrin glues, biological adhesives used as sealants for air leaks after pulmonary resection; however, the use of blood products has been questioned from both safety and economic perspectives. Therefore we were prompted to attempt the use of Integran® (method C), a sheet-type absorbable topical collagen hemostat that is neither expensive nor derived from blood.
Objective: To compare the efficacy of method C with that of method G, a combined approach in which TachoComb® or a polyglycolic acid (PGA) sheet was fixed with a fibrin glue in a randomized controlled trial to prevent pulmonary fistula formation after lung surgery.
Materials and Methods: Of the patients who were scheduled to undergo pulmonary resection in 2006 at the Department of General Thoracic Surgery, Juntendo University, and who provided informed consent for the study before surgery, those who developed visible air leaks during lobectomy, segmentectomy, partial resection for lung tumor or pulmonary cyst, or intractable pneumothorax were included as the subjects of this study. The subjects were randomized for treatment with either of 2 procedures, namely, method C or method G. Pulmonary fistula was defined as an obvious air leak persisting until day 3 after surgery.
Results: A total of 38 patients were assigned to method C and 34 to method G. Three patients (7.9%) assigned to method C (including 1 who underwent lobectomy and 2 who underwent partial resection), and 6 (17.6%) patients assigned to method G, including 3 who each underwent a lobectomy and partial resection, developed postoperative pulmonary fistula. The incidence of pulmonary fistula was significantly lower in the group assigned to method C, with a statistically significant difference of p = 0.044.
Conclusions: In a Randomized Controlled Trial of Sealing with a Sheet-type Collagen vs. a Combined Approach of Fixing a Collagen Sponge, Using Fibrin Glue for Closure of Air Leaks, the use of Integran®, a sheet-type absorbable topical collagen hemostat, is feasible to prevent pulmonary fistula after lung surgery. It is also affordable and safe because it is not a blood product. (Ann Thorac Cardiovasc Surg 2010; 16: 16–20)

Key words: air leak, sheet-type collagen, Integran®, fibrin glue, TachoComb®

From Department of General Thoracic Surgery, Juntendo University, Tokyo, Japan

Received September 16, 2008; accepted for publication January 5, 2009

Address reprint requests to Hideaki Miyamoto, MD: Department of General Thoracic Surgery, Southern Tohoku Research Institute & General Hospital, 7–115 Yatsuyamada Koriyama, Fukushima 963–8563, Japan.

Introduction

The use of various sealants for air leaks after pulmonary resection has been reported in the field of pulmonary surgery, and recently there have been many reports on the use of fibrin glue, a biological adhesive.[1–4] In particular, the efficacy of a combined approach using TachoComb®, a spongelike collagen fibrin agent (a spongelike collagen sheet with a layer of dry fibrinogen, thrombin, and aprotinin firmly fixed to one side),[5,6] or a bioabsorbable polyglycolic acid (PGA) mesh sheet, and fibrin glue has been widely reported.[7–10] However, the use of blood products has been questioned from the perspectives of both safety and economics. Therefore we attempted the use of a new product, Integran® (Integran/Emistat; Nippon Zoki Pharmaceutical Co., Ltd.; and KOKEN CO., LTD., Tokyo, Japan), a sheet-type absorbable topical collagen hemostat, which is less expensive and not derived from blood. We conducted this randomized controlled trial with the objective of comparing the effect of Integran® (method C) and that of a method using fibrin glue (method G) to prevent pulmonary fistula formation after lung surgery.

Materials and Methods

Of 300 patients who underwent pulmonary surgery in 2006 at the Department of General Thoracic Surgery, Juntendo University, we selected 72 who were scheduled to undergo pulmonary resection and who agreed to provide informed consent for this study before surgery. Subjects who showed evident air leaks that remained even after surgical treatment (e.g., suture during surgery) following pulmonary resection (lobectomy, segmentectomy, or partial resection) for lung cancer, metastatic lung tumors, pulmonary cysts (excluding spontaneous pneumothorax), or intractable pneumothorax were enrolled in this study. The pulmobronchial stump was sutured with a stapler, and patients with severe pleural adhesions were excluded from the study. The subjects were randomized to 1 of 2 methods for sealing air leaks: method C, using a pressed sheet type of Integran® (100 × 50 mm and 0.2 mm thick), which was cut to an appropriate size and applied to the site of the air leak in the lung (Figs. 1, 2, and 3); Method G, using TachoComb® (95 × 48 mm), which was applied directly to the site, or Neoveil®, an absorbable PGA mesh sheet, (100 × 50 mm), which was cut to an appropriate size, and either TachoComb® or Neoveil® was fixed to the site with a fibrin glue (Beriplast® or Bolheal®). As a rule, TachoComb® was selected for a small air leak and Neoveil® for large ones, both being used in combination with a fibrin glue. Of a total of 72 patients enrolled in the study, 38 were assigned to method C and 34 to method G. Of the patients randomized to method G, TachoComb® was used in 4. In all 4, there were 1 or 2 sites of small (≤ 3 cm) air leakages after lobectomy. Pulmonary fistula was defined as an obvious air leak from the drain persisting until day 3 (72 hours) after surgery, at which time treatment was begun. The incidence of pulmonary fistula formation in patients assigned to the 2 methods above was statistically analyzed. The data were considered to be significant when the p value was 0.05 or less, and adverse events (possible adverse reactions) were monitored.

Results

A total of 38 patients was assigned to method C: 22 patients were scheduled for lobectomy, 5 for segmentectomy, and 11 for partial resection. A total of 34 patients was assigned to method G: 23 were scheduled for lobectomy and 11 for partial resection. The distribution of patients is shown in Table 1. There was no statistically significant difference in any of the background characteristics between the two groups, and the results are presented in Table 2 by surgical procedure. Three patients (7.9%) assigned to method C, 1 who underwent lobectomy and 2 who underwent partial resection, were diagnosed to have postoperative pulmonary fistula; none of the patients undergoing segmentectomy developed a pulmonary fistula. Six patients (17.6%) assigned to method G, 3 who underwent lobectomy and 2 who underwent partial resection, were diagnosed to have postoperative pulmonary fistula. None of the 4 patients treated with the TachoComb® developed a pulmonary fistula. Among the 3 assigned to method C who developed a pulmonary fistula, the fistula closed spontaneously in 1 patient, and pleurodesis by intrathoracic injection of drugs was required in the remaining 2. Among the 6 patients assigned to method G who developed a pulmonary fistula, the fistula resolved spontaneously in 1, and pleurodesis by intrathoracic injection of drugs was required in the remaining 5. All of these patients showed closure of the pulmonary fistula with conservative treatment and were discharged from the hospital. However, lung collapse occurred in 2 patients assigned to method G on day 5 after the surgery, and a drain needed to be reinserted. None of the patients developed adverse reactions. Statistically, the incidence of pulmonary fistula was significantly lower in the patient group assigned to method C than in the group assigned to method G ($p = 0.044$).

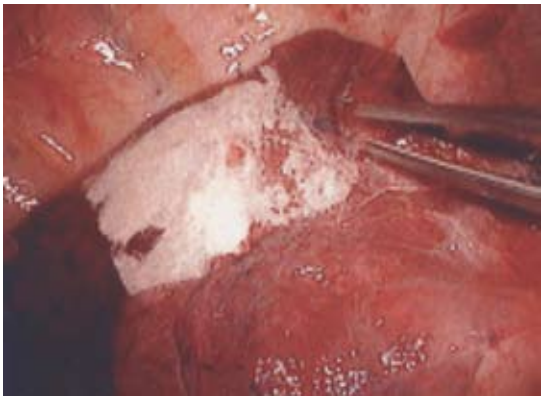

Fig. 1. Sealing by sheet-type collagen (Intergran®).

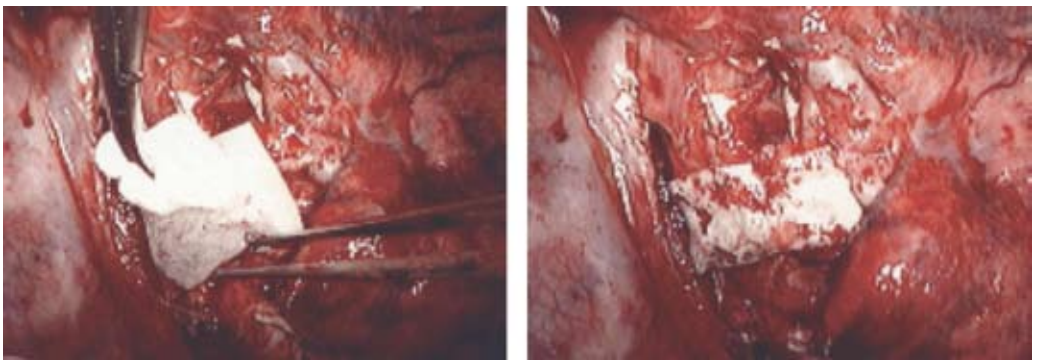

Fig. 2. Post-right lower lobectomy.

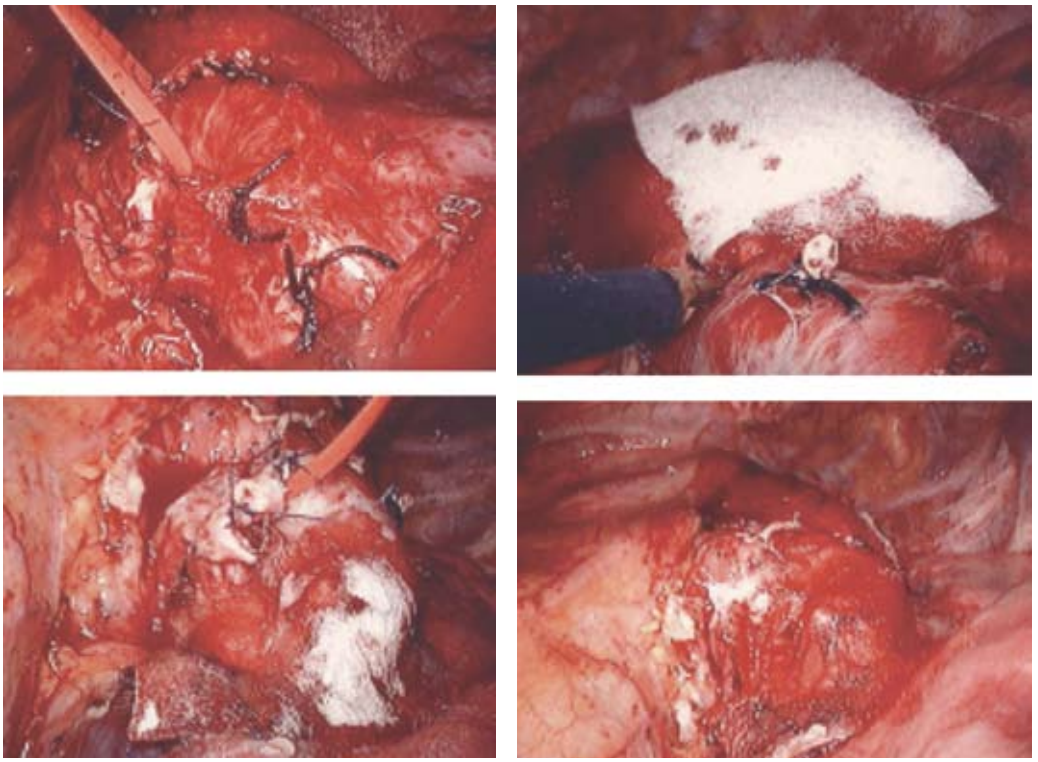

Fig. 3. Air leak from inter-lobe with post-VATS left upper lobectomy.

No adverse events suspected as adverse reactions occurred in either group.

Discussion

Control of air leaks after pulmonary resection is of clinical importance because it greatly influences the risk of postoperative complications, length of hospitalization, and patients' quality of life.[11,12]

Various sealants have been reported for closure of air leaks after pulmonary resection in the field of pulmonary surgery. In Japan, fibrin glues, which are biological adhesives and plasma derivatives, are most often used for this purpose. In particular, there have been many reports recently of the efficacy of a combined approach in which TachoComb®,[13,14] a spongelike collagen fibrin agent (a spongelike collagen sheet with a layer of dry fibrinogen, thrombin, and aprotinin firmly fixed to one side) or a bioabsorbable PGA mesh is fixed with a fibrin glue.[7–10] However, the use of blood products has been questioned from the standpoints of safety (a risk of blood-borne infections, such as AIDS and hepatitis,[15] and anaphylaxis[16,17]) and of economics (the high cost poses a medicoeconomic problem). In Japan, the price of TachoComb® (95 × 48 mm) is at least 25 times that of the press sheet-type Integran® (100 × 50 mm, 0.2 mm thick) used in this study. And Neoveil®, an absorbable PGA mesh sheet, (100 × 50 mm) is 3.4 times as expensive as Integran®. Moreover, the use of fibrin glue (Beriplast® or Bolheal®) to fix these products increases the cost even further.

Consequently, we considered attempting a new approach to the use of Integran®, a sheet-type absorbable topical collagen hemostat, which is more affordable and is not a blood product. Today, collagen has multiple uses in the development of drugs, quasi-drugs, cosmetics, and medical devices. It is especially effective for hemostasis and is therefore commonly used as a hemostat in the medical field.[18] Integran® was launched in the market as an absorbable topical hemostat. Furthermore, collagen has been known to be a good tissue scaffold in the field of regenerative medicine and tissue engineering, and it is also known to promote the formation of granulation tissue in defects.[19–21] The raw material used to produce Integran® is atelocollagen derived from the dermis of Australian calves by enzyme solubilization and purification. The product contains no protein other than atelocollagen and therefore has low antigenicity.[20,22] No safety concern has been raised for Integran® until now, based on currently available reports. The purified atelocollagen is subjected to spinning and chemical cross-linking using a polyepoxy compound to convert it into an insoluble and physically stable fiber.[23] Lastly, Integran® is a highly biocompatible product that is absorbed by the body. It has a Japanese paperlike thin form and a strong cotton-fiber structure as compared to other collagen products, and it is easily usable with good adhesiveness.

This randomized controlled clinical trial was conducted with the intention of determining the efficacy of Integran® in preventing pulmonary fistula formation after pulmonary resection in comparison with that of the conventionally employed fibrin glues. The results showed that Integran® was significantly superior to the fibrin glues. TachoComb®, the group assigned to which showed no pulmonary fistula formation, was included in this study's method G, along with the fibrin glues; however, it might be inappropriate to use it for comparison with Integran®, since TachoComb® also contains collagen. Although any material will not stick again to tissue after removal or coming off for some reason, collagen will easily readhere. It is also assumed to promote tissue regeneration. Moreover, once the fibrin glue dissolves in a few days, the material that was fixed with it becomes easily detached. The reason why 2 patients in this study assigned to method G developed lung collapse on day 5 after surgery may be because the fibrin glue dissolved around that time. In regard to these findings, the results of this study would not negate the

Table 1. Patients' background

	Method C	Method G
No.	38	34
Male/female	22/16	25/9
Average age	61.7	59.9
Lung cancer	27 (1)	23 (3)
Lung metastasis	5	2
Pulmonary bulla	5 (2)	8 (2)
Intractable air leak	1	1 (1)

( ), number of air leaks.

Table 2. Results

	Method C	Method G
Lobectomy	22 (1)	23 (3)
Segmentectomy	5	0
Partial resection	11 (2)	11 (3)
No.	38 (3)	34 (6)

( ), number of air leaks.

efficacy of fibrin glues, but they would focus on the efficacy of collagen.

A comparison of collagen products of the same type has revealed that the sheet form is more easily applicable than the powder or cotton form, and that Integran®, an extremely thin and strong press sheet, is excellent in terms of both operability and applicability.

Conclusions

The use of a sheet-type absorbable topical collagen hemostat to prevent pulmonary fistula formation after lung surgery is highly feasible because it is affordable, safe, and effective.

References

1. Bayfield MS, Spotnitz WD. Fibrin sealant in thoracic surgery. Pulmonary applications, including management of bronchopleural fistula. *Chest Surg Clin N Am* 1996; **6**: 567–83.
2. Gagarine A, Urschel JD, Miller JD, Bennett WF, Young JE. Effect of fibrin glue on air leak and length of hospital stay after pulmonary lobectomy. *J Cardiovasc Surg* (*Torino*) 2003; **44**: 771–3.
3. Fabian T, Federico JA, Ponn RB. Fibrin glue in pulmonary resection:a prospective, randomized, blinded study. *Ann Thorac Surg* 2003; **75**: 1587–92.
4. Mouritzen C, Dromer M, Keinecke H. The effect of fibrin glueing to seal bronchial and alveolar leakages after pulmonary resections and decortications. *Eur J Cardiothorac Surg* 1993; **7**: 75–80.
5. Izbicki JR, Kreusser T, Meier M, Prenzel KL, Knoefel WT, et al. Fibrin-glue-coated collagen fleece in lung surgery—experimental comparison with infrared coagulation and clinical experience. *Thorac Cardiovasc Surg* 1994; **42**: 306–9.
6. Lang G, Csekeö A, Stamatis G, Lampl L, Hagman L, et al. Efficacy and safety of topical application of human fibrinogen/thrombin-coated collagen patch (TachoComb) for treatment of air leakage after standard lobectomy. *Eur J Cardiothorac Surg* 2004; **25**: 160–6.
7. Morikawa T, Katoh H: Improved techniques of applying fibrin glue in lung surgery. *Eur Surg Res* 1999; **31**: 180–6.
8. Kaseda S, Aoki T, Hangai N, Omoto T, Yamamoto S, et al. Treating bullous lung disease with Holmium YAG laser in conjunction with fibrin glue and DEXON mesh. *Lasers Surg Med* 1998; **22**: 219–22.
9. Mukaida T, Andou A, Date H, Aoe M, Shimizu N. Thoracoscopic operation for secondary pneumothorax under local and epidural anesthesia in high-risk patients. *Ann Thorac Surg* 1998; **65**: 924–6.
10. Miyamoto H, Futagawa T, Wang Z, Yamazaki A, Morio A, et al. Fibrin glue and bioabsorbable felt patch for intraoperative intractable air leaks. *Jpn J Thorac Cardiovasc Surg* 2003; **51**: 232–6.
11. Serra-Mitjans M, Belda-Sanchis J, Rami-Porta R. Surgical sealant for preventing air leaks after pulmonary resections in patients with lung cancer. *Cochrane Database Syst Rev* 2005: CD003051.
12. Venuta F, Rendina EA, De Giacomo T, Flaishman I, Guarino E, et al. Technique to reduce air leaks after pulmonary lobectomy. *Eur J Cardiothoracic Surg* 1998; **13**: 361–4.
13. Muramatsu T, Ohmori K, Shimamura M, Furuichi M, Takeshita S, et al. Staple line reinforcement with fleece-coated fibrin glue (TachoComb) after thoracoscopic bullectomy for the treatment of spontaneous pneumothorax. *Surg Today* 2007; **37**: 745–9.
14. Kawamura M, Gika M, Izumi Y, Horinouchi H, Shinya N, et al. The sealing effect of fibrin glue against alveolar air leakage evaluated up to 48 h; comparison between different methods of application. *Eur J Cardiothorac Surg* 2005; **28**: 39–42.
15. Berguer R, Staerkel RL, Moore EE, Galloway WB. Warning: fatal reaction of the use of fibrin glue in deep hepatic wounds. Case reports. *J Trauma* 1991; **31**: 408–11.
16. Milde LN. An anaphylactic reaction to fibrin glue. *Anesth Analg* 1989; **69**: 684–6.
17. Mitsuhata H, Horiguchi Y, Saitoh J, Saitoh K, Fukuda H, et al. An anaphylactic reaction to topical fibrin glue. *Anesthesiology* 1994; **81**: 1074–7.
18. Tomizawa Y. Clinical benefits and risk analysis of topical hemostats: a review. *J Artif Organs* 2005; **8**: 137–42.
19. Teramachi M, Nakamura T, Yamamoto Y, Kiyotani T, Takimoto Y, et al. Porous-type tracheal prosthesis sealed with collagen sponge. *Ann Thorac Surg* 1997; **64**: 965–9.
20. Ochi M, Uchio Y, Tobita M, Kuriwaka M. Current concepts in tissue engineering technique for repair of cartilage defect. *Artif Organs* 2001; **25**: 172–9.
21. Iwai S, Sawa Y, Ichikawa H, Taketani S, Uchimura E, et al. Biodegradable polymer with collagen microsponge serves as a new bioengineered cardiovascular prosthesis. *J Thorac Cardiovasc Surg* 2004; **128**: 472–9.
22. Charriere G, Bejot M, Schnitzler L, Ville G, Hartmann DJ. Reactions to a bovine collagen implant. Clinical and immunologic study in 705 patients. *J Am Dermatol* 1989; **21**: 1203–8.
23. Kodaira K, Miyata T, Furuse M, Noishiki Y. Characterization of collagenous materials crosslinked by polyepoxy compounds. *J Artif Organs* 1986; **15**: 239–42.