Original Article

Short- and Long-Term Outcomes of Acute Upper Extremity Arterial Thromboembolism

Katsuaki Magishi, MD, PhD, Yuichi Izumi, MD, PhD, and Noriyuki Shimizu, MD, PhD

Purpose: To evaluate the short-/long-term outcomes after acute thromboembolism of the upper extremity.
Materials and Methods: Twenty-one patients with acute arterial occlusion in the upper extremity were treated from January 1993 to July 2007 at our hospital. Their average age was 73.0, and 14 (66%) were male. The right and left limbs were affected in 15 cases (71%) and 6 cases (29%), respectively. The main associated disease was arrhythmia, in 20 cases (95%), including atrial fibrillation in 17 (81%). The time from onset to operation was 9.7 ± 9.2 h (range: 2–41 h). All patients underwent thromboembolectomy with a Fogarty catheter.
Results: The symptoms showed regression in all cases after operation, but one patient died from cerebral infarction the following day. Anticoagulant and antiplatelet therapies are commonly prescribed in cases after thromboembolectomy. The free rates of thromboembolism were 74% and 27%, and cumulative actuarial survival rates were 95% and 61% at 1 and 3 years, respectively.
Conclusion: Because of the high recurrence rates of thromboembolism, it seems necessary to severe anticoagulant therapy. Upper extremity thromboembolism should also be considered as one manifestation of a systemic embolism. (Ann Thorac Cardiovasc Surg 2010; 16: 31–34)

Key words: thromboembolectomy, thromboembolism, upper extremity, atrial fibrillation

Introduction

Acute arterial thromboembolism in the upper extremities is rare compared with that in the lower extremities. The most frequently used techniques for the management of acute arterial thromboembolism are administration of heparin, embolectomy, thrombolysis, and thromboaspiration. Numerous follow-up studies have been published regarding the long-term effects of embolectomy in the lower extremities. Only a few previous reports focused on the upper extremities, and most of these presented short-term outcomes. In the present study, we investigated both short- and long-term mortality and morbidity rates in cases of acute arterial thromboembolism of the upper extremities.

Materials and Methods

Twenty-one patients undergoing treatment for acute arterial thromboembolism of the upper extremity from January 1993 to July 2007 in our hospital were analyzed retrospectively based on a review of their medical records. Cases of arterial trauma, including iatrogenic cases and those with vascular graft occlusion, were excluded from this study. The average age of the patients was 73.0 ± 10.5 years (range: 54 to 91 years), and 14 patients (66%) were male. All patients presented unilateral symptoms. According to Balas's classification, 6 were in class II, 12 in class III, and 3 were not classified. The diagnosis of each patient was based on the patient's history, symptoms,

From Deparment of Cardiovascular Surgery, Nayoro City General Hospital, Nayoro, Japan

Received September 25, 2008; accepted for publication December 25, 2008
Address reprint requests to Katsuaki Magishi, MD, PhD: Deparment of Cardiovascular Surgery, Nayoro City General Hospital, Nishi 7 Minami 8–1 Nayoro, Hokkaido 096–8511, Japan.
©2010 The Editorial Committee of *Annals of Thoracic and Cardiovascular Surgery.* All rights reserved.

and findings of a physical examination. An angiogram of the upper extremity was performed in 13 cases before September 2001, after which 8 were diagnosed by 64-row multislice computed tomography (CT) and ultrasound examination. The obstruction was located in the axillary artery in 4 cases (19%) and in the brachial artery in 17 (81%). The lesion was located in the right extremity in 15 cases (71%) and in the left extremity in the remaining 6 (29%). Twenty cases (95%) showed arrhythmia, 17 (81%) atrial fibrillation (Af), 1 premature Af, and 1 premature ventricular construction (Lown classification IVb). Seven had mitral valve disease (6 complicated with Af) and 1 was implanted with a permanent pacemaker. Five patients had cerebral vascular disease (infarction in 4 and transient ischemic attack [TIA] in 1), and 4 patients with a history of previous illness had acute arterial occlusive disease in the lower extremity (Table 1). At the time of diagnosis, either anticoagulant therapy or antiplatelet therapy was administered to each of 4 patients. All patients underwent thromboembolectomy using a Fogarty catheter. This was performed under general anesthesia in 19 patients and, because of their advanced age, with local anesthesia in the remaining 2. An S-shaped incision was made in the antecubital fossa for easy identification of the brachial, radial, and ulnar arteries. Patency of the artery was monitored by angiography during the operation. After the operation, the anticoagulant warfarin and antiplatelet drugs were administered in all patients except in cases with contraindications for these drugs. The presumed origins of the emboli were examined in 15 cases by transesophageal/thoracic echocardiography and enhanced CT scanning during the perioperative period. The carotid artery was not evaluated in any case in the present study. The rates of survival and freedom from thromboembolism were estimated by the Kaplan-Meier procedure.

Table 1. Patient characteristics

Characteristic	(%)
Male sex	14 (66)
Balas's classification	
II	6 (29)
III	12 (57)
Not classified	3 (14)
Right side	15 (71)
Obstructed site	
Axillary	4 (19)
Brachial	17 (81)
Comorbidities	
Arrhythmia	20 (95)
Atrial fibrillation	17 (81)
Mitral valve disease	7 (33)
Cerebral vascular disease	5 (24)
Previous acute arterial occlusion in lower extremity	4 (19)

Results

The duration of ischemia before surgery was less than 12 h in 17 cases (81%) and from 12 to 48 h in 4 (19%). The average duration of ischemia in these patients was 9.7 ± 9.2 h (mean ± standard deviation [SD], range 2 to 41 h). According to the results of angiography after thromboembolectomy, 20 cases showed no stenosis or obstruction of the arteries in the forearm, but 1 showed obstruction of the radial artery and stenosis of the palmar arch. Ischemic symptoms disappeared in all cases after thromboembolectomy. None of the patients had any upper extremity disorders. After the operation, thrombi of the left atrium or ventricle were detected in 3 of 15 cases examined (20%), but the sources of the emboli could not be determined in the others. No operations for thrombi of the heart chamber were performed in these 3 cases, but warfarin was administered. Acute arterial occlusion of the lower extremity occurred in 1 case 4 days after thromboembolectomy, but the remaining 2 patients are alive without recurrence of thromboembolism. Warfarin was administered in 10 cases after the operation. Information on whether warfarin had been administered in 6 early cases was lacking. Warfarin and antiplatelet drugs were not administered in 3 patients because of their advanced age or in 2 who had intestinal bleeding or hemorrhagic cerebral infarction. After thromboembolectomy, a new embolism occurred in 10 cases, cerebral infarction in 8, supramesenteric artery embolism in 1, and lower extremity artery embolism in 1. These complications occurred within a week after the operation in 3 cases, which included 2 patients with cerebral infarction, both of whom died within a month after the operation. The median follow-up time after treatment was 20.2 months (range 2 to 117 months). None of the patients developed upper limb embolism after the first operation. The rate of freedom from thromboembolism was calculated as 80% at 1 month, 74% at 1 year, and 27% at 3 years after the operation (Fig. 1). The actuarial survival rate was 95% at 1 year and 61% at 3 (Fig. 2). The causes of death were cerebral infarction in 4 cases, heart failure in 2, supramesenteric artery embolism in 1, and lower extremity embolism in another. A summary is shown in Table 2.

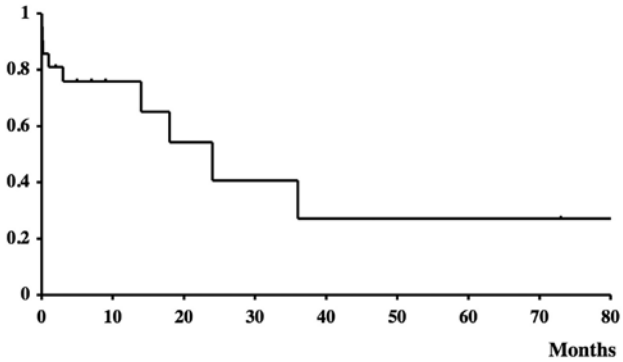

Fig. 1. Rate of freedom from thromboembolism.
Results of the Kaplan-Meier analyses of long-term patients free from thromboembolism (standard error exceeds 10% at 12 months).

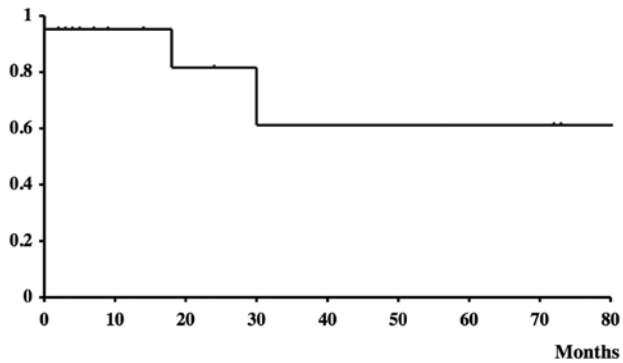

Fig. 2. Actuarial survival rate.
Results of the Kaplan-Meier analyses of long-term patients actuarial survival rate (standard error exceeds 10% at 12 months).

Discussion

Acute extremity ischemia is the most common type of emergency in vascular surgery. It accounts for 16%–33% of all cases of acute limb ischemia.[1–3] The following criteria are generally used to diagnose embolisms: a sudden clinical presentation, an absence of peripheral arteriosclerosis, and a removal of a discrete clot at operation. According to this definition, a diagnosis of embolism was made in all except 1 case in the present study. Most previous studies have suggested that embolism is associated with cardiac conditions, but this often cannot be confirmed pathologically. In previous studies, 82%–87% of cases of acute ischemia of the lower and upper extremities were classified as cardiogenic embolisms, and > 50% of patients had Af.[2,3] In the present study, 81% of the patients had Af. However, it is important to note that the management of Af may increase the risk of intracardiac thrombus formation. The prevention of cardiogenic thromboembolism requires treatment associated with phleboid thrombosis, and antithrombotic therapy is recommended in these cases. In the present study, only 4 patients (19%) were taking warfarin, an oral antithrombotic drug, before the attack. Licht et al. reported no significant differences in survival between patients who did or did not receive any anticoagulants or acetylsalicylic acid.[4] Another study indicated that postoperative anticoagulant therapy seems to improve the survival rate.[5] Warfarin showed a 64%–68% reduction in the risk of stroke in patients with Af.[6,7] The administration of warfarin may improve life-threatening conditions. After treatment of acute upper extremity ischemia, patients often develop cerebral infarction, which adversely affects daily activities and survival prognosis. A targeted intensity of the international normalized ratio (INR) from 2.0 to 3.0 was recommended in Western countries,[6,8] but INR 1.6 to 2.8 is recommended for Japanese patients. For high-risk patients with a history of thromboembolism, a target range of INR from 2.2 to 2.8 is recommended in Japanese populations.[9] Anticoagulant therapy should be applied rapidly after surgery for acute arterial thromboembolism, unless there are contraindications or the patient decides that the benefits are not worth the inconvenience. After the operation, new thromboembolisms occurred in 10 cases, including 5 in which warfarin was not used. INR control was not evaluated in the present study, though a higher INR is associated with a risk of bleeding, and especially a value over 2.25 is associated with increased hemorrhagic complications.[10]

In this series, 71% of cases occurred in the right upper

Table 2. Results

Duration for recurrence of thromboembolism	
0–1 Mo	4
2–12	1
13–24	4
25–36	1
Recurrence of thromboembolism	
Cerebral artery	8
SMA	1
Lower extremity artery	1
Cause of death	
Cerebral infarction	4
Embolism of SMA	1
CHF	2
Embolism of lower extremity	1

SMA, supramesenteric artery; CHF, chronic heart failure.

extremity, which was consistent with the results reported previously by Licht et al.[4] and in the Japanese literature,[11] indicating that 61% to 75% of embolisms occurred on the right side. However, the reasons for this right side predominance of thromboembolism have yet to be determined. It is interesting that the brachiocephalic artery arises from the first branch proximal to the curve of the normal aortic arch. Viewed from the heart, the brachiocephalic artery is located in a comparatively straight line, but other branches are divided from the middle of the arch. The right side dominance may be because of the three-dimensional structure of the arch as the right carotid artery arises from the brachiocephalic artery.

Available treatments for acute upper extremity ischemia include thromboembolectomy, thrombolysis, percutaneous transluminal angioplasty, and bypass in cases with stenosis.[12,13] Amputation and loss of function of the upper limbs are rare. However, the mid- to long-term prognosis revealed cerebral infarction in 38% of cases along with other thromboembolisms, which may have a negative impact on daily activities. Licht et al. reported poor survival rates of 54% and 37% at 3 and 5 years, respectively, after embolism in the upper limbs, and the main causes of death in long-term follow-up were cardiovascular and cerebrovascular problems in about 54% of cases.[4] Actuarial survival rate at 3 years after the operation was 61% in this series, and causes of death were cardiovascular in 4 cases and cerebral infarction also in 4.

Upper extremity thromboembolism recurred in 10 cases (48%) among patients with other lesions in this series, but acute embolism in the lower limbs showed recurrence at a rate of 10.7% in 397 patients and stroke at a rate of 3%.[14] These observations suggest a tendency for a high rate of recurrence of upper extremity thromboembolism.

In conclusion, the functional prognosis of the upper extremities is excellent with thromboembolectomy, but the risks of cerebral infarction and other thromboembolisms increased gradually after the operation. Therefore mortality and morbidity rates both became worse over long-term follow-up. Upper limb thromboembolism should also be considered a manifestation of systemic embolism.

References

1. Haimovici H. Arterial embolism of the extremities and technique of embolectomy, In: Asher E ed.; Vascular Surgery 5th ed. Massachusetts: Backwell, 2003; pp 388–408.
2. Karapolat S, Dag Ö, Abanoz M, Aslan M. Arterial embolectomy: a retrospective evaluation of 730 cases over 20 years. *Surg Today* 2006; **36**: 416–9.
3. Ueberrueck T, Marusch F, Schmidt H, Gastinger I. Risk factors and manegement of arterial emboli of the upper and lower extremities. *J Cardiovasc Surg (Torino)* 2007; **48**: 181–6.
4. Licht PB, Balezantis T, Wolff B, Baudier JF, Røder OC. Long-term outcome following thromboembolectomy in the upper extremity. *Eur J Vasc Endovasc Surg* 2004; **28**: 508–12.
5. Staudacher M, Böhm C, End A, Haberzettl C, Müller MR, et al. Embolic occlusion of arteries of the upper extremity. *Vasa* 1991; **20**: 358–64.
6. Atrial Fibrillation Investigators. Risk factors for stroke and efficacy of antithrombotic therapy in atrial fibrillation. Analysis of pooled data from five randomized controlled trials. *Arch Intern Med* 1994; **154**: 1449–57.
7. Go AS, Hylek EM, Chang Y, Phillips KA, Henault LE, et al. Anticoagulation therapy for stroke prevention in atrial fibrillation. *JAMA* 2003; **290**: 2685–92.
8. Mant J, Hobbs FD, Fletcher K, Roalfe A, Fitzmaurice D, et al. Warfarin versus aspirin for stroke prevention in an elderly community population with atrial fibrillation (the Birmingham Atrial Fibrillation Treatment of the Aged Study, BAFTA): a randomised controlled trial. *Lancet* 2007; **370**: 493–503.
9. Guidelines for manegement of anticoagulant and antiplatelet therapy in cardiovascular disease (JCS 2004). *Circ J* 2004; **68** (Suppl IV): 1153–219. (in Jpse.)
10. Yamaguchi T. Optimal intensity of warfarin therapy for secondary prevention of stroke in patients with nonvalvular atrial fibrillation: a multicenter, prospective, randomized trial. Japanese Nonvalvular Atrial Fibrillation-Embolism Secondary Prevention Cooperative Study Group. *Stroke* 2000; **31**: 817–21.
11. Koyama T, Funai S, Nishimura K, Kanno M, Abe H, et al. Acute arterial obstruction of the upper extrimities. *Jpn J Vasc Surg* 2000; **9**: 479–83. (in Jpse. with Engl. abstr.)
12. Puma JA, Haq SA, Sacchi TJ. Acute upper extremity arterial occlusion: a novel role for the use of rheolytic thrombectomy and intravascular ultrasound. *Catheter Cardiovasc Interv* 2005; **66**: 291–6.
13. Johnson SP, Durham JD, Subber SW, Gordon M, Rutherford R, et al. Acute arterial occlusions of the small vessels of the hand and forearm: treatment with regional urokinase therapy. *J Vasc Interv Radiol* 1999; **10**: 869–76.
14. Becqemin JP, Kovarsky S. Atrial emboli of the lower limbs: analysis of risk factors for mortality and amputation. Association Universitaire de Recherche en Chirurgie. *Ann Vasc Surg* 1995; **9** (Suppl): S32–8.