Original Article

After Omental Flap Transposition, Respiratory Function and Exercise Capacity Decrease

Nobuo Morotomi, MD,[1,2] Masakazu Saitoh, MS,[1] Shuichiro Takanashi, MD,[1] Masatoshi Nagayama, MD, PhD,[1] and Masazumi Mizuma, MD, PhD[2]

Purpose: To evaluate the effect of respiratory function and exercise capacity after omental flap transposition

Methods: From October 2005 to December 2006, we classified mediastinitis patients treated with omental flap transposition (OT group; n = 10) and patients who underwent only cardiovascular surgery without developing complications (control group; n = 25). Percent vital capacity (%VC) was evaluated from the day of returning to the general ward for 5 consecutive days and on 14 days. The day of a 200 m walk was investigated, and the cardiopulmonary exercise test was conducted after discharge. Load and oxygen consumption (VO_2) at anaerobic threshold (i.e., AT load and AT VO_2), peak load, and peak VO_2 were measured.

Results: %VC significantly decreased in the OT group compared with the control group ($P < 0.05$). An interaction effect between the 2 groups on the change in %VC was observed ($F = 2.71$, $P < 0.05$). Three patients failed to accomplish a 200 m walk in the ward after omental flap transposition. AT VO_2 and peak VO_2 were significantly lower ($P < 0.05$ and $P < 0.01$, respectively) in the OT group than in the control group.

Conclusion: After omental flap transposition, %VC and VO_2 decreased. (Ann Thorac Cardiovasc Surg 2010; 16: 9–15)

Key words: mediastinitis, omental flap transposition, respiratory function, exercise capacity

Introduction

Complications of cardiovascular surgery include arrhythmia,[1)] cerebral infarction,[2)] postoperative infection,[3)] and respiratory dysfunction.[4)] In particular, postoperative infectious mediastinitis (mediastinitis) is one of the severe complications.[5)] Mediastinitis is inflammation of the mediastinal cavity caused by bacterial infection after midline sternal incision. Treatments include wash drainage, omental flap transposition (OT), major pectoral muscle transposition, and, as a recently developed treatment, continuous vacuum aspiration.[6,7)] OT is a procedure in which the sternum is initially removed, the mediastinal space is washed, and gastric omentum is then placed in the space. This technique has greatly reduced mortality from mediastinitis, compared with only wash drainage, and has become widely used for mediastinitis.[8–10)]

Respiratory dysfunction is also recognized as a complication of cardiovascular surgery.[4)] Such factors as lying in a supine position while positive pressure ventilation is supplied by a ventilator during general anesthesia[11)] and capillary-alveolar membrane permiability[12)] is being increased cause a decrease in functional residual capacity, resulting in pulmonary atelectasis and oxygenation disorders. Vital capacity (VC) also decreases after cardiovascular surgery,

From [1]Sakakibara Heart Institute and [2]Department of Rehabilitation Medicine, Showa University Hospital, Tokyo, Japan

Received July 8, 2008; accepted for publication November 26, 2008

Address reprint requests to Nobuo Morotomi, MD: Department of Rehabilitation Medicine, Showa University Hospital, 1–5–8 Hatanodai, Shinagawa-ku, Tokyo 142–8666, Japan.

approximately 48% before surgery on the day following the operation and 81% even at postoperative day 14.[13)]

The development of mediastinitis will cause further increase in vascular permeability, resulting in persistent respiratory dysfunction. Removal of the sternum before OT will cause a marked decrease in thoracic compliance, resulting in a further decrease in postoperative VC.

In this study, we compared changes in respiratory function after OT with those after cardiovascular surgery. We also investigated respiratory complications and the progress of postoperative rehabilitation.

Subjects

Clinical variables investigated

From a total of 789 patients who underwent midline sternal incision for cardiovascular surgery at the Sakakibara Heart Institute from October 2005 to December 2006, fourteen developed mediastinitis and 10 subsequently underwent OT. The 10 patients that resulted in the OT group were as follows: age range 69 ± 7 years; 6 males and 4 females; surgical procedures performed prior to OT included coronary artery bypass surgery in 4, mitral valve replacement in 1, mitral valve plasty in 2, aortic arch replacement in 1, and complex surgery in 2. The 2 undergoing complex surgery included a coronary artery bypass combined with mitral and aortic valve replacements in and aortic valve replacement and mitral valve plasty in the other. The remaining 4 patients underwent wash drainage. Of those who underwent cardiovascular surgery during the same period and completed postoperative rehabilitation without developing complications, 25 patients who provided informed consent to participate in this study were included in the control group, as follows: age range 64 ± 12 years; 19 males and 6 females; surgical procedures included coronary artery bypass surgery in 11, mitral valve replacement in 1, mitral valve plasty in 5, aortic valve replacement in 5, and other types in 3.

Mediastinitis was given as a diagnosis when all of the following criteria were met: clinical findings of wound redness, sternal instability, pain and high body temperature (38°C or higher); a laboratory test finding of increased white blood cell count (12,000/μl or higher); and a chest computed tomography (CT) finding of abscess retention at the lower part of the sternum. After OT was completed, for at least 2 weeks drains were placed in the anterior and posterior regions of the omentum, under the right and left major pectoral muscles, under the pericardial sternum, and in the right and left thoracic cavities. In postoperative rehabilitation, patients were instructed to walk rehabilitation on the day they returned to the general ward, and the walking distance was then increased to 50, 100, 200, and up to 400 m.

Methods

The following patient characteristics were investigated from the medical records: age, sex, body mass index (BMI), surgical procedure, diabetic mellitus, left ventricular ejection fraction (LVEF), medication, operation time, anesthesia time, aortic clamp time, extracorporeal time, days to extubation, days of intensive care unit (ICU) stay, days to 200 m walking, duration of hospitalization. Furthermore, pathogens, days to diagnosis of mediastinitis, days to reoperation, operation time and anesthesia time of OT, days to extubation, days of ICU stay, days to 200 m walking, and outcome in patients undergoing OT were assessed. The presence or absence of plural effusion, atelectasis, and pneumonia before and after OT was also evaluated by chest CT, and interpretations of all chest CT images were performed by a radiologist who was not informed of the purpose of the study. Respiratory function was evaluated by measuring percent vital capacity (%VC) with a spirometer for 5 consecutive days from the day of transfer from ICU to the general ward and on 2 weeks postsurgery, and recovery of respiratory function was thereafter assessed. Visual analog scale (VAS) was also measured simultaneously for evaluation of postoperative pain. The cardiopulmonary exercise test (CPET) was performed at discharge to measure load at the anaerobic threshold (AT load), oxygen uptake at the anaerobic threshold (AT VO_2), maximum load (peak load), and maximum oxygen uptake (peak VO_2).

Respiratory function test

The respiratory function test was performed using an electronic spirometer (MICROSPIRO, Chest M.I., Inc., Tokyo, Japan). During measurement, patients were asked to sit in an upright position with their nasal cavities fixed with a clip. Forced vital capacity from the maximum inspiration to the maximum expiration was measured, and %VC was calculated and used for analysis. An explanation of the procedure was provided before measurements, and the highest values obtained from 2 measurements were adopted.[14,15)]

Visual analog scale

Patients were asked to indicate the intensity of pain they

Table 1. Patient characteristics

	OT group	Control group	P value
Age (y)	69 ± 7	64 ± 12	
Sex (M/F)	6/4	19/6	
BMI (kg/m^2)	23.6 ± 3.3	22.2 ± 2.7	
Surgical procedure (%)			
CABG	40	40	
MVP	20	16	
MVR	10	4	
AVR	0	20	
TAR	10	0	
DVR	10	0	
CABG + DVR	10	0	
CABG + MVP	0	8	
ASD closure	0	12	
Diabetes mellitus (%)	40	16	
LVEF (%)	53.4 ± 14	62.2 ± 9.5	<0.05
Medication (%)			
β-blocker	70	64	
Ca-blocker	40	20	
ACEI/ARB	30	40	
Operation time (min)	301 ± 72	256 ± 64	
Anesthesia time (min)	345 ± 73	302 ± 66	
Aortic cramp time (min)	117 ± 49	101 ± 32	
Extracorporeal time (min)	171 ± 52	131 ± 40	
Extubation (days)	2 ± 2	1 ± 1	<0.01
ICU stay (days)	3 ± 2	2 ± 1	<0.01
200 m walking (days)	6 ± 3	4 ± 1	<0.01
Duration of hospitalization (days)	40 ± 20	13 ± 3	<0.01

OT, omental flap transposition; M, male; F, female; BMI, body mass index; CABG, coronary artery bypass graft; MVP, mitral valve plasty; MVR, mitral valve replacement; AVR, aortic valve replacement; TAR, total aortic arch replacement; DVR, double valve replacement; ASD, atrial septal defect; LVEF, left ventricular ejection fraction; ACEI, angiotensin-converting enzyme inhibitor; ARB, angiotensin receptor blocker; ICU, intensive care unit.

felt at the time of evaluation on a 100 mm line with 0 points (no pain) on the left end and 10 points (most intense pain) on the right end, and the distance to the indicated point was measured and used for analysis.[16)]

Cardiopulmonary exercise test

Using a cycle ergometer (Rehcor500, Lode, Groningen, the Netherlands), a symptom-limited exercise was performed with a 4 min warm-up at 20 W followed by ramp load at 10 W/min. Expired gas was analyzed (AE300S, Minato Medical Science Co., Ltd., Osaka, Japan) on a breath-by-breath basis.[17)]

Statistical analysis

A comparison of patient characteristics was performed using the unpaired t-test and χ^2 test. A comparison of respiratory function parameters and VAS between the 2 groups was performed using two-way analysis of variance. Each measured value was expressed as mean ± standard deviation (SD), and the significance level was set at 5%. All statistical analyses were performed using SPSS ver11.0J (SPSS Inc., Chicago, IL, USA).

Results

Patient characteristics are shown in Table 1. No significant differences in age, sex, BMI, diabetes mellitus, medications, operation time, anesthesia time, aortic clamp time, or extracorporeal time were found between the OT and control groups. LVEF was significantly lower in the OT group than in the control group (P <0.05). Days to extubation and ICU stay were significantly more delayed in the OT group than in the control group (P <0.01 and P <0.01, respectively). Two hundred meters walking and duration of hospitalization were significantly more delayed in the OT group than in the control group (P <0.01 and P <0.01,

Table 2. Clinical background after omental flap transposition in OT group

Pathogens	
MRSA	2
MSSA	7
Staphylococcus epidermidis	1
Diagnosis (days)	14 ± 5
Reoperation (days)	19 ± 7
Operation time (min)	171 ± 33
Anesthesia time (min)	218 ± 41
Extubation (days)	1 ± 1
ICU stay (days)	3 ± 1
200 m walking (days)	6 ± 3
Outcome	
Discharge	10
Transfer	0
Death	0

MRSA, methicillin-resistant *Staphylococcus aureus*; MSSA, methicillin-sensitive *Staphylococcus aureus*; ICU, intensive care unit.

Table 3. Chest CT findings before and after omental flap transposition

	Preoperation	Postoperation
Chest CT		
Pleural effusion		
Unilateral	3	2
Bilateral	7	8
Nothing	0	0
Atelectasis		
Unilateral	3	5
Bilateral	3	4
None	4	1
Pneumonia	0	0

respectively).

Clinical backgrounds in the OT group are shown in Table 2. All bacteria causing the mediastinitis were found to be *Staphylococci*. The mean day to diagnosis of mediastinitis was 14 ± 5 days. With no cases of early in-hospital death, all patients were discharged from the hospital, though 3 who had undergone OT were unable to walk in the ward.

Pre- and postoperative chest CT findings of patients in the OT group are shown in Table 3. Chest CT performed before OT demonstrated pleural effusion in all patients, of which 6 showed physical atelectasis because of retention of pleural effusion. It was still observed in all patients and atelectasis was observed in 9 patients postsurgery.

Changes in percent VC (%VC) in the OT and control groups are shown in Fig. 1. An interaction effect was found in the change in %VC between the 2 groups ($F = 2.71$, $P < 0.05$).

Changes in VAS in the OT and control groups are shown in Fig. 2. No main effect of postoperative clinical course on the change in VAS was observed either in the OT or control group. Neither was interaction effect found in VAS between the 2 groups.

Measured values of oxygen uptake and exercise load in CPET are shown in Figs. 3 and 4, respectively. AT VO_2, AT load, and peak VO_2 were significantly lower in the OT group than in the control group ($P < 0.05$, $P < 0.05$, and $P < 0.01$, respectively).

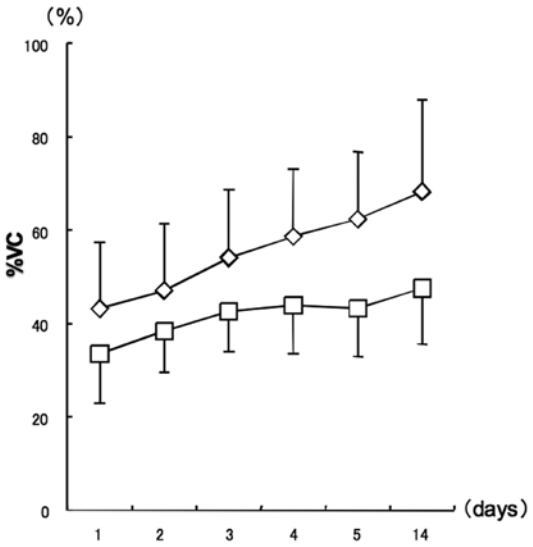

Fig. 1. Changes in percent vital capacity (%VC).
Squares denote the OT group and diamonds the control group.

Discussion

In a study by Krabatsch, the incidence of mediastinitis after cardiovascular surgery was 1.9%, and the 5-year survival after OT was 82.1%.[18] In a study by Loop et al., mediastinitis occurred in 1.1% of patients, 26% of whom underwent OT or major pectoral muscle transposition for treatment of mediastinitis and 14% of whom died while they were in the hospital.[5] The incidence of mediastinitis at our hospital is consistent with those in the preceding studies. The period of days to diagnosis in the present study was also similar to those in the preceding studies, and mortality was lower in the present study. Reported determining factors for mediastinitis include LVEF < 30%,[19] pro-

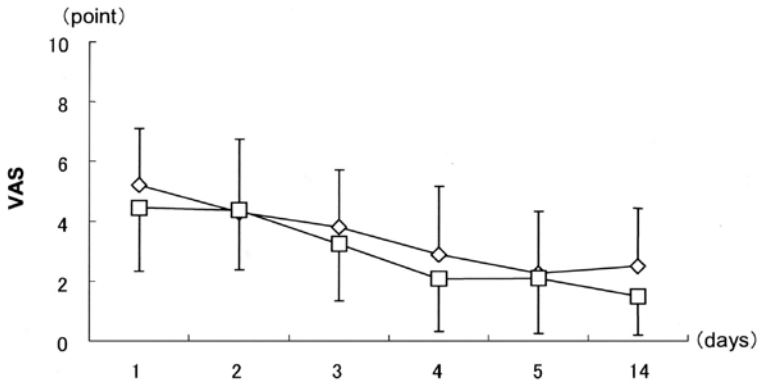

Fig. 2. Changes in pain score (VAS).
Squares denote the OT group and diamonds the control group.

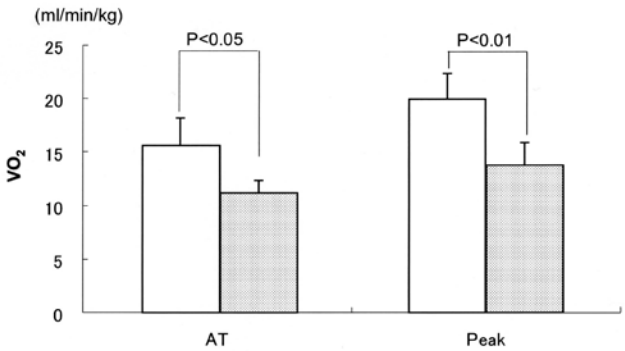

Fig. 3. Peak oxygen consumption (VO_2) and VO_2 at anaerobic threshold (AT) measured by cardiopulmonary exercise test at discharge.
Open bars represent the control group and shaded bars the OT group.

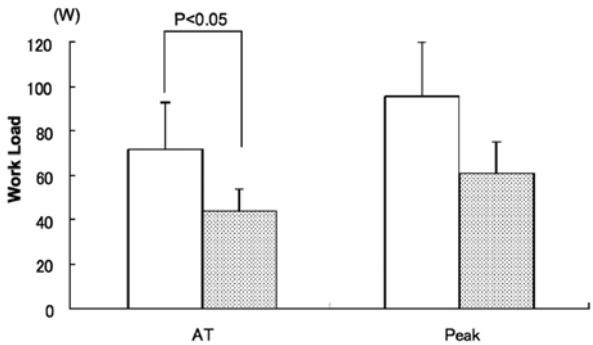

Fig. 4. Peak work load and work load at anaerobic threshold (AT) measured by cardiopulmonary exercise test at discharge.
Open bars represent the control group and shaded bars the OT group.

longed artificial respiratory management,[20] and prolonged stay in ICU,[21] which were also applicable to patients who developed mediastinitis in the present study. With regard to bacteria causing inflammation, *Staphylococci* have been reported to be the causative bacteria in 75% of patients who developed mediastinitis in a study by Yasuura et al.,[22] 84% in a study by Krabatsch and Hetzer,[18] and 71% in a study by Eklund et al.[23] In the present study, all bacteria causing inflammation were found to be *Staphylococci* in all patients, which is consistent with the preceding studies.

%VC after cardiovascular surgery has been reported to be 66% of the %VC before surgery at 2 weeks after coronary artery bypass surgery in a study by Braun et al.,[24] and 56% at 4 days postsurgery in a study by Jenkins et al.[25] In the present study, %VC in the control group was consistent with those in the preceding studies, though the OT group showed an apparent delay in the recovery of %VC.

Possible causes of the delay in the recovery of %VC in the OT group include (a) postoperative wound pain; (b) atelectasis because of retention of pleural effusion; (c) delay in postoperative rehabilitation, all mediastinitis-related factors; (d) decrease in thoracic compliance resulting from removal of the sternum; (e) exacerbation of pleural effusion retention and atelectasis, which are both OT-related factors.

(1) Postoperative wound pain has been reported as a possible cause of respiratory depression and also of a shallow and frequent breathing pattern.[26] We thus expected that inflammatory pain caused by mediastinitis would further exacerbate wound pain and affect respiratory function. However, the change in VAS in the OT group

did not significantly differ from that in the control group, indicating a minor impact of pain on the decrease in %VC.

(2) Development of atelectasis because of plural effusion, retention of pleural effusion, and atelectasis were observed on chest CT before OT and were further exacerbated during postsurgery in the OT group. Postoperative infection causes an increase in vascular permeability and subsequent pleural effusion, which subsequently causes atelectasis and oxygenation dysfunction.[10] In this study, retention of pleural effusion resulting from mediastinitis had been present before OT was performed, which might have affected the decrease in %VC. Moreover, since patients in the OT group were subjected to prolonged artificial respiratory management after cardiovascular surgery, it was speculated that positive pressure ventilation with a ventilator and diffuse lower lung damage caused by prolonged bed rest were also involved in the development of atelectasis.

(3) Concerning delay in postoperative rehabilitation, it resulted when patients had shortness of breath and dyspnea because of the decrease in %VC and the development of atelectasis caused by the above-mentioned reasons. We speculate that this prevented pleural effusion from being absorbed, thereby causing persistent atelectasis.

(4) Regarding a decrease in thoracic compliance resulting from the removal of the sternum, we speculate that the decrease in thoracic compliance caused restrictive impairment in the thoracic cage, which thereby exacerbated the decrease in %VC.

(5) In regard to exacerbated pleural effusion retention, although it is important to allow the lung to expand sufficiently in the early stage after cardiovascular surgery,[26] sufficient expansion of the thoracic cage could not be obtained because of absence of the sternum in the OT group. This made patients unable to take a deep breath or to cough effectively, resulting in persistent atelectasis. We speculate that a vicious cycle of delayed recovery of %VC was produced by the above-mentioned process.

The CPET performed at discharge revealed an apparent decrease in exercise capacity in the OT group. We speculate that the difficulty in continuing postoperative rehabilitation resulted in the decrease in exercise capacity in the OT group.

Takahashi et al. have mentioned that the occurrence of respiratory complications have recently been reduced by shortened operation time and improved medical devices; therefore they do not account for delay in the progress of postoperative rehabilitation.[27] However, we have demonstrated that in patients who have developed mediastinitis after cardiovascular surgery and underwent OT, a retention of pleural effusion and atelectasis caused by mediastinitis and a decrease in thoracic compliance resulting from the removal of the sternum have made it difficult for them to perform respiratory physical therapies such as deep breathing and coughing. These patients will also experience a marked decrease in %VC and delay in the recovery of %VC. Delay in postoperative rehabilitation may also cause a decrease in exercise capacity.

One of the limitations of the present study is that the absolute number of subjects is small because only patients who developed mediastinitis as a postoperative complication were included in the study. Another limitation is that the comparison between the OT and control groups is not strict because patients in the OT group underwent thoracotomy twice during a short period, but those in the control group were subjected to this operation only once. It is important in the future to increase the number of patients and to conduct studies, including not only patients treated with OT, but also those treated with major pectoral muscle transposition or wash drainage, and then compare these patient groups. In this study, although a decrease in thoracic compliance was suspected to be a cause of the decrease in %VC, we were unable to perform sufficient investigation to further clarify this matter. It is also necessary to examine the extent of difference between the thoracic compliance of patients in the control group and that of patients in the OT group by such methods as measuring the circumference of the thoracic cage and three-dimensional motion analysis. How the decrease in thoracic compliance affects respiratory function should also be examined. Further, although the present study investigated short-term changes in respiratory function after OT and also the effects of these changes, only a few studies have investigated long-term follow-up. Especially, reports on the effects of postoperative rehabilitation after OT are extremely limited. As we mentioned above, patients in the OT group showed a decrease in %VC and a resulting decrease in exercise capacity. We need to continue investigations on how %VC changes by respiratory muscle training and continuous aerobic exercise and how changes in %VC affect exercise capacity.

References

1. Aranki SF, Shaw DP, Adams DH, Rizzo RJ, Couper GS, et al. Predictors of atrial fibrillation after coronary artery surgery. Current trends and impact on hospital resources. *Circulation* 1996; **94**: 390–7.
2. Salazar JD, Wityk RJ, Grega MA, Borowicz LM, Doty JR, et al. Stroke after cardiac surgery: short-and long-

term outcomes. *Ann Thorac Surg* 2001; **72**: 1195–202.
3. De Feo M, Gregorio R, Della Corte A, Marra C, Amarelli C, et al. Deep sternal wound infection: the role of early debridement surgery. *Eur J Cardiothorac Surg* 2001; **19**: 811–6.
4. Toyota A, Hiramatsu K, Kanazawa I, Fujimura T, Toba K. Pulmonary rehabilitation and the change of pulmonary function after surgery. *Jpn J Rehabil Med* 2001; **38**: 769–74.
5. Loop FD, Lytle BW, Cosgrove DM, Mahfood S, McHenry MC, et al. J. Maxwell Chamberlain memorial paper. Sternal wound complications after isolated coronary artery bypass grafting: early and late mortality, morbidity, and cost of care. *Ann Thorac Surg* 1990; **49**: 179–86.
6. Dickie SR, Dorafshar, Dorafshar AH, Song DH. Definitive closure the infected median sternotomy wound: a treatment algorithm utilizing vacuum-assisted closure followed by rigid plate fixation. *Ann Plast Surg* 2006; **56**: 680–5.
7. Norris SO. Managing postoperative mediastinitis. *J Cardiovasc Nurs* 1989; **3**: 52–65.
8. Lee AB Jr, Schimert G, Shaktin S, Seigel JH. Total excision of the sternum and thoracic pedicle transposition of the greater omentum; useful stratagems in managing severe mediastinal infection following open heart surgery. *Surgery* 1976; **80**: 433–6.
9. Greig AV, Geh JL, Khanduja V, Shibu M. Choice of flap for the management of deep sternal wound infection —an anatomical classification. *J Plast Reconstr & Aesthet Surg* 2007; **60**: 372–8.
10. Gårdlund B, Bitkover CY, Vaage J. Postoperative mediastinitis in cardiac surgery—microbiology and pathogenesis. *Eur J Cardiothorac Surg* 2002; **21**: 825–30.
11. Morimoto S, Takeuchi N, Imanaka H, Nishimura M, Takezawa J, et al. Gravity-dependent atelectasis. Radiologic, physiologic and pathologic correlation in rabbits on high-frequency oscillation ventilation. *Invest Radiol* 1989; **24**: 522–30.
12. Nakos G, Tsangaris H, Liokatis S, Kitsiouli E, Lekka ME. Ventilator-associated pneumonia and atelectasis: evaluation through bronchoalveolar lavage fluid analysis. *Intensive Care Med* 2003; **29**: 555–63.
13. Takahashi T, Arizono S, Kumamaru M, Nara I, Adachi H, et al. Recovery of vital capacity after cardiac surgery: recovery trend and the effectiveness of incentive spirometry. *J Jpn Phy Ther Assoc* 2003; **30**: 335–42. (in Jpse.)
14. Despopoulos A, Silbernagel S. Color Atlas of Physiology 5th ed. Completely revised and expanded, First Japanese edition 2005. Medical Sciences International: Tokyo, 2005; pp 106–9.
15. Hughes JMB, Pride NB. Lung function tests: physiological principles and clinical applications. First Japanese edition 2004. Medical Sciences International: Tokyo, 2004; pp 3–24.
16. Scott J, Huskisson EC. Graphic representation of pain. *Pain* 1976; **2**: 175–84.
17. Wasserman K, Hansen JE, Sue DY, Whipp BJ, Casaburi R. In: Principles of Exercise Testing and Interpretation, 2nd ed. Lea & Febiger, Philadelphia 1994; pp 117–9.
18. Krabatsch T, Hetzer R. Poststernotomy mediastinitis treated by transposition of the greater omentum. *J Card Surg* 1995; **10**: 637–43.
19. Ivert T, Lindblom D, Sahni J, Eldh J. Management of deep sternal wound infection after cardiac surgery—Hanuman syndrome. *Scand J Thorac Cardiovasc Surg* 1991; **25**: 111–7.
20. Serry C, Bleck PC, Javid H, Hunter JA, Goldin MD, et al. Sternal wound complications. Management and results. *J Thorac Cardiovasc Surg* 1980; **80**: 861–7.
21. Bryan AJ, Lamarra M, Angelini GD, West RR, Breckenridge IM. Median sternotomy wound dehiscence: a retrospective case control study of the risk factors and outcome. *J R Coll Sur Edinb* 1992; **37**: 305–8.
22. Yasuura K, Okamoto H, Morita S, Ogawa Y, Sawazaki M, et al. Results of omental flap transposition for deep sternal wound infection after cardio vascular surgery. *Ann Surg* 1998; **227**: 455–9.
23. Eklund AM, Lyytikäinen O, Klemets P, Huotari K, Anttila VJ, et al. Mediastinitis after more than 10,000 cardiac surgical procedures. *Ann Thorac Surg* 2006; **82**: 1784–9.
24. Braun SR, Brinbaum ML, Chopra PS. Pre-and postoperative pulmonary function abnormalities in coronary artery revascularization surgery. *Chest* 1978; **73**: 316–20.
25. Jenkins SC, Soutar SA, Forsyth A, Keates JR, Moxham J. Lung function after coronary artery surgery using the internal mammary artery and the saphenous vein. *Thorax* 1989; **44**: 209–11.
26. Tsuji T. Respiratory physical for thoracic and abdominal surgery. *J Clin Rehab* 2003; **12**: 408–15.
27. Takahashi T, Jenkins S, Adachi H, Kaneko T, Kumamaru M, et al. The effectiveness of early chest physiotherapy for patients after coronary artery bypass graft surgery. *J Jpn Phys Ther Assoc* 2001; **28**: 31–7. (in Jpse.)