Case Report

Successful Surgical Treatment of Tricuspid Valve Endocarditis Associated with Vertebral Osteomyelitis

Kenji Aoki, MD, Maya Watanabe, MD, and Hajime Ohzeki, MD

Right-sided endocarditis is relatively rare and can occasionally be complicated by vertebral osteomyelitis (VO). We describe successful treatment, including valve repair for tricuspid endocarditis associated with VO. A 77-year-old man presented with back pain and high fever. Magnetic resonance imaging demonstrated VO. Despite 2 months of intravenous antibiotics, the infectious signs persisted and both legs became edematous. Enterococcus faecalis was isolated from blood cultures, and echocardiography showed severe tricuspid regurgitation with large vegetations attached to the anterior leaflet (AL). A series of echocardiographic assessments revealed that the antibiotic therapy did not affect the tricuspid lesions. In surgery, the infection was extended to some chordae and over half of the AL was resected. The AL was repaired with autologous pericardium and artificial chordae. Antibiotic therapy was continued for 2 months after surgery, and the infections did not reoccur. Follow-up echocardiography showed mild regurgitation of the tricuspid valve. The patient remains free from endocarditis at 2 years after surgery. (Ann Thorac Cardiovasc Surg 2010; 16: 207–209)

Key words: tricuspid endocarditis, vertebral osteomyelitis, valve repair

Introduction

Right-sided endocarditis (RSE) is very rare in patients with no history of drug abuse. Most endocarditis can be treated successfully with antibiotics, though surgery is indicated for some special circumstances. Vertebral osteomyelitis (VO) is a rare complication that can arise in patients with infective endocarditis and has the potential to be lethal. We describe successful treatment including valve repair in a patient with tricuspid endocarditis (TE) and VO.

From Department of Cardiovascular Surgery, Niigata Prefectural Shibata Hospital, Shibata, Niigata, Japan

Received December 26, 2008; accepted for publication March 3, 2009
Address reprint requests to Kenji Aoki, MD: Department of Cardiovascular Surgery, Niigata Prefectural Shibata Hospital, 1–2–8 Honcho, Shibata, Niigata 957–8588, Japan.

Case Report

A 77-year-old man with a 10-year-history of diabetes mellitus presented with back pain and high fever. Magnetic resonance imaging demonstrated VO in L2 and L3 (Fig. 1). The leukocyte count was $15.6 \times 10^3/mm^3$, and the C-reactive protein level was 10.5 mg/dl. Antibiotic therapy with sulbactam sodium and ampicillin sodium (6 g/day) was initiated, and the backbone was stabilized using a plastic jacket. The antibiotics were continued for 2 months, but fever developed and both legs became insidiously edematous. *Enterococcus faecalis* was isolated in blood cultures. Imipenem hydrate/cilastatin sodium (1 g/day) was administered based on the findings of the disc sensitivity test. Echocardiography demonstrated severe tricuspid regurgitation with two large vegetations measuring 2.0 × 1.7 and 1.6 × 1.1 cm attached to the anterior leaflet (AL). A second course of antibiotics was administered for 1 month, and the patient became afebrile. However, the vegetations and valve incompetence persisted according to a series of echocardiographic assessments.

Surgery for the TE revealed remarkably degenerated AL

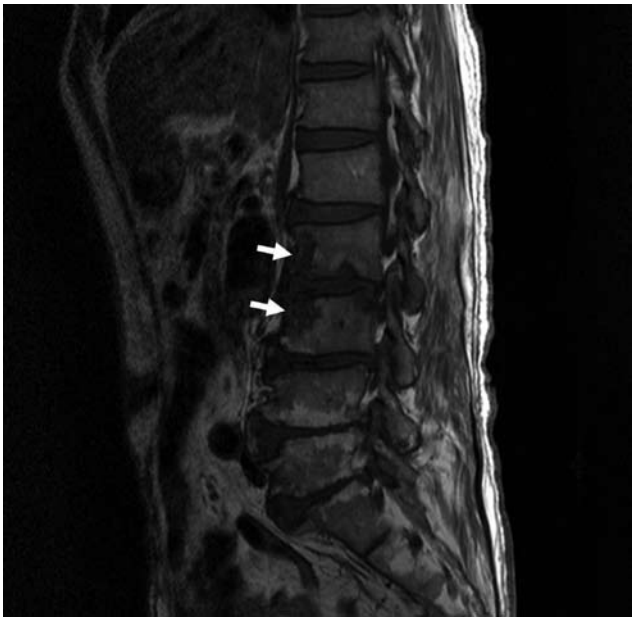

Fig. 1. Magnetic resonance imaging of spine.
L2 and L3 destruction is evident (arrow).

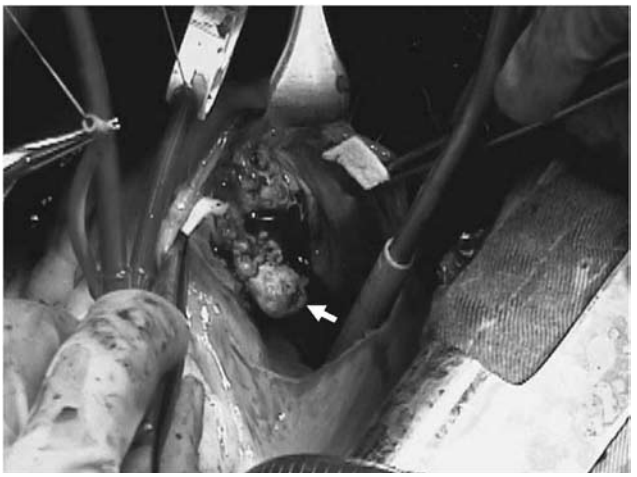

Fig. 2. Intraoperative view. Large vegetations (arrow) are attached to anterior leaflet of tricuspid valve.

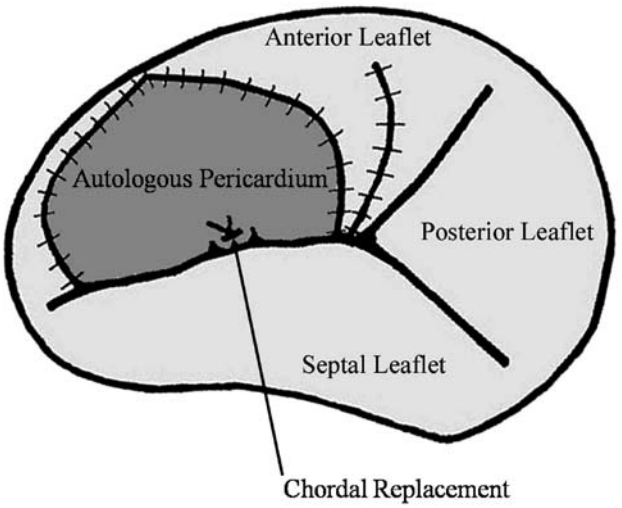

Fig. 3. Schema of tricuspid valve repair.
The larger defect was repaired with autologous pericardium, and the other was directly sutured. Prolapse of the repaired leaflet was corrected by chordal replacement.

(Fig. 2). The infected tissue with the larger vegetation was extended widely near the anteroseptal commissure, and some chordae were embroiled. The other vegetation was attached near the anteroposterior commissure. The other leaflets were intact. The infected tissues, including degenerated chordae, were completely excised; the larger of two defects equivalent to half of the AL was repaired with autologous pericardium, and the other was directly sutured. The water injection test demonstrated prolapse of the patched pericardium. The chordae were replaced with a 5–0 expanded polytetrafluoroethylene suture, and leaflet coaptation was restored (Fig. 3). Intraoperative transesophageal echocardiography showed mild regurgitation after the valve repair.

The second antibiotic therapy was continued for another month after surgery, and VO was successfully controlled with conservative therapy. Diabetes was strictly managed with insulin throughout the perioperative period. The patient was discharged on postoperative day 34. Warfarin was administrated for the first 3 months after surgery. Leukocyte count and C-reactive protein level were checked every 2 months for the first year, and no relapse signs for the infection were found. Follow-up echocardiography was performed every 6 months, and the repaired valve functioned well with no changes of regurgitation under semiquantitative assessment. The patient has remained free of endocarditis for 2 years since the surgery.

Discussion

Vertebral osteomyelitis coexists in only 5% of patients with infective endocarditis (IE).[1,2] However, in-hospital mortality is high (25%) when IE is accompanied by VO.[1] Most reports of IE accompanied by VO describe left-sided endocarditis or RSE that has been treated medically. We believe that the present report is the first in the English literature to describe a patient who has been successfully treated by surgery for RSE complicated with VO.

RSE accounts for 5% to 10% of all patients with IE.[3] It can

be caused by intravenous drug abuse, other heart diseases, transvenous interventions (such as pacemaker implantation), and long-term central venous catheters.[4,5] Antibiotics can resolve 70% to 80% of RSE,[4–6] but surgery is indicated for persistent infection that does not respond to antibiotic therapy, repetitive pulmonary emboli, and intractable heart failure when the size of a vegetation increases or persists at > 1 cm.[4–6]

Successful surgery for TE includes the excision of all infected tissue and the restoration of valve competence.[5,6] The valve should be repaired rather than replaced because of a high incidence of prosthetic valve-related complications including reinfection and thrombosis.[5,6] Small defects localized to one leaflet can be repaired by direct closure with or without annuloplasty.[5,6] Bicuspidization annuloplasty is an option after complete resection of the posterior leaflet.[5,6] However, patch repair is necessary when one major or two minor leaflets are widely excised.[6] Autologous pericardial patches are often applied under such conditions, and simple patch repair provides excellent restoration of valve competence.[6] We also reconstructed the chordae in our patient to correct prolapse of the autologous pericardial patch, which satisfactorily restored valve competence. The repaired valve has functioned well for 2 years without signs of progressive regurgitation.

References

1. Pigrau C, Almirante B, Flores X, Falco V, Rodoriguez D, et al. Spontaneous pyogenic vertebral osteomyelitis and endocarditis: incidence, risk factors, and outcome. *Am J Med* 2005; **118**: 1287.
2. Ninet J, Gayet JL, Etienne J, Bonvoisin B, Vignon E, et al. Bacterial endocarditis presenting as acute vertebral osteomyelitis: 14 cases. *Eur Heart J* 1984; **5** [Suppl C]: 101–5.
3. Nandakumar R, Raju G. Isolated tricuspid valve endocarditis in nonaddicted patients: a diagnostic challenge. *Am J Med Sci* 1997; **314**: 207–12.
4. Bayer AS, Blomquist IK, Bello E, Chiu CY, Ward JY, et al. Tricuspid valve endocarditis due to Staphylococcus aureus. Correlation of two-dimensional echocardiography with clinical outcome. *Chest* 1988; **93**: 247–53.
5. Carozza A, Renzulli A, De Feo M, Ismeno G, Della Corte A, et al. Tricuspid repair for infective endocarditis: Clinical and echocardiographic results. *Tex Heart Inst J* 2001; **28**: 96–101.
6. Gottardi R, Bialy J, Devyatko E, Tschernich H, Czerny M, et al. Midterm follow-up of tricuspid valve reconstruction due to active infective endocarditis. *Ann Thorac Surg* 2007; **84**: 1943–9.