Original Article

Safe Approach for Redo Coronary Artery Bypass Grafting – Preventing Injury to the Patent Graft to the Left Anterior Descending Artery

Hiroyuki Nishi, MD,[1] Masataka Mitsuno, MD,[1] Mitsuhiro Yamamura, MD,[1]
Hiroe Tanaka, MD,[1] Masaaki Ryomoto, MD,[1] Shinya Fukui, MD,[1] Yoshiteru Yoshioka, MD,[1]
Shunichiro Takanashi, MD,[2] and Yuji Miyamoto, MD[1]

Objective: In redo coronary artery bypass grafting (CABG), repeat median sternotomy is a routine approach when the graft to the left anterior descending artery (LAD) is occluded. However, it is important to avoid injury to the patent graft to LAD during repeat sternotomy. We retrospectively reviewed our cases to assess our combined strategy for a safer redo CABG.
Methods: The study group comprised 19 patients (18 men and 1 woman; mean age 67.7 ± 6.9 years) who underwent redo CABG operations from January 2000 to August 2008. All patients had undergone median sternotomy during previous surgery (13 ± 6 years before repeat CABG). Eighteen patients had previous graft occlusion, and 6 had developed new coronary artery disease. Five patients had patent left internal thoracic artery (LITA) and 8 had patent saphenous vein graft (SVG). We attempted to avoid median sternotomy when patients had patent graft to LAD.
Results: Median sternotomy (on-pump cardiac arrest) was performed on 13 patients with occluded graft to LAD. For those with the patent graft to LAD, left thoracotomy (on-pump beating) on 4 patients, and 2 patients underwent off-pump CABG via the subxiphoid approach. The mean number of bypass grafts was 2.6 ± 1.2. Internal thoracic arteries, radial arteries, saphenous vein graft, and gastroepiploic arteries were all selected as conduits. The ascending aorta, descending aorta, and previous SVG graft were used as the proximal anastomosis site. There was no graft injury, and 1 patient died as a result of ventricular tachycardia.
Conclusion: According to the circumstances, conduits and a proximal anastomosis should be selected. For redo CABG patients who have a patent graft to LAD, it is important to choose the optimal approach to avoid injury to the previous patent graft. (Ann Thorac Cardiovasc Surg 2010; 16: 253–258)

Key words: redo coronary artery bypass grafting (CABG), patent graft

Introduction

As operative techniques evolve and survival after cardiac operations improves, the number of patients who have repeat sternotomy inevitably continues to increase. In Japan, redo coronary artery bypass grafting (CABG) has

From [1]Department of Cardiovascular Surgery, Hyogo College of Medicine, Hyogo, Japan, and [2]Department of Cardiovascular Surgery, Sakakibara Heart Institute, Tokyo, Japan

Received March 25, 2009; accepted for publication April 7 2009
Address reprint requests to Yuji Miyamoto, MD: Department of Cardiovascular Surgery, Hyogo College of Medicine, 1–1, Mukogawa cho, Nishinomiya, Hyogo 663–8501, Japan.

gradually increased over the years.[1] Because of the increasing use of bilateral internal thoracic arteries and other arterial conduits, more patients in the future will present for reoperation with a variety of arterial conduits, in addition to saphenous vein grafts (SVG). When coronary reoperation is necessary, the presence of a patent left internal thoracic artery (LITA)-left anterior descending artery (LAD) graft creates specific risks, including the possibility of intraoperative injury to the graft and potential difficulties with myocardial protection[2,3]. Conventional redo CABG via the repeat median sternotomy approach has been associated with increased mortality and morbidity.[4–6] The mortality rate after redo CABG is reported to be more than three times higher than that of primary CABG.[4–7] Injury to a patent LITA-LAD graft at reoperation can have catastrophic consequences.

With recent advances of CABG, various types of approaches have been introduced, such as left thoracotomy[2, 8, 9] and the subxiphoid approach with or without cardiopulmonary bypass.[10] To avoid injury to a patent functional graft to LAD, such as the LITA-LAD graft, we have developed a strategy to select the optimal approach according to the status of patients and grafts. Our study intends to assess our strategy for a safer redo CABG.

Patients and Methods

Study population (Table 1)

This study included 19 patients who had a redo CABG from January 2000 to August 2008 at the Hyogo College of Medicine. The subjects comprised 19 of the 305 patients (6.8%) who had undergone isolated CABG in our institute during that period. Patients who underwent combined valvular or ventricular surgery and those who had combined surgery with major vascular surgery were excluded from this study. The mean age of the patients was 68 ± 7 years (range, 58 to 83); 1 patient (5%) was female. All patients underwent median sternotomy at the previous surgery. There were two second-time operations and one third-time reoperation. The patients' demographics are shown in Table 1. Informed consent was obtained from all patients.

The interval between operations was 13 ± 6 years (the shortest being 1 year and the longest 20 years, 4 months). The reasons for a redo CABG were graft failure in 19 cases and development of a new native coronary artery disease on a nonbypassed coronary artery in 6 (including overlap). During the previous operations, LITA was used in 8 cases and SVG was used in 18 (including overlap).

Table 1. Demographics of the patients

Age (y)	67.4 ± 6.8
75≧yrs	2 (11%)
Gender (male/female)	18/1
Hypertension	13 (68%)
Diabetes	15 (79%)
Hyperlipidemia	13 (68%)
Dialysis	0
Smoking	12 (63%)
Emergent, Urgent	2 (11%)
CCS classes 3,4	9 (47%)
LVEF (%)	49.7 ± 12.3
≦40%	5 (26%)
Preoperative IABP	2 (11%)
No. of diseased vessels	2.2 ± 0.9

LVEF; left ventricular ejection fraction; CSS, Canadian Cardiovascular Society

One patient had a bypass graft with the right gastroepiploic artery (RGEA). Three LITAs were occluded, and there were 5 patent LITA-LAD grafts. There were 54 SVG grafts in the initial operations; 43 of these were occluded or clinically stenosed. One patient had a patent SVG-LAD graft.

Operative technique and choice of procedure

To make a decision on the operative approach and procedure, we considered the presence of a patent graft to the LAD as the most important factor. When there was no patent graft to the LAD, we preferred to choose median sternotomy. Redo sternotomy was performed using an oscillating saw while lifting up the sternal wires. After completing the dissection around the heart, the standard on-pump CABG technique was applied. For patients who have a functional patent graft to LAD and require revascularization for the right coronary artery or the left circumflex artery, we tried to perform percutaneous catheter intervention (PCI) at first. We consider a case as an indication for surgery when it is impossible to complete PCI. When we needed to avoid a repeat sternotomy, we selected an alternative approach, such as left thoracotomy or a subxiphoid incision, according to the patient's circumstances. A cardiopulmonary bypass via the femoral artery and vein was always established in the left thoracotomy technique. On the other hand, standard beating heart principles with RGEA were used for the subxiphoid incision approach. Otherwise, we adapted an on-pump CABG at first when patients had no contraindications for an on-pump CABG.

Table 2. Operative results

	Total	Median	Left thoracotomy	Subxiphoid
No. of distal anastomoses	2.5 ± 1.2	3.0 ± 1.1	1.8 ± 0.5	1.0
1	4	1	1	2
2	6	3	3	–
3	5	5		
4	3	3		
5	1	1		
Operative time (min.)	485 ± 127	527 ± 116	439 ± 103	305 ± 14
CPB time (min.)	162 ± 55	166 ± 60	151 ± 41	–
Cross-clamp time (min.)	102 ± 28	102 ± 28	–	–
Graft injury	none			

No., number.
CPB: cardiopulmonary bypass.

Results

Operative approaches

Repeat median sternotomy was employed in 13 patients who had no patent graft to the LAD. A cardiopulmonary bypass was applied to all repeat median sternotomy patients.

There were four left thoracotomies in 3 patients with patent LITA-LAD and in 1 with SVG-LAD. These patients required no revascularization for the right coronary artery. The on-pump beating heart surgery technique via the femoral artery and vein was used for all left thoracotomy cases. After completion of a proximal anastomosis to the descending aorta, the SVG graft or radial artery graft was led through the pericardium, and a distal anastomosis was performed under stabilization. Two patients who had coronary artery disease on the right coronary artery territory underwent off-pump CABG with RGEA via the subxiphoid approach. These procedures were successfully completed off-pump.

Operative results

The mean number of distal anastomoses was 2.5 ± 1.2 for the total number of cases, and that of median sternotomy patients (3.0 ± 1.1) tended to be larger than that of left thoracotomy (1.8 ± 0.5) or subxiphoid approaches (1.0). Eleven patients (79%) had 3 or more distal anastomoses in median sternotomy cases, and 3 (75%) in the left thoracotomy group had 2 distal anastomoses (Table 2). Internal thoracic arteries, radial arteries, saphenous vein graft, and gastroepiploic arteries were all selected as conduits. The distribution of grafts and onduits is summarized in Table 3. The ascending aorta was used as a proximal anastomosis site in 10 cases, the descending aorta was used in 4, and previous SVGs were used in 3. Other operative data are provided in Table 2.

No graft injuries occurred, including a patent graft to LAD. One patient died as a result of ventricular tachycardia, and 30-day mortality was 5.3%. Three patients had significant postoperative morbidity, such as reexploration for bleeding, a cerebrovascular accident, or deep sternal infection. Perioperative myocardial infarction, documented by new Q waves on the electrocardiogram or by cardiac enzyme levels of more than 250 IU/l, was observed in 3 patients. These were not related to graft occlusion. Four patients (21%) required postoperative new intra-aortic balloon pump (IABP). Other complications are listed in Table 4. Eleven patients were examined for postoperative graft patency with angiography or multislice computed tomography. Postoperative overall graft patency was 93%. There were 4 late deaths (2 sudden deaths, 1 pneumonia, 1 multiple organ failure) during follow-up.

Discussion

A redo CABG provides several technical challenges that distinguish it from primary CABG. These obstacles include repeat sternotomy, injury to previous grafts or the heart during dissection, quality and availability of conduits, a calcified ascending aorta, and more-advanced coronary disease involving the native vessels. As a result, operative morbidity and mortality are increased during a redo CABG, with an operative mortality in most series of reoperations 3 to 5 times that for a primary CABG.[1, 4–7] It is of the utmost importance that this operation be carefully planned. The procurement and study of old operative notes and the assessment of angiography or enhanced computed tomography (CT) can be helpful in this regard.[1,3,11] We always performed preoperative assessment

Table 3. Distribution of conduits

		Number of bypass grafts (Median Sternotomy/Left Thoracotomy/Subxiphoid)				
		Grafts				
		LITA	RITA	RAG	GEA	SVG
Targets	LAD	5 (5/0/0)	4 (4/0/0)	4 (4/0/0)	2 (2/0/0)	6 (5/1/0)
	LCX	2 (2/0/0)	–	2 (1/1/0)	1 (1/0/0)	9 (4/5/0)
	RCA	–	–	–	4 (2/0/2)	7 (7/0/0)

LITA, left internal thoracic artery; RITA, right internal thoracic artery;
RAG, radial artery graft; GEA, gastroepiploic artery;
SVG, saphenous vein graft;
LAD, left anterior descending artery LCX, left circumflex artery;
RCA, right coronary artery

Table 4. Mortality and morbidity

	Total	Median	Left thoracotomy	Subxiphoid
30-day Mortality	1 (5.3%)	0	1	0
Complications				
Postoperative MI	3 (19%)	3	0	0
Reexploration for bleeding	2 (11%)	2	0	0
Cerebral vascular accident	2 (11%)	2	0	0
Deep sternal infection	2 (11%)	2	0	0
Postoperative new IABP	4 (21%)	3	1	0
Late Death	4 (sudden death: 2; pneumonia: 1; MOF: 1)			

MI, myocardium infarction.
IABP, intra-aortic balloon pumping.
MOF, multiple organ failure.

of graft patency and route by angiography and enhanced CT. From these results, we established our strategy for a safer redo CABG, using a combined approach according to the circumstances (Fig. 1). When patients had only one vessel disease in the right coronary artery, off-pump CABG via the subxiphoid approach with right gastroepiploic artery (RGEA) was favorable, and it was the least invasive approach. Thus we adapted this procedure for this situation. When there was no functional graft to the LAD or when patients needed revascularization for three territories, we used the repeat median sternotomy approach. We preferred not to touch this graft in the presence of a patent functional graft to LAD. Therefore, depending on the number and location of coronary artery disease, alternative methods, such as a left thoracotomy or subxiphoid approach, were applied. As a result, there

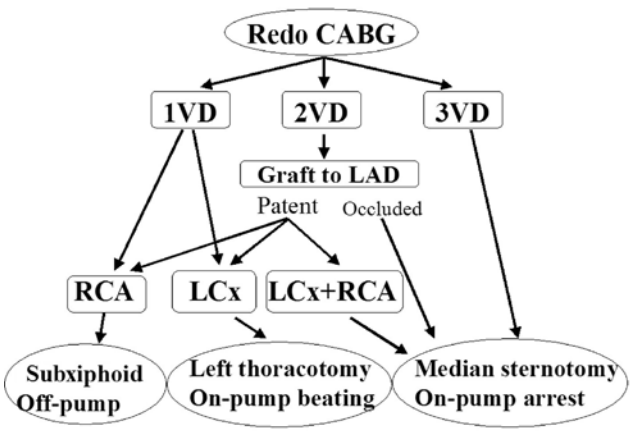

Fig. 1. Our strategy for redo CABG

were no injuries of a patent graft to LAD.

In a redo CABG, one of the most difficult and challenging situations is to dissect the LITA at the time of sternal reentry. Recently, skeletonized LITA have been harvested more and more frequently,[12] which could create more risky and demanding technical problems. The incidence of LITA injury during repeat sternotomy has been reported to range from 5% to 38%.[13,14] A previous report showed that injury to LITA was followed by the evolution of a perioperative infarction in 40% of patients.[2] Moreover, investigators have reported an operative mortality rate as high as 50% when the LITA graft is injured.[15] Although several reports have shown special techniques to avoid injury to LITA at the time of sternal reentry,[16] the best way to elude this catastrophic event is not to choose repeat sternotomy. Although median sternotomy is still required for some patients with a patent graft to LAD, there also exists a patient with a patent graft to LAD adhered to the sternum. It may be dangerous to perform resternotomy and to dissect LITA in this kind of patient. A patent functional graft to the LAD means that the LAD territory is protected. Thus it is reasonable to select an alternative approach for a redo CABG, especially when only the left circumflex artery or the right coronary artery is diseased. In the current study, we adapted alternative approaches when patients with a patent graft to LAD required bypass grafts to either the left circumflex artery (LCX) or the right coronary artery (RCA) territory. However, it might be better to choose median sternotomy when patients with a patent graft to LAD need revascularization for both the LCX and the RCA systems.

The left thoracotomy in a redo CABG has been described as a useful approach for patients requiring revascularization of the left circumflex territory.[8,9,17] The advantages of this procedure are elimination of repeat median sternotomy, minimal dissection around the heart and previous grafts, and no manipulation of the ascending aorta, which could prevent stroke and direct exposure of the target vessels. On the other hand, the most important disadvantage is a limitation of revascularization. Although the possibility of triple vessel revascularization via the left thoracotomy has been reported,[18] we do not consider that the left thoracotomy can be routinely used for grafting to the RCA. We selected this approach only when patients had single-vessel disease of the LCX or two-vessel disease with a diagonal coronary artery territory. It is also important to consider the location of targets, selection of conduits, shape of the patient's chest, and calcification of the descending aorta before choosing this approach. Initially, the left thoracotomy in a redo CABG was introduced under hypothermic cardiopulmonary bypass and ventricular fibrillation.[19] With recent advances in the off-pump CABG technique, this technique has been applied to the left thoracotomy approach.[17] In the present study, we adapted on-pump beating CABG with peripheral cannulation via the femoral artery and vein. We consider this technique easier and safer for preventing catastrophic events, such as perioperative myocardial infarction, especially when a partial clamp of the descending aorta is difficult and patients are unstable. We did not experience hemodynamic instability during the operation via the left thoracotomy.

Revascularization of the right coronary artery via the subxiphoid approach with RGEA is also one of the choices for redo CABG, in which selection of conduits is frequently limited and RGEA is a useful choice for revascularization.[10] The most suitable target is RCA territory. Several reports have shown successful results of off-pump CABG with RGEA via the subxiphoid approach.[10,20] Although some investigators have reported the right thoracotomy approach with the right internal thoracic artery, we consider this approach to be easier because of minimal dissection. As previously reported, almost all cases of this approach can be performed without cardiopulmonary bypass.[10,20] When LAD territory is protected by a patent graft, this situation is safer. If patients have suitable RGEA and targets for the RCA, it is important to recognize the subxiphoid approach as one of the useful methods for redo CABG to the right coronary artery.

The current study has several limitations. First, the numbers in this study are small. Second, we did not compare the results with or without our strategy. Lastly, long-term results are needed to confirm the usefulness of our strategy. The most important finding of this study is that despite the small number of cases, we did not experience injury to a patent functional graft to the LAD. Although other investigators have reported reduced injury to a patent LITA graft via sternotomy (approximately 5%) as a result of careful planning,[2] we believe that the final goal should be no graft injury to a patent graft to the LAD. This fear of injury has resulted in a significant proportion of patients referred for percutaneous intervention when they developed recurrent ischemia after primary CABG with a patent graft to the LAD.[21] To obtain a favorable outcome for these complicated cohorts, it is important for surgeons to consider and to select appropriate approaches on the basis of each patient's situation. Surgeons should have a com-

prehensive approach for redo CABG.

In summary, it is important to choose the optimal approach to avoid injury of the patent graft to LAD for a redo CABG when patients have a patent graft to the LAD. Although careful and long-term follow-up are needed, our strategy could be useful for obtaining improved results for a redo CABG.

References

1. Hirose H, Amano A, Takahashi A, Takanashi S. Redo coronary artery bypass grafting-Early and mid-term results. *Jpn J Thorac Cardiovasc Surg* 2004; **52**: 11–7.
2. Gillinov AM, Casselman FP, Lytle BW, Blackstone EH, Parsons EM, et al. Injury to patent left internal thoracic artery graft at coronary reoperation. *Ann Thorac Surg* 1999; **67**: 382–6.
3. Gasparovic H, Rybicki F, Millstine J, Unic D, Byrne JG, et al. Three dimensional computed tomographic imaging in planning the surgical approach for redo cardiac surgery after coronary revascularization. *Eur J Cardiothorac Surg* 2005; **13**: 244–9.
4. Yau TM, Borger MA, Weisel RD, Ivanov J. The changing pattern of reoperative coronary surgery trends in 1230 consecutive reoperations. *J Thorac Cardiovasc Surg* 2000; **120**: 156–63.
5. Christenson JT, Schmuziger M, Simonet F. Reoperative coronary artery bypass procedure: Risk factors for early mortality and late survival. *Eur J Cardiothorac Surg* 1997; **11**: 129–33.
6. Yamamuro M, Lytle BW, Sapp SK, Cosgrove DM, Loop FD, et al. Risk factors and outcomes after coronary reoperation in 739 elderly patients. *Ann Thorac Surg* 2000; **69**: 464–74.
7. Committee for Scientific, Ueda Y, Fujii Y, Udagawa H. Thoracic and cardiovascular surgery in Japan during 2006: Annual report by the Japanese Association for Surgery. *Gen Thorac Cardiovasc Surg* 2008; **56**: 365–88.
8. Mack MJ. Off-pump surgery and alternatives to standard operation in redo coronary surgery. *J Card Surg* 2004; **19**: 313–9.
9. Shapira OM, Natarajan V, Kaushik S, DeAndrade KM, Shemin RJ. Off-pump versus on-pump reoperative CABG via left thoracotomy for circumflex coronary artery revascularization. *J Card Surg* 2004; **19**: 113–8.
10. Ochi M, Hatori N, Kanno S, Yamada K, Saji Y, et al. Coronary artery bypass grafting without cardiopulmonary bypass: a five-year experience. *J Nippon Med Sch* 2003; **70**: 157–64.
11. Joyce FS, McCarthy PM, Taylor PC, Cosgrove DM, Lytle BW. Cardiac reoperation in patients with bilateral internal thoracic artery grafts. *Ann Thorac Surg* 1994; **58**: 80–5.
12. Pevni D, Uretzky G, Mohr A, Braunstein R, Kramer A, et al. Routine use of bilateral skeletonized internal thoracic artery grafting: long-term results. *Circulation* 2008; **118**: 705–12.
13. Coltharp WH, Decker MD, Lea 4th JW, Petracek MR, Glassford Jr DM, et al. Internal mammary artery graft at coronary reoperation risks, benefits, and methods of preservation. *Ann Thorac Surg* 1991; **52**: 225–8.
14. Bailot RG, Loop FD, Cosgrove DM, Lytle BW. Reoperation after previous grafting with the internal mammary artery. *Ann Thorac Surg* 1985; **40**: 271–3.
15. Elami A, Laks H, Merin G. Technique for reoperative median sternotomy in the presence of a patent left internal mammary artery graft. *J Card Surg* 1994; **9**: 123–7.
16. Follis FM, Pett Jr SB, Miller KB, Wong RS, Temes RT, et al. Catastrophic hemorrhage on sternal reentry: Still a dreaded complication? *Ann Thorac Surg* 1999; **68**: 22215–9.
17. Byrne JG, Aklog L, Adams DH, Cohn LH, Aranki SF. Reoperative CABG using left thoracotomy: A tailored approach. *Ann Thorac Surg* 2001; **71**: 196–200.
18. Iemura J, Oku H, Ohtaki M, Inoue T. Coronary artery bypass grafting following substernal gastric interposition. *Jpn Circ J* 2000; **64**: 404–5.
19. Cheung D, Flemma RJ, Mullen DC, Lepley D Jr. An alternative approach to isolated circumflex coronary bypass reoperations. *Ann thorac Surg* 1982; **33**: 302–3.
20. Kamiya H, Watanabe G, Takemura H, Tomita S, Nagamine H, et al. Skeletonization of gastroepiploic artery graft in off-pump coronary artery bypass grafting: early clinical and angiographic assessment. *Ann thorac Surg* 2004; **77**: 2046–8.
21. Brener SJ, Loop FD, Lytle BW, Ellis SG, Cosgrove DM, et al. A profile of candidates for repeat myocardial revascularization: Implications for selection of treatment. *J Thorac Cardiovasc Surg* 1997; **114**: 153–61.