Case Report

Giant Saccular Aneurysm of Coronary Arteriovenous Fistula to the Main Pulmonary Artery: Intraoperative Assessment by Using Fluorescent Imaging

Ken Nakamura, MD,[1] Kazuaki Shiratori, MD,[1] and Kazuhiro Hashimoto, MD[2]

Coronary arteriovenous fistulas (CAF) and coronary artery aneurysms (CAA) are uncommon, but their detection has recently increased. In this case we succeeded in identifying the residual shunt flow by using an intraoperative fluorescence imaging technique with indocyanine green after surgical treatment. The photodynamic eye imaging system is based on fluorescence of indocyanine green. This is the first report to identify residual shunt flow with such a giant coronary aneurysm by using fluorescence imaging, and the result indicates that this technique is useful for acceptance as one of the examinations to evaluate CAAs. Furthermore, it may be useful for the detection of shunt cases, such as congenital heart disease. (Ann Thorac Cardiovasc Surg 2010; 16: 354–357)

Key words: giant saccular aneurysm, coronary arteriovenous fistula, fluorescence imaging

Introduction

Coronary arteriovenous fistulas (CAF) and coronary artery aneurysms (CAA) are uncommon, but their detection has recently increased because of the widespread use of coronary angiography and multidetector computed tomography (MDCT).[1,2] There are some surgical reports about successful operative strategies, but few have announced the detection of residual shunt after surgical treatment, except for those using transesophageal echocardiography (TEE). We describe a case of a giant saccular aneurysm of coronary arteriovenous fistula to the main pulmonary artery. In this case we succeeded in identifying the residual shunt flow by using an intraoperative fluorescence imaging technique with indocyanine green (ICG) after surgical treatment. The technique is based on the capture, by a charge-coupled device video camera, of fluorescence of ICG when illuminated with near infrared light using laser energy from the photodynamic eye (PDE). This is the first report to identify residual shunt flow with such a giant coronary aneurysm by using fluorescence imaging.

From [1]Department of Cardiovascular Surgery, Saku Central Hospital, Nagano; and [2]Department of Cardiovascular Surgery, The Jikei University School of Medicine, Kashiwa, Japan

Received June 19, 2009; accepted for publication August 3, 2009
Address reprint requests to Ken Nakamura, MD: Department of Cardiovascular Surgery, The Jikei University School of Medicine, Kashiwa Hospital, 163–1 Kashiwashita, Kashiwa City 277–8567, Japan.

Case Presentation

A 62-yr-old woman with hypertension was referred to our hospital because of an abnormal shadow on her chest roentgenogram. She has never recognized such symptoms as chest oppressions and been pointed out of such an abnormal shadow. She reported no history of Kawasaki disease or cardiac trauma. On physical examination, a continuous murmur was audible at the 4th intercostal space. Multidetector row CT revealed a giant coronary artery aneurysm 70 × 45 mm in diameter. Coronary angiography confirmed that the left coronary artery #7 fed into and drained into the main pulmonary artery; the pulm-syst flow ratio (Qp/Qs) is 1.2 (Fig. 1). From these findings, she was found to have a giant saccular aneurysm of coronary

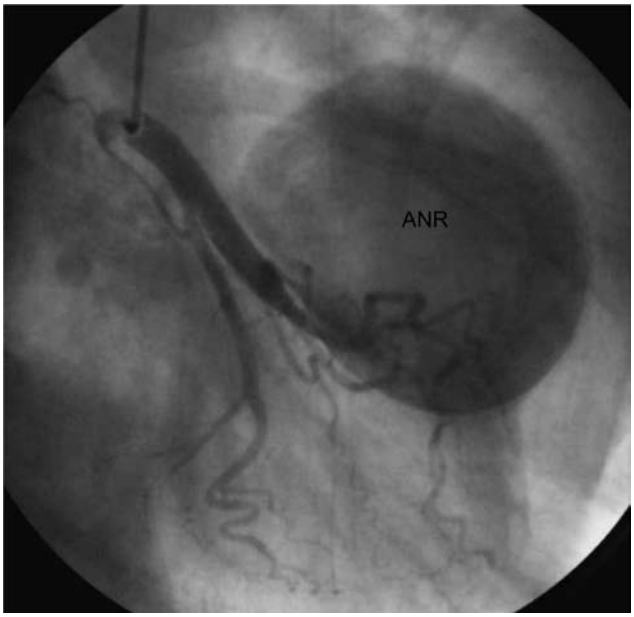

Fig.1. Coronary angiography revealed a giant saccular aneurysm with coronary arteriovenous fistula to the main pulmonary artery. ANR: aneurysm

Fig. 2.
A: The giant aneurysm is 70 × 40 mm in diameter (white arrows).
B: The giant aneurysm was fluoresced and identified with the shunt flow to the pulmonary artery (black arrows).
ANR: aneurysm; PA: pulmonary artery

A | B

arteriovenous fistula to the main pulmonary artery.

During the operation (Fig. 2A), under cardiopulmonary bypass (CPB) 1 ml of ICG (Diagnogreen 0.5%; Daiichi Pharmaceutical, Tokyo, Japan) was intravenously injected by an anesthesiologist via a central venous line. We utilized a newly developed near-infrared PDE camera system (Hamamatsu Photonics K.K., Hamamatsu, Japan) that activates ICG with emitted light, enabling it to handle real-time images of a giant aneurysm. The aneurysm, 70 × 40 mm in diameter, was fluoresced and identified with the shunt flow to the pulmonary artery (Fig. 2B). After aortic clamping, it was opened, a small mass of thrombus was removed, two ostia were revealed, and we closed the orifice of the feeder from the left anterior descending

artery (LAD) #7 with a pledgeted suture; we then closed the drainer artery's orifice, and the aneurysm was overwrapped. The collateral artery to the pulmonary artery (PA) was closed near the main PA from outside. At that time, we thought there was no residual shunt flow. Weaning CPB, we again injected ICG, checking the coronary flow. The native flow was very smooth, but we found that the residual shunt drained to the pulmonary artery and closed the shunt from the outside on a beating heart (Fig. 3).

The postoperative course of the patient was steady and uneventful. Postcoronary angiography showed no stenosis of native flow. Pathological examination showed no atherosclerotic changes, and the specimens exhibited thin fibrous media with no elastic tissue. A postoperative cardiac catheter showed fluent flow, and no residual shunt.

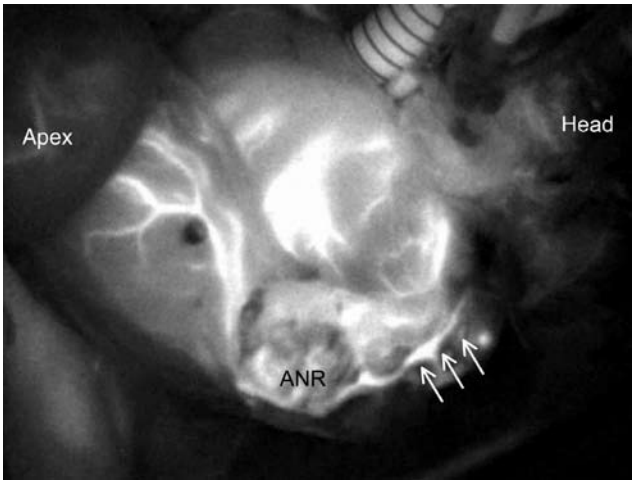

Fig. 3. We found the residual shunt drained to the pulmonary artery (white arrow).
ANR: aneurysm

Discussion

The CAF is an uncommon congenital cardiac malformation identified in only 0.1% of routine cardiac angiographic studies.[3] Levine et al. reported that the vessels originated from the right coronary artery (50%), from the left coronary artery (42%), and from both vessels (5%). The low-pressure chambers are the usual drainage sites into the right ventricle in 41% of patients, into the right atrium in 26%, into the pulmonary artery in 17%, into the coronary sinus in 7%, into the left atrium in 5%, into the left ventricle in 3%, and into the superior vena cava in 1%.[4] The CAA was present in 26% of patients with the CAF.[5] Hirooka et al. first reported a huge saccular aneurysm of a CAF in 2002.[6] We experienced the giant CAA associated with CAF. This case was asymptomatic, the reason perhaps being because the shunt flow was very small. Young patients are generally asymptomatic. More than half of the older patients have such symptoms as dyspnea, fatigue, and anginal chest pain. Angina is thought to be a consequence of a coronary steal phenomenon. The current management of older adults who are asymptomatic is controversial. Some physicians report that patients without symptoms are currently being managed conservatively.[7] Lowe et al. recommended that all patients with major CAF should be considered for surgical correction, and the closure should be electively performed before symptoms and pathological changes in the heart become apparent.[8] Some reports suggest basing the decision to operate on the degree of shunting through the fistula because any communication that creates a Qp:Qs ratio ≥ 1.5:1 will surgically correct.[9,10] But our case showed that the flow ratio is 1.2 and has no atherosclerotic change. The reason for growth into such a huge aneurysm is because there are two genetic types of CAF, chamber and pulmonary artery. This case belongs to a pulmonary artery type, which has less short flow in comparison with the chamber type.[11] This may suggest that minor shunt flow enables growth with no symptoms. But according to the Reitz report, an experimental model, the pulmonary artery PA-circumflex artery (LCx) shunt model whose pulm-syst flow ratio is 1.1, 26% of coronary flow was stolen.[12] If our patient had symptoms that include fatigue, exertional dyspnea, angina, and myocardial infarction as a result of the coronary steal, we might be able to manage treatment at a much smaller size. So we believe that early surgical treatment must be recommended if a sacular aneurysm shows progressive dilatation during the follow-up period with asymptomatic patients.

Many institutions use TEE to confirm the disappearance of the abnormal shunts after the operative procedure.[1] But TEE does not show the residual shunt precisely because it depends on the situation at that time and on the person operating on it. We identified the residual fistula by use of a device called the PDE, produced by Hamamatsu Photonics, Hamamatsu, Japan, that is equipped with a Charge Coupled Device (CCD) camera as a detector with a 760 nm light-emitting diode (LED) and a filter-cutting light below 820 nm. The PDE imaging system is based on ICG fluorescence. The principle is that ICG obtains fluorescence when the peak wavelength is 845 nm, at which time the ICG is combined with serum protein. LED activates the fluorescence, and the image is visualized at the

monitor for real-time display. ICG is a medically useful dye and has been used clinically for various clinical situations, such as liver function evaluation, assessment of intraocular neovascular formation, sentinel lymph node detection,[13] cardiac output measurements and assessment of myocardial blood flow or perfusion (intraoperative graft patency control after coronary artery bypass grafting (CABG)),[14] and evaluation of flap viability.[15–17] Although the injection of ICG causes few complications, patients with a history of allergic reactions, especially to iodine, must be excluded. The rates of complications are very low (0.17%), including nausea (0.08%), fever (0.02%), and nonsevere shock (0.02%).[18] We always use this system to assess CABG graft flow, and there are currently limitations to the technique. First, it is only semiquantitative because it permits assessment of graft flow as "excellent," "satisfactory," or "poor," but it does not provide an exact measure of graft flow measurement. Second, the depth of laser beam penetration is only about 1 mm; thus it is vulnerable to varying depths of the native coronary artery; also, the images of LCx or the right coronary artery (RCA) area are less clear because of the camera position.[19] However, this is not same as in the case of coronary aneurysms, especially giant ones. The results indicate that this technique is useful for acceptance as one of the examinations to evaluate such a coronary aneurysm. Furthermore, it may be useful for the detection of shunt cases, such as congenital heart disease.

Reference

1. Cheng-Wei Lu, Tzu-Yu Lin, Ming-Jiuh Wang. Large Coronary Arteriovenous Fistula to the Main Pulmonary Artery. *Anesthesia & Analgesia* 2006; **103**: 41–2.
2. Hara H, Mori M, Araki T, et al. Coronary artery fistula with an associated aneurysm detected by 16-slice multidetector row computed tomographic angiography. *Heart Vessels* 2005; **20**: 184–5.
3. Vavuranakis M, Bush CA, Boudouls H. Coronary artery fistulas in adults:Incidece, angiographic characteristics, natural history. *Cathet Cardiovasc Diagn* 1995; **35**: 116–20.
4. Levin DC, Fellows KE, Abrams HL. Hemodynamically significant primary anomalies of the coronary arteries. *Circulation* 1978; **58**: 25–33.
5. Said SAM, El Gamal MIH. Coronary angiographic morphology of congenital coronary arteriovenous fistulas in adults. *Cathet Cardiovasc Diagn* 1995; **35**: 29–35.
6. Hirooka K, Hanatani A, Nakatani S, et al. Huge sacular aneurysm in a coronary-pulmonary fistula fed by the left and right coronary arteries. *Circ J* 2002; **66**: 525–7.
7. Sherwood MC, Rockenmacher S, Colan SD, et al. Prognostic significance of clinically silent coronary artery fistulas. *Am J Cardiol* 1999; **83**: 407–11.
8. Lowe JE, Oldham HN, Jr, Sabiston DC, Jr. Surgical management of congenital coronary artery fistulas. *Ann Surg* 1981; **194**: 373–80.
9. Carr JA, Al-Sadir J, Jeevanandam V. Anomalous coronary to pulmonary artery fistula and aneurysm in an 86-year-old female. *J Card Surg* 2006; **21**: 188–90.
10. Davis TJ, Allen HD, Wheller JJ, et al. Coronary artery fistula in the pediatric age group: A 19-year institutional experience. *Ann Thorac Surg* 1994; **58**: 760–3.
11. Rittenhouse EA, Doty DB, Ehrenhaft JL. Congenital coronary artery-cardiac chamber fistula. *Ann. Thorac. Surg* 1975; **20**: 468–85.
12. Reitz BA, Harrison LH, Michaelis LL. Experimental coronary artery fistula. *J. Thorac. Cardiovasc. Surg* 1975; **69**: 278–82.
13. Kitai T, Inomoto T, Miwa M, et al. Fluorescence navigation with indocianine green for detecting sentinel lymph nodes in breast cancer. *Breast Cancer* 2005; **12**: 211–5.
14. Detterb C, Russ D, Ifflamd A, et al. Near-infrared fluorescence coronary angiography: a new noninvasive technology for intraoperative graft patency control. *Heart Surg Forum* 2002; **5**: 364–9.
15. Holm C, Mayr M, Hofter E, et al. Perfusion zones of the DIEP flap revisited: a clinical study. *Plast Reconstr Surg* 2006; **117**: 37–43.
16. Yamaguchi S, De Lorenzi F, Petit JY, et al. The perfusion map of the unipedicled TRAM flap to reduce postoperative partial necrosis. *Ann Plast Surg* 2004; **53**: 205–9.
17. Still J, Law E, Dawson J, et al. Evaluation of the circulation of reconstructive flaps using laser-induced fluorescence of indocyanine green. *Ann Plast Surg* 1999; **42**: 266–74.
18. Daiichi Pharmaceutical [package insert]. Tokyo, Japan: 2007.
19. Taggart DP, Choudhary B, Anastasiadis K, Abu-Omar Y, Balacumaraswami L, et al. Preliminary experience with a novel intraoperative fluorescence imaging technique to evaluate the patency of bypass grafts in total arterial revascularization. *Ann Thorac Surg* 2003; **75** : 870–3.