Case Report

Diaphragm Perforation after Radio-Frequency Ablation for Metastatic Lung Cancer

Takeshi Mori, MD, PhD,[1] Koichi Kawanaka, MD,[2] Yasuomi Ohba, MD,[1]
Kenji Shiraishi, MD, PhD,[1] Kazunori Iwatani, MD,[1] Kentaro Yoshimoto, MD,[1]
and Yusuyuki Yamashita, MD, PhD[2]

A case of diaphragm perforation after radio-frequency ablation (RFA) for lung metastasis from uterine cervical cancer is reported. The patient developed pelvic recurrence and solitary lung metastasis after a radical hysterectomy for uterine cervical cancer. Pelvic radiation and RFA for lung metastasis were performed. Metastasis was located in the laterobasal segment of the lower lobe of the right lung. RFA was repeatedly performed in September 2005 and August 2006. In May 2008, ^{18}F-fluoro-deoxy-glucose (FDG) positron emission tomography–computed tomography showed evidence of local recurrence of the lung metastasis. A solid lesion with FDG accumulation accompanying a cystic lesion was observed in the lung base. The patient underwent a wedge resection of the lung in June 2008, during which a perforated area of the diaphragm (3 cm in diameter) was identified under the cystic lesion, which was not herniated. The perforation in the diaphragm was closed with a simple continuous suture. (Ann Thorac Cardiovasc Surg 2010; 16: 426–428)

Key words: diaphragm perforation, radio-frequency ablation, metastatic lung cancer, tuberculoma

Introduction

Radio-frequency ablation (RFA) is increasingly being used for the treatment of intrathoracic malignancies. Although RFA is considered to be a minimally invasive therapy, the rate of major complications associated with RFA has been reported to be 10%–20%.[1–4] Several cases of diaphragm perforation have been reported after liver RFA[5–8]; however, diaphragm perforation has not been previously reported after lung RFA. Here we report a case of asymptomatic diaphragm perforation after RFA for lung metastasis. To our knowledge, this is the first such reported case.

From [1]Departments of Thoracic Surgery and Diagnostic Imaging, and [2]Graduate School of Medical Sciences, Kumamoto University, Kumamoto, Japan

Received April 15, 2009; accepted for publication September 14, 2009
Address reprint requests to Takeshi Mori, MD, PhD: Department of Thoracic Surgery, Graduate School of Medical Sciences, Kumamoto University, Honjo 1–1–1, Kumamoto 860–8556, Japan.

Case Report

A 39-year-old female patient underwent a radical hysterectomy for uterine cervical cancer in August 2002. The patient developed pelvic recurrence, which was irradiated with 60 Gy in October 2003. In July 2005, a lung nodule (1.8 cm in diameter) was detected in the laterobasal segment (S^9_b) of the lower lobe of the right lung by computed tomography (CT) (Fig. 1). The patient rejected surgical intervention for the lung nodule because she had been suffering from complications after pelvic surgery. In our institute, percutaneous lung RFA is applied to patients who cannot tolerate pulmonary resection or who refuse it. After CT-guided percutaneous biopsy of the lung nodule proved metastasis from the cervical cancer of the uterus, percutaneous lung RFA was performed in September 2005. A 17-gauge expandable RFA device with an array diameter of 2 cm (LaVeen Needle Electrode, Radiotherapeutics, Mountain View, CA) was used with

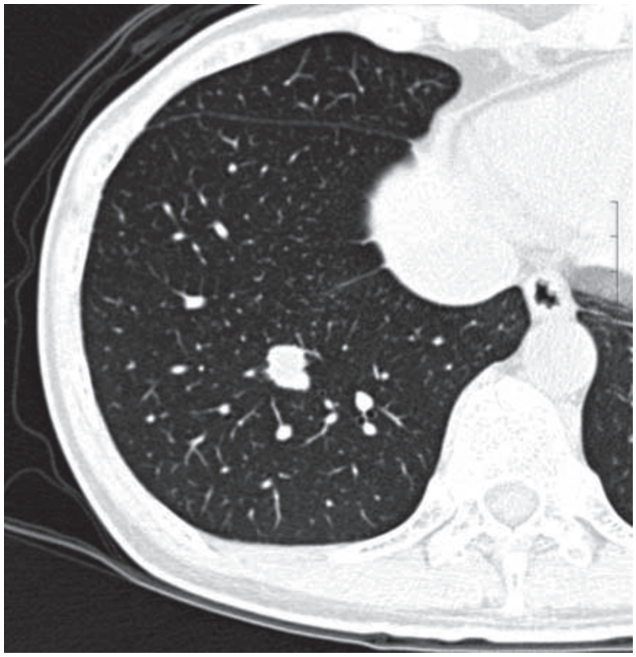

Fig. 1. Computed tomography showed a well-defined solid nodule (1.8 cm in diameter) in the laterobasal segment of the lower lobe of the right lung.

Fig. 2. Computed tomography showed a spindle-shaped solid nodule (3.1 cm in diameter) in the laterobasal segment of the lower lobe of the right lung.

10 retractable curved electrodes. The RF 3000 generator system (Radiotherapeutics, Sunnyvale, CA, distributed by Boston Scientific, Natik, MA) was used as the radio-frequency generator. During application, the grounding pads were placed on the patient's thigh. After a local anesthetic was administered in combination with a small intravenous dose of 0.2 mg fentanyl, the radio-frequency needle was positioned in the center of the tumor with CT fluoroscopic guidance. RFA was initiated at 30 W and increased by 10 W every minute until it "impeded out" at 100 W. RFA was then begun again at 60 W and was maintained for several minutes until it again "impeded out." The same procedures were administered in the ventral and dorsal areas of the tumor, respectively. In August 2006, RFAs were repeatedly performed in the same manner to treat local recurrence of the lung metastasis detected by CT (Fig. 2). During two RFAs, there were no direct needle insertions into the diaphragm.

In May 2008, positron emission tomography–computed tomography (PET-CT) detected an oval-shaped lesion and a polygonal-shaped lesion with 18F-fluorodeoxy-glucose accumulation (maximal standardized uptake: 6.1) (Fig. 3).

The patient had no symptoms, and diagnostic imaging showed no evidence of diaphragm herniation. Surgery was performed via minithoracotomy in June 2008. After adhesiolysis of the pleural adhesion between the lung base and the diaphragm, a perforated area of the diaphragm (3 cm in diameter) was identified under the cystic lesion, which was not herniated, and through it the liver could be seen (Fig. 4).

The perforation in the diaphragm was closed with a simple continuous suture (3-0 PROLENE®; Ethicon Inc., Somerville, NJ). The tumor was resected completely and histologically diagnosed as a tuberculoma. The patient was prescribed antituberculosis medication and was observed to be doing well 10 months after surgery.

Discussion

To our knowledge, this is the first reported case of diaphragm perforation after lung RFA. Complications of lung RFA have been reported to include pneumothorax, pleuritis, pleural effusion, and lung abscess.[1–4] Diaphragm perforation is a rare but serious complication resulting from thermal damage that occurs during liver RFA. There have been several reports about diaphragm perforation after liver RFA caused diaphragm herniation.[5–8]

Rhim et al. noted that diaphragmatic thermal injury

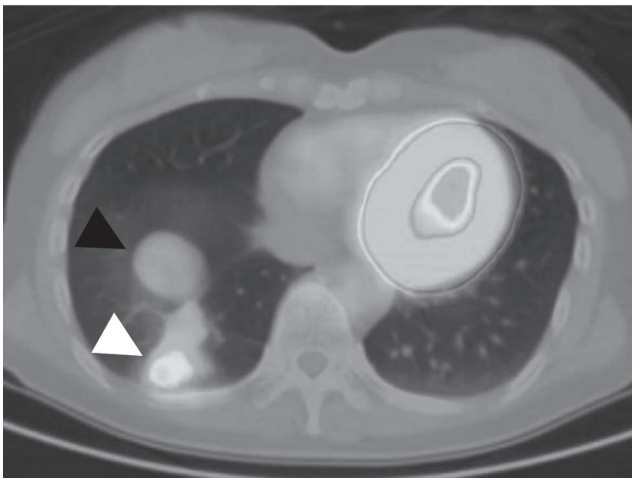

Fig. 3. ^{18}F-fluoro-deoxy-glucose positron emission tomography–computed tomography showed an oval-shaped lesion (black arrow) and a polygonal-shaped lesion with ^{18}F-fluoro-deoxy-glucose accumulation (white arrow).

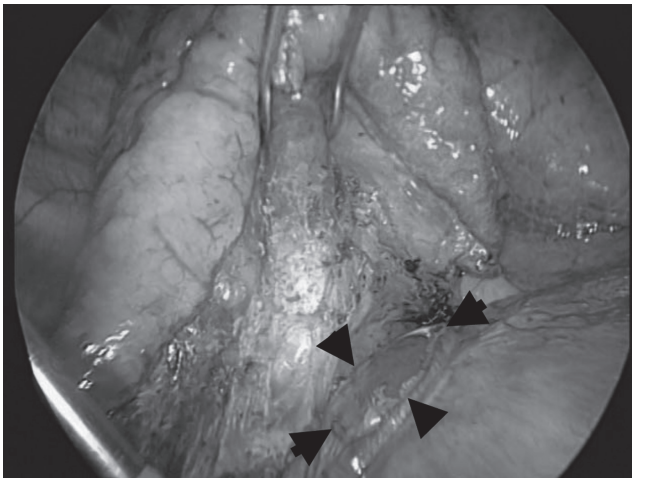

Fig. 4. The perforation with no herniation was located at the dome of the diaphragm, through which the liver was observable.

after liver RFA is possible when a mass is located in the dome of the liver.[7] Possible causes of diaphragm perforation include contact between the target tumor of RFA and the diaphragm and thermal damage resulting from pleural adhesion around the tumor after RFA. In the present case, the lung tumor treated with RFA was located at the base of the lung close to the diaphragm. During surgery, pleural adhesion was noted between the lung base and the diaphragm, which most likely resulted from repeated RFA and caused the perforation of the diaphragm.

Herniation of the diaphragm was not observed in the present case, probably because the diaphragm perforation was small (3 cm in diameter), because there was no gap between the liver and the diaphragm perforation, and because of tight adhesion between the lung base and the diaphragm.

In this case there was another possibility, the natural development of tuberculosis, which caused the diaphragm perforation. But we thought that the thermal injury was more likely than the development of tuberculoma to cause the diaphragm perforation because of the following reasons. (1) In PET-CT, the tuberculoma was not in contact with the cyst, which was located at the perforated area of the diaphragm (Fig. 3). (2) The diaphragm perforation was not irregular, but it was smooth coin shaped (Fig. 4).

Because lung and liver RFAs can cause thermal damage to the surrounding organs, caution should be taken during both.

References

1. Sano Y, Kanazawa S, Gobara H, Mukai T, Hiraki T, et al. Feasibility of percutaneous radiofrequency ablation for intrathoracic malignancies. A large single-center experience. *Cancer* 2007; **109**: 1397–405.
2. Kang S, Luo R, Liao W, Wu H, Zhang X, et al. Single group study to evaluate the feasibility and complications of radiofrequency ablation and usefulness of post treatment position emission tomography in lung tumours. *World J Surg Oncol* 2004; **2**: 30.
3. de Baère T, Palussière J, Aupèrin A, Hakime A, Abdel-Rehim M, et al. Midterm local efficacy and survival after radiofrequency ablation of lung tumors with minimum follow-up of 1 year. Prosective evaluation. *Radiology* 2006; **240**: 587–96.
4. Simon CJ, Dupuy DE, DiPetrillo TA, Safran HP, Grieco CA, et al. Pulmonary radiofrequency ablation. Long-term safty and efficacy in 153 patients. *Radiology* 2007; **243**: 268–75.
5. Dodd GD 3rd, Soulen MC, Kane RA, Livraghi T, Lees WR, et al. Minimally invasive treatment of malignant hepatic tumors. At the threshold of a major breakthrough. *Radiographics* 2000; **20**: 9–27.
6. Mulier S, Mulier P, Ni Y, Miao Y, Dupas B, et al. Complications of radiofrequency coagulation of liver tumours. *Br J Surg* 2002; **89**: 1206–22.
7. Rhim H, Yoon KH, Lee JM, Cho Y, Cho JS, et al. Major complications after Radio-frequency thermal ablation of hepatic tumor. Spectrum of imaging findings. *Radiographics* 2003; **23**: 123–34.
8. Koda M, Ueki M, Maeda N, Murawaki Y. Diaphragmatic perforation and hernia after hepatic Radiofrequency ablation. *AJR* 2003; **180**: 1561–2.