

Aortic Balloon Used in a Cardiac Reoperation of a Patient with Patent Coronary Grafts

Kenji Akiyama, MD,¹ Kin-ich Nakata, MD,¹ Satoshi Kashiwazaki, MD,¹
and Seiji Fukushima, MD²

Reoperation in patients with patent coronary artery bypass grafts behind the sternum is associated with a high risk of graft injury that may be life-threatening. We recently performed mitral valve replacement in a patient with patent coronary artery bypass grafts and grade IV mitral regurgitation. Surgery was safely performed with minimal adhesion dissection and modified Port-Access Technique using an aortic balloon.

Key words: cardiac reoperation, minimal adhesion dissection, aortic balloon

Introduction

Repeat median sternotomy after coronary artery bypass surgery entails a high risk of injury to patent grafts that may be life-threatening. This report describes the use of an aortic balloon in a mitral valve replacement in a patient with patent coronary bypass grafts. Using this approach, we could limit the dissection to the right atrium and superior vena cava.

Patient and Surgical Technique

The patient was a 67-year-old man who had undergone coronary artery bypass surgery in 4 vessels, 5 years earlier. He was admitted to the hospital with heart failure due to mitral valve insufficiency. Cardiac evaluation showed mitral regurgitation, grade IV, and the performance status, grade IV (New York Heart Association

classification of cardiac performance); therefore, the grade of mitral regurgitation indicated surgery. Preoperative evaluation revealed that the left internal thoracic artery (LITA) to the left anterior descending artery graft and right coronary and circumflex grafts (vein grafts) were patent. In addition, the LITA and right coronary grafts were behind the sternum (**Fig. 1**). After intravenous administration of 5000 units of heparin, an aortic balloon (Tokai Medical Products, Kasugi City, Japan) (**Fig. 2**) was inserted under fluoroscopic guidance through the left femoral artery into the ascending aorta. We referred to the 3-D CT for positioning of the balloon (**Fig. 1**). Under general anesthesia with differential lung ventilation, the patient was placed in a left lateral decubitus position with the right arm elevated, and then, the thoracotomy was performed with an anterior axillary incision in the 4th intercostal space. An incision was placed in the mediastinal pleura, and then, adhesions between the pericardium and right atrium were dissected. The patent graft to the right coronary artery, confirmed preoperatively, ran between the atrium and ventricle; therefore, the dissection was limited from the lateral right atrium to the superior vena cava, with taping of the superior vena cava.

After heparinization, a 22-F inflow cannula was inserted through the right femoral artery, a 50-cm, 27-F outflow cannula was inserted through the right femoral vein to the inferior vena cava, resulting in the start of extracorporeal circulation. To perform the mitral valve procedure under a transatrial septal approach, we inserted

¹Department of Cardiovascular Surgery, Nihon University Nerima Hikarigaoka Hospital, Tokyo, Japan

²Department of Cardiology, Nihon University Nerima Hikarigaoka Hospital, Tokyo, Japan

Received: February 9, 2009; Accepted: October 28, 2009

Corresponding author: Kenji Akiyama, Department of Cardiovascular Surgery, Nihon University Nerima Hikarigaoka Hospital, 2-11-1 Hikarigaoka, Nerima-ku, Tokyo 179-0072, Japan
E-mail: kakiyama@med.nihon-u.ac.jp

©2011 The Editorial Committee of *Annals of Thoracic and Cardiovascular Surgery*. All rights reserved.

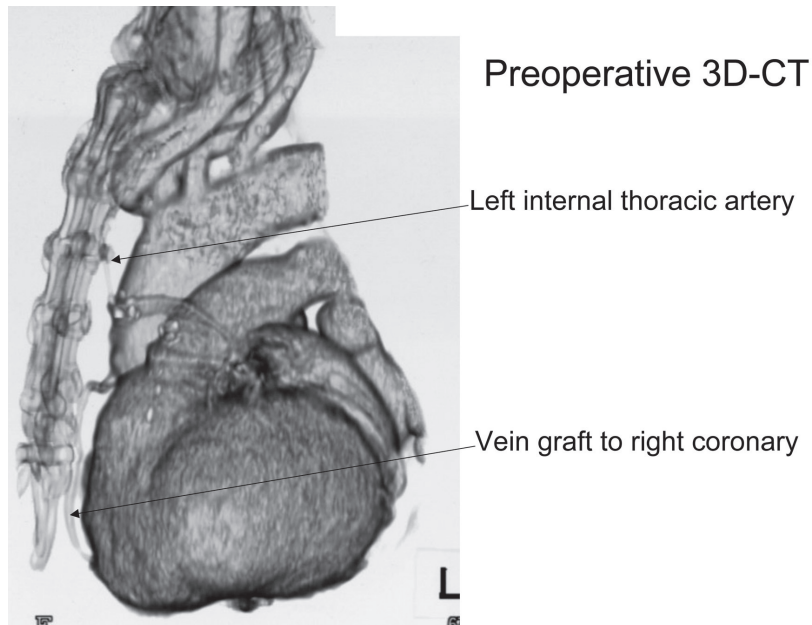


Fig. 1 Three-dimensional CT showing the left internal thoracic artery and right coronary vein graft coursing behind the sternum.

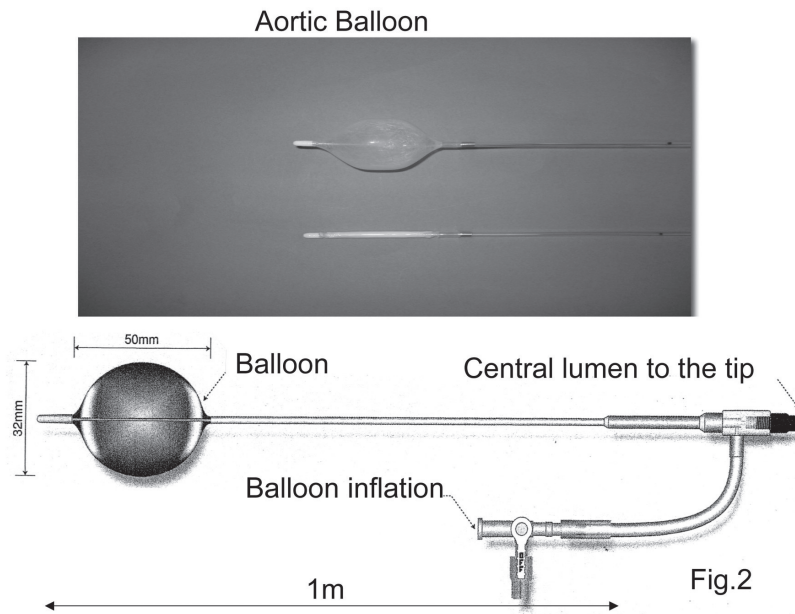


Fig. 2 Aortic occlusion balloon
The polyurethane balloon has a capacity of 23 mL and is expanded to a diameter of 32 mm. The polyurethane shaft is 9F and insertable up to 1 m.

a 30-F outflow cannula from the right atrium to the superior vena cava and inserted a snare into it. For the inferior vena cava, instead of placing a snare, a 24-F Foley balloon catheter was inserted from the right atrium to the inferior vena cava, and the balloon was dilated to con-

trol right atrial blood flow. Under general hypothermia at 24°C, the aorta was occluded with the indwelling aortic balloon, and 1800 mL of cardioplegic solution was infused through the balloon tip to induce cardiac standstill (**Fig. 3**), applied as a Port-Access Technique.

Operative schema

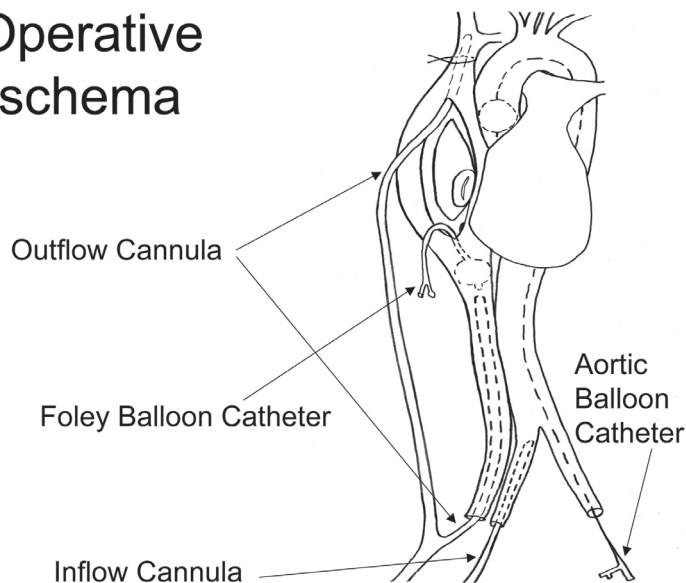


Fig. 3 Operative schema

Inflow and outflow from right femoral vessels. The aortic occlusion balloon is inserted from the contralateral femoral artery to the ascending aorta. To provide an adequate view of the right atrium, the inferior vena cava is occluded with a balloon, a catheter is inserted in the superior vena cava, and a snare is placed.

After incision of the atrial septum, inspection of the mitral valve showed thinning, but the configuration could not be assessed. The anterior leaflet was thus incised and mitral valve replacement, with preservation of the posterior leaflet, was performed with everting interrupted mattress suture using a 25-mm St. Jude Medical valve. Air was removed by suction through the tip of the aortic balloon and insertion of a left ventricular vent from the left superior pulmonary vein. The atrial septum was closed with continuous sutures; then the aortic occlusion was released, and the balloon was removed. After resumption of the heart beat, transesophageal echocardiography was performed to ensure air removal from the heart, and then the left ventricular vent was removed. Duration of aortic occlusion was 27 min. After administration of dopamine, the patient was easily weaned from extracorporeal circulation. One year after the operation, the patient has been free of symptoms and enjoys a normal life.

Comments

Cardiac reoperation is associated with a risk of tissue injury, depending on the extent of the adhesions. Injury to patent grafts can occur in patients who have had coronary artery bypass surgery. The injury can be life-threatening,

particularly if the internal thoracic artery is injured during a median sternotomy.¹⁾ Right thoracotomy is often performed to avoid injury to coronary artery bypass grafts in a subsequent mitral valve surgery. However, compared to median sternotomy, the field of vision during a right thoracotomy is limited, and inflow access to the ascending aorta for extracorporeal circulation is difficult. Aortic occlusion and cardiac perfusion techniques must therefore be devised. In addition, venous bypass grafts may be damaged during the dissection. For these reasons, right thoracotomy, inflow and outflow through the femoral vessels for extracorporeal circulation and mitral valve replacement are widely used during hypothermia and ventricular fibrillation without aortic clamping.^{2, 3)} In these cases, ventricular fibrillation must be maintained to prevent ejection of air.⁴⁾

Therefore, before starting surgery, we inserted a balloon through the femoral artery to the ascending aorta under fluoroscopic guidance for aortic occlusion and coronary perfusion. The balloon is made of polyurethane, with a capacity of 23 mL, and expands to an outer diameter of 32 mm. However, even at 300 mL, the balloon remains intact, expanding up to 84 mm. In addition, the shaft is insertable up to 1 m for indwelling in the ascending aorta, and the central lumen extends to the tip for an

insertion with a guide wire, allowing the injection of cardioplegic solution. These features 1) help avoid graft injury due to ascending aortic dissection, 2) do not require any special devices for the aortic occlusion or injection of cardioplegic solution,⁵⁾ and 3) eliminate the risk of air ejection resulting from aortic occlusion and cardiac standstill. However, because the LITA graft blood stream remains, it may become a problem from the aspect of the myocardial protection effect. In the previous CABG operation, the transit time of the LITA graft flow was 32ml/min, with a blood pressure 130/80 mm Hg. However, it is thought that the blood streaming down the myocardium, which relaxed considerably, decreases in blood pressure by 40 mm Hg, during the complete extracorporeal circulation. Therefore, the rise of myocardial temperature was slight, and it is thought that the myocardium protection effect was not ideal though adequate. In fact, bloodflow from the coronary sinus was minimal, which did not interfere. I think that we can keep myocardial temperature low by injecting cardioplegic solution repeatedly.

The mitral valve procedure was performed using a transatrial septal approach, so dissection of the right side of the left atrium was not required. However, to ensure a clear field of vision, reflux of blood into the right atrium had to be controlled, so an outflow cannula was inserted from the right atrium to the superior vena cava, then, a snare was placed, and a Foley balloon was inserted in the

inferior vena cava. These techniques are advantageous because they minimize the dissection of adhesions.

There are various approaches for cardiac reoperation and auxiliary procedures, each having its own advantages and disadvantages. However, we should carefully select the one approach that is best for the individual patient, to minimize risk.

References

- 1) Byrne JG, Aranki SF, Adams DH, Rizzo RJ, Couper GS, et al. Mitral valve surgery after previous CABG with functioning IMA grafts. *Ann Thorac Surg* 1999; **68**: 2243–7.
- 2) Vleissis AA, Bolling SF. Mini-reoperative mitral valve surgery. *J Card Surg* 1998; **13**: 468–70.
- 3) Onnasch JF, Schneider F, Falk V, Walther T, Gummert J, et al. Minimally invasive approach for redo mitral valve surgery: A true benefit for the patient. *J Card Surg* 2002; **17**: 14–9.
- 4) Svensson LG, Gillinov AM, Blackstone EH, Houghtaling PL, Kim KH, et al. Does right thoracotomy increase the risk of mitral valve reoperation? *J Thorac Cardiovasc Surg* 2007; **134**: 677–82.
- 5) Aybek T, Dogan S, Risteski P, Zierer A, Wittlinger T, et al. Two Hundred Forty Minimally Invasive Mitral Operations Through Right Minithoracotomy. *Ann Thorac Surg* 2006; **81**: 1618–24.