Ann Thorac Cardiovasc Surg 2011; 17: 212–214

Case Report

A Case of Multiple Squamous Cell Papillomas of the Trachea

Saiko Ogata-Suetsugu, MD,[1] Miiru Izumi, MD, PhD,[1] Koichi Takayama, MD, PhD,[1]
Torahiko Nakashima, MD, PhD,[2] Hiromasa Inoue, MD, PhD,[1] and Yoichi Nakanishi, MD, PhD[1]

We report a case of 68-year-old woman suffering from breathlessness on exertion with stridor. A chest computed tomography showed a tumor arising from the posterior wall of the trachea. The diagnosis was squamous cell papilloma of the surgically removed tumor, which had caused the asphyxiation. After removal of the tumor, the patient received radical therapy: semiconductor laser transpiration. Polymerase chain reaction (PCR) detected human papilloma virus (HPV) type 6, thought to be the cause of the respiratory papilloma.

Key words: papilloma, human papilloma virus, polymerase chain reaction, semiconductor laser, trachea

Case Report

A 68-year-old woman was admitted to our hospital because of breathlessness with stridor, which gradually worsened over the previous 2 months. She was a non-smoker and had no history of radiotherapy to the trachea. Physical examinations were normal, except for inspiratory and expiratory stridor. Her routine laboratory results were normal. Pulmonary function test revealed a severe obstructive impairment: a forced vital capacity (FVC) of 3.09 L (135.5% of predicted), a forced expiratory volume in 1 s (FEV1.0) of 0.91 L (53.2% of predicted), and FEV1.0 to FVC ratio of 29.5%. Flow volume loop pattern showed intrathoracic upper airway obstruction. Chest computed tomography (CT) and flexible bronchoscopy documented a cauliflower-like, warty tumor. The main tumor size was 15 × 10 × 10 mm and was located 30 mm below the vocal cords (**Fig. 1a** and **1b**). In addition, we observed two other small polypoid lesions. We started an emergency tracheostomy of the patient under local anesthesia to remove the tumors and secure her airway.

During the tracheostomy, she became nearly asphyxiated. Then, we administered general anesthesia. After completing the tracheostomy, we successfully removed the main tumor without preparing an extracorporeal cardiopulmonary bypass. Histologically, the tumor specimen contained squamous cell papilloma with mild, atypical koilocytes; thus, the diagnosis was multiple respiratory papillomas (**Fig. 1c** and **1d**). Polymerase chain reaction (PCR) amplification (**Fig. 2**) detected human papilloma virus (HPV) type 6 DNA in the tumor specimen. Otherwise, there was no viral DNA in normal tissue. After removal of the primary tumor, we used semiconductor laser transpiration, a radical therapy, to remove the remaining tumors. The patient got relief from her symptoms with no recurrence 8 months after treatment.

Discussion

Respiratory papilloma has been reported in children and adults. Onset during adulthood is more common among men and often occurs in the third or fourth

[1]*Research Institute for diseases of the Chest, Graduate School of Medical Sciences, Kyushu University, Fukuoka, Fukuoka, Japan*
[2]*Department of Otorhinolaryngology, Graduate School of Medical Sciences, Kyushu University, Fukuoka, Fukuoka, Japan*

Received: October 1, 2009; Accepted: January 7, 2010
Corresponding author: Koichi Takayama, MD, PhD. Research Institute for Diseases of the Chest, Graduate School of Medical Sciences, Kyushu University, 3-1-1 Maidashi, Higashi-ku, Fukuoka, Fukuoka 812-8582, Japan
Email: koichi-t@kokyu.med.kyushu-u.ac.jp

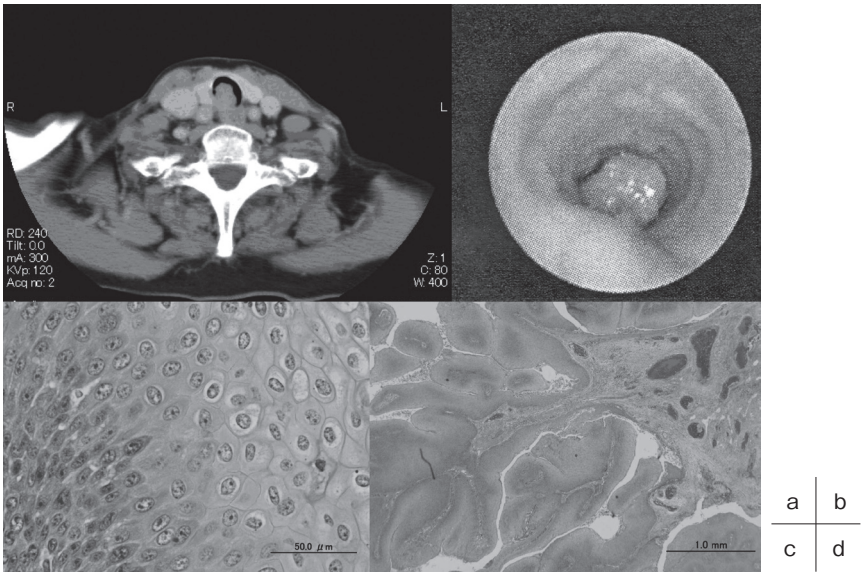

Fig. 1 **a**: CT scan of the tumor, 15 mm in size, arising from the posterior wall of the trachea. **b**: Flexible bronchoscopy documented a cauliflower-like, warty tumor. The tumor size was 15 mm and was located in 30 mm below from vocal code. **c**, **d**: Sections show exophytic proliferation of squamous epitherium with koilocytosis and fibro-vascular stroma (HE stain × 200). Transtitional epitherium is partly seen. There is no evidence of malignancy.
CT, computed tomography

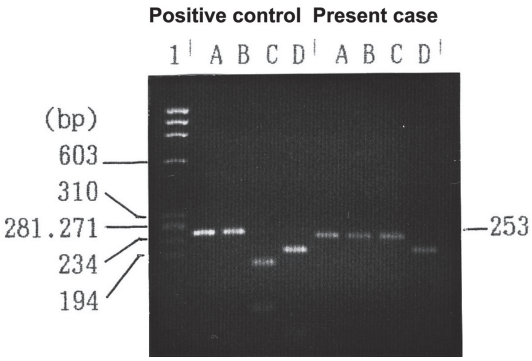

Fig. 2 Restriction mapping of the amplified HPV DNA from the tumor biopsy sample. The PCR product was cut with the following restriction enzymes, A, uncut; B, *Rsa*; C, *Dde*; D, *Hae*. This mapping pattern showed the presence of HPV type 6 DNA.
HPV, human papilloma virus; PCR, polymerase chain reaction

decade of life. According to previous reports, most papillomas are found in the larynx: only 5% of patients had distal involvement of the trachea, and involvement of lung parenchyma is very rare, which is seen in less than 1% of all cases.[3)]

There is now convincing evidence from immunohistochemical, ultrastructural, and molecular biologic studies that the majority, if not all cases of multiple airway papillomas are caused by human papillomavirus (HPV). The etiological agent of many benign and malignant tumors arising from epidermal tissue is HPV, a causative factor of cervical cancer. It is also associated with other ano-genital cancers such anal, penile, vulval and vaginal carcinoma. Furthermore, head and neck cancers are also associated with HPV infection. These malignancies are associated with high-risk types, in particular HPV type 16, 18, 31, 33, 35, 39, 45, 51, 52, 56, 58, 59, 68, 73 and 82. Benign tumors are caused by low risk types such as HPV 1, 2, 3, 4, 6, 10, 11 and others.[9)] No simple culture method or serologic test is available for identifying HPV infection. Techniques for identifying the virus are based on nucleic acid detection, either direct hybridization or PCR amplification. Liu[1)] studied 16 patients with recurrent respiratory papillomatosis (RRP) using a slot blot hybridization technique and detected HPV6b, HPV 11, and HPV 16 in 87.5%, 93.7%, and 81.6% of cases, respectively. Other report showed that the co-presence of HPV types 6, 11, 16, 31, 33, 35 or 39 (in various combinations of the types) was confirmed in all cases.[7)] The route of transmission is

likely to differ in the juvenile onset and adult onset forms of RRP. In juvenile onset RRP, HPV is thought to be acquired at the time of vaginal delivery.[3] In one case control study,[9] adult onset RRP patients had more sexual partners and oral sex than their controls. HPVs cause latent airway infection, in addition to the active infection, that induces papillomas, and activation of latent HPV DNA, which appears to persist for the life of the patient, is considered to be the cause of recurrent disease. Allan L reported the presence of HPV in clinically normal laryngeal and trachea tissue from RRP patient. There was also no significant differences between tracheal latency with HPV 6 and 11. This report proposed that the low frequency of tracheal disease reflects a lower frequency of activation.[5] Risk factors leading to virus activation in RRP have not been recognized; however, gastroesophageal reflux disease has been suggested as a possible factor.[10] Malignant degeneration into squamous cell carcinoma occurs in 3% to 5% of papilloma patients and more often in patients with a history of smoking or radiation therapy. However, other risk factor for malignant transformation has been noted. Several reports suggested HPV 11 is associated with a transformation to squamous cell carcinoma.[2, 3, 8]

Our patient was female and relatively older than most patients with adult onset papillomas. The route of HPV transmission was unclear. Her tumors were limited to the trachea, and her vocal cords were intact. She did not have risk factors for malignant transformation, such as a history of smoking, radiation therapy, or HPV 11 infection. Furthermore, we did not detect by PCR the presence of HPV in clinically normal tracheal tissue. The basic treatment of respiratory papilloma is surgical removal of the tumor using various lasers such as CO_2, KTP, and pulse dye. Other reports have suggested that the microdebrider may be equally safe and cost less. In addition, several reports have indicated the utility of adjuvant therapies, such as photodynamic therapy, indol-3-carbinol, cidofovir intralesional injections, mumps vaccine, α-interferon, erlotinib, celecoxib, and bevacizumab. A quadrivalent vaccine for human papilloma virus is also expected to become a therapeutic option against respiratory papilloma.

In our patient, we successfully removed the tumor using electrocautery and a semi-conductor laser. However, clinical follow-up is necessary to confirm the absence of recurrence or malignant transformation.

References

1) Lam CW, Talbot AR, Yeh KT, Lin SC, Hsieh CE, et al. Human papilloma virus and squamous cell carcinoma in a solitary tracheal papilloma. Ann Thorac Surg 2004; **77**: 2201–2.
2) Lele SM, Pou AM, Ventura K, Gatalica Z, Payne D. Molecular events in the progression of recurrent respiratory papillomatosis to carcinoma. Arch Pathol Lab Med 2002; **126**: 1184–8.
3) Cook JR, Hill DA, Humphrey PA, Pfeifer JD, El-Mofty SK. Squamous cell carcinoma arising in reccurent respiratory papollomatosis with pulmonary involvement: emerging common pattern of clinical features and human papillomavirus serotype association. Mod Pathol 2000; **13**: 914–18.
4) Long YT, Sani A. Reccurent respiratory papillomatosis. Asian J Surg 2003; **26**: 112–6.
5) Abramson AL, Nouri M, Mullooly V, Fisch G, Steinberg BM. Latent human papillomavirus infection is comparable in the larynx and trachea. J Med Virol 2004; **72**: 473–7.
6) Rady PL, Schnadig VJ, Weiss RL, Hughes TK, Tyring SK. Malignant transformation of recurrent respiratory papilloatosis associated with integrated human papillomavirus type 11 DNA and mutation of p53. Laryngoscope 1998; **108**: 735–40.
7) Peñaloza-Plascencia M, Montoya-Fuentes H, Flores-Martínez SE, Fierro-Velasco FJ, Peñaloza-González JM, et al. Molecular identification of 7 human papillomavirus types in recurrent respiratory papillomatosis. Arch Otolaryngol Head Neck Surg 2000; **126**: 1119–23.
8) Rabah R, Lancaster WD, Thomas R, Gregoire L. Human papillomavirus-11-associated recurrent respiratory papillomatosis is more aggressive than human papillomavirus-6-associated disease. Pediatr Dev Pathol 2001; **4**: 68–72.
9) Kashima HK, Shah F, Lyles A, Glackin R, Muhammad N, et al. A comparison of risk factors in juvenile-onset and adult-onset recurrent respiratory papillomatosis. Laryngoscope 1992; **102**: 9–13.
10) Borkowski G, Sommer P, Stark T, Sudhoff H, Luckhaupt H. Recurrent respiratory papillomatosis associated with gastroesophageal reflux disease in children. Eur Arch Otorhinolaryngol 1999; **256**: 370–2.
11) Pasquale K, Wiatrak B, Woolley A, Lewis L. Microdebrider versus CO2 laser removal of recurrent respiratory papillomas: a prospective analysis. Laryngoscope 2003; **113**: 139–43.
12) Freed GL, Derkay CS. Prevention of recurrent respiratory papillomatosis: Role of HPV vaccination. Int J Pediatr Otorhinolaryngol 2006; **70**: 1799–803.